F. W. S. Langmaid, M. D.,
Instruments,
Books,
Supplies,
for practitioner and student,
202 S. 36th St., Phila., Pa.

P. H. Dale

Digitized by the Internet Archive
in 2026

https://archive.org/details/twelvelectureson0000unse

TWELVE LECTURES

ON THE

STRUCTURE

OF THE

CENTRAL NERVOUS SYSTEM

FOR PHYSICIANS AND STUDENTS.

BY

DR. LUDWIG EDINGER,
Frankfort-on-the-Main.

SECOND REVISED EDITION. WITH 133 ILLUSTRATIONS.

TRANSLATED BY

WILLIS HALL VITTUM, M.D.,
St. Paul, Minn.

EDITED BY

C. EUGENE RIGGS, A.M., M.D.,
PROFESSOR OF MENTAL AND NERVOUS DISEASES, UNIVERSITY OF MINNESOTA; MEMBER OF THE AMERICAN NEUROLOGICAL ASSOCIATION.

PHILADELPHIA, NEW YORK, CHICAGO:
THE F. A. DAVIS COMPANY, PUBLISHERS.
1897.

Entered according to Act of Congress, in the year 1890, by
F. A. DAVIS,
In the Office of the Librarian of Congress, at Washington, D. C., U. S. A.

Philadelphia, Pa., U. S. A.:
The Medical Bulletin Printing House,
1231 Filbert Street.

AUTHOR'S PREFACE TO FIRST EDITION.

THE following lectures were delivered during the winter of 1883–4, before an audience composed of practicing physicians. It was the endeavor of the author to lay before his hearers (who were already familiar with the coarser anatomy of the brain) all that had been discovered in regard to its finer structure. It was important, too, to present this, so far as possible, as a harmonious whole. Much that was in controversy could barely be mentioned, while here and there only one view of a disputed question was given,—that view which appeared most likely to be correct, either from the author's own investigations or from the writings of trustworthy authors. This would be absurd if this work pretended to be anything more than an introduction into the study of the structure of the central nervous system. He, however, who wishes to inform himself still more accurately in this direction will find all that he desires in the magnificent volume of Wernicke, and particularly in the superb works of Meynert and Flechsig. Besides these, we possess in Schwalbe's Quain-Hoffmann's hand-book a very clear and comprehensive exposition of the anatomy of the brain. The student may also consult with great benefit the work of Henle, which is based mainly on his own views and investigations. After searching these authors, he will find still further sources of knowledge in the works of B. Stilling, Kölliker, Gudden, Clarke, and others.

The author has in his own work (the results of which cannot at present be published *in extenso*) followed principally the method of investigation introduced by Flechsig, and has thereby come to entertain some views which differ from those commonly accepted. He has ventured, however, to introduce the results of his own investigations into this little monograph only so far

as that could be done without the addition of numerous cuts and prolonged explanations, which the limits of the work would not permit.

Inasmuch as it would be impossible to give even an incomplete list of the authors who have written on this subject, the writer has almost wholly ignored names. Only in the first chapter has he tried to mention those who began the structure at which we are still laboring.

The author, in common with all those who have actually worked in this difficult field, well knows that very few facts are indisputably settled, and that no region of anatomy is more subject to change than the one under consideration. He, therefore, himself calls attention to the fact that possibly here and there a line or point may be laid down a little too confidently. This, however, has nowhere been done in the interests of didactic clearness alone.

THE AUTHOR.

FRANKFORT-ON-THE-MAIN, May, 1885.

FOOT-NOTE TO AUTHOR'S ORIGINAL PREFACE.

The student who may be anxious to keep himself posted on the advances made in the study of cerebral anatomy will do well to consult Dr. Edinger's annual reviews of the current literature of the subject in Schmidt's *Jahrbücher*. These reviews have been published regularly since 1886.

THE EDITOR.

AUTHOR'S PREFACE TO SECOND EDITION.

The work on the central nervous system, which now for the second time appears before the public, has undergone many changes and been added to in some respects.

Much that is new has been discovered during the last four years. The author has endeavored to embody the most important of these discoveries in this book. The chapters on histology and histogenesis have been entirely rewritten. At some points nothing new has been added, but the old facts have been presented in a new form (fornix, cornu ammonis, etc.).

Continued investigations have led the author to modify his views in many respects. In accordance with this, the sections on the oculomotor, the acoustic, and the fibres of the deep marrow have been entirely rewritten. The discoveries which were published shortly before the appearance of this book concerning the course of the tracts in the posterior roots permitted us to adopt a much more simple plan of the structure of the spinal cord than was possible in the first edition.

The wish expressed on many hands that this little work should be adapted to the needs of those who wished to practice under its guidance has been complied with, in that the number of cuts has been increased and the description of individual regions been made more exhaustive.

A treatise on the comparative anatomy of the nervous system, based on personal investigation, has been embodied in the work. This addition, which permits us to take a more general morphological view of the macroscopic structures, will also serve as a guide to those who wish to pursue independent courses of study in this most important portion of brain anatomy.

No comprehensive description of the finer brain-structure

in the lower animals can as yet be given; still, matter bearing on this subject will be found scattered here and there throughout these pages.

Even now, when, by reason of unsatisfactory methods of investigation, little is known of the brains of the lower animals, still, enough has been ascertained to show that a careful study of the conditions there prevailing will enable us to penetrate farther into the finer structure than when the mammalian brain was the principal object of investigation.

There must be a certain number of anatomical conditions which are common to all vertebrates—those which permit the simplest expressions of the activity of the central organ. It only remains to discover some animal or some stage of development in which this or that mechanism exists in such a simple form that it can be easily and clearly comprehended. If we have thus once discovered the course of some tract of fibres or the arrangement of some group of cells, we can ordinarily recognize them in situations where the picture is blurred by the presence of other structures.

The search after these fundamental lines in the structure of the brain is the present task of brain anatomy. Once we have accomplished this, it will be easy to understand the complicated conditions present in the more highly organized brain.

EDINGER.

FRANKFORT-ON-THE-MAIN, May 1889.

AUTHOR'S PREFACE TO ENGLISH EDITION.

MODERN NEUROLOGY owes so much to the labors of American physicians that the author deems it a special honor that his book is considered a fit guide for physicians across the ocean in their studies of the most difficult branch of anatomy.

My best thanks are due to the translators, Dr. C. Eugene Riggs and Dr. Vittum, for their efforts in bringing the author into relation with English-speaking physicians.

If this book, in its new form, prove an incentive to further work, and if it be productive of some good, considerable praise is due to the translators.

EDINGER.

FRANKFORT-ON-THE-MAIN, 20 GÄRTNERWEG,
May, 1890.

EDITOR'S PREFACE TO AMERICAN EDITION.

The great desire to find for my class in the State University an authoritative treatise on the structure of the central nervous system first suggested to me the translation of Dr. Edinger's work.

I feel, in presenting these twelve lectures to the English-speaking profession, that the student and progressive practitioner are assured of a reliable guide to a more thorough comprehension of this most difficult and intricate subject. Their scope and character are best explained by the author in his own preface.

Most fully do I appreciate the cordial indorsement given by Dr. Edinger to the American edition. I wish, especially, to extend to my friend, Dr. B. Sachs, my sincere thanks for the hearty encouragement and the assistance without which this work would never have been undertaken; and gladly do both Dr. Vittum and myself acknowledge his valuable aid in overlooking translation and proof. Thanks are also due to the publisher, Mr. F. A. Davis, for his untiring effort to render this American edition worthy of the original.

C. Eugene Riggs.

595 Dayton Avenue, St. Paul,
August 1, 1890.

TABLE OF CONTENTS.

LECTURE I.

PAGE

A Review of the History and Methods of Investigating the Central Nervous System, ... 1

LECTURE II.

Embryology and Comparative Anatomy of the Brain, . . 13

LECTURE III.

The General Conformation and Histology of the Brain, . 31

LECTURE IV.

The Convolutions and Fissures of the Surface of the Cerebrum, ... 45

LECTURE V.

The Cortex of the Fore-Brain, the White Substance of the Hemispheres, the Commissures, and the Corona Radiata, 63

LECTURE VI.

The Corona Radiata, the Corpus Striatum, the Thalamus, and the Subthalamic Region. The Structures at the Base of the Brain 85

LECTURE VII.

The Subthalamic Region, the Corpora Quadrigemina and the Origin of the Optic Nerve, ... 103

LECTURE VIII.

The Pons and the Cerebellum, ... 127

LECTURE IX.

PAGE

The Roots of the Peripheral Nerves, the Spinal Ganglia, and the Spinal Cord, ... 147

LECTURE X.

The Spinal Cord and the Commencement of the Medulla Oblongata, ... 173

LECTURE XI.

The Medulla Oblongata and the Tegmentum of the Pons, . 195

LECTURE XII.

The Pons—Final Review, ... 215

Index, ... 227

Structure of the Central Nervous System.

LECTURE I.

A REVIEW OF THE HISTORY AND METHODS OF INVESTIGATING THE CENTRAL NERVOUS SYSTEM.

GENTLEMEN: The anatomy of the central nervous system, with the main features of which these lectures are to make you familiar, has engaged the serious attention of numerous investigators since the *renaissance* of anatomical science.

Vesalius, Eustachio, Aranzio, Varolio, and Fallopia laid the foundations upon which it was possible to build in a later age. As early as the seventeenth century several good-sized monographs appeared, which, considering the methods of investigation then pursued, may be regarded as exhaustive. Such are the books of Th. Willis, of Raim, and of Vieussens. And yet at this time Willis could describe such structures as the corpus striatum, the anterior commissure, the pyramids, and the olivary bodies as new. Important contributions to the anatomy of the brain were made by F. D. Sylvius, J. J. Wepfer, and Van Leuwenhoeck. It was the latter, indeed, who first instituted microscopic examination of the brain. Toward the end of the last century v. Malacarne, in Italy; S. Th. von Sömmering, in Germany; and Vicq d'Azyr and Rolando, in France, materially increased our knowledge of the brain.

At the beginning of the present century hardly anything of importance remained to be added to the description of the coarser structure of the nervous system. Nevertheless, hardly any advance had been made in what we to-day regard as the most important part of our knowledge of brain anatomy; that is, the minute connections of the different parts of the brain and the course of nerve-tracts. Even comparative anatomy, the study of which was taken up during the first part of this

century, added nothing to this knowledge. Whatever it was possible to discover by the coarse, macroscopic methods of investigation was discovered by Reil, Gall and Spurzheim, F. Arnold, C. B. Reichert, Foville, Burdach, and others.

Reil, in particular, who first brought into general use the process of artificially hardening the brain, discovered a number of anatomical facts, which were the result of closest observation. As his most important discoveries must be reckoned the arrangement of the corona radiata, the nerve-tracts of the crus cerebri, whose relation to the fibres of the corpus callosum, which pass transversely through it, he was the first to recognize. The lemniscus and its origin in the corpora quadrigemina, the lenticular nucleus, the island, and many other parts were first made known through his investigations. As a landmark at the end of this older period, we may regard Burdach's work on "The Structure and Life of the Brain," which appeared in 1819 and contained all that had been discovered up to that time, besides adding much new material.

Up to about the middle of this century the most prominent methods of investigation were anatomical dissection with the knife and teasing out fibres from hardened specimens of brain with forceps. By the latter method Gall, Burdach, Reil, F. Arnold, and Foville discovered much that was new. To Tiedemann and Reichert is due the chief credit of introducing the study of embryology, from which we have learned much concerning general morphological conditions.

But after Ehrenberg (1833) proved that "the organ of mind" consisted of innumerable microscopic "tubules;" after Remak (1838) had given a more accurate description of the ganglion-cells, and Hannover (1840) had shown their connection with the nerve-fibres, it was plain that a simple process of teasing could never give the desired insight into the structure and arrangement of the central nervous system. To B. Stilling is due the great credit of originating and bringing into use a new method, viz., the preparation of thin sections, or, rather, of

whole series of sections, which are made in different but in definite directions through the organ to be examined.*

The sections so prepared were carefully examined throughout, the pictures they presented combined, and thus the structure and arrangement of the central nervous system were determined. By means of this method and the studies which he instituted by its use, Stilling laid the foundation of the modern anatomy of the spinal cord, the oblongata, the pons, and the cerebellum. On the 25th of January, 1842, Stilling froze a piece of spinal cord at a temperature of 13° R., and then, with a scalpel, made a moderately thin cross-section. "When I placed this under the microscope," he writes, "and, with a power of 15 diam., saw the beautiful transverse striations (central nerve-tracts), I had found a key which would reveal the mysteries of the wonderful structure of the spinal cord. Not more joyfully did Archimedes cry out, 'Eureka!' than I, at the first sight of these fibres."

Stilling's method is the one now most used in investigations of the central nervous system. It is rendered very much easier by the splendid hardening which these organs undergo in dilute chromic acid, or in a solution of chromic salts,—a discovery of Hannover and Eckhardt.

The sections are made "free-hand," with a razor, or, better, with a microtome, which cuts much more exactly and enables us to make larger and more even sections. Welcker, Rivet, Weigert, Thoma, Gudden, Schiefferdecker, and others have been of service in constructing microtomes adapted to the purpose. We can now divide an entire human brain into an unbroken series of sections, less than $\frac{1}{10}$ millimetre in thickness.

These sections may be examined unstained. All that Stilling discovered was found in such unstained sections. It is better, however, to use staining fluids.

To Gerlach is due the credit of first calling attention (1858) to the advantages to be derived from staining the sections in

*Thin sections of the central nervous system had been made before Stilling's time (*e.g.*, B. Rolando, 1824), but the reconstruction of the organ by the combination of extended series of sections was first done by Stilling.

carmine. As time passed on, many new staining methods were devised, particularly with aniline colors (nigrosine, etc.).

But it is only very recently (1883) that we have learned from Golgi a method which brings out ganglion-cells more distinctly than the old one of Gerlach. This method rests on the production of a deposit of silver salts in the cells and their processes. The course of the fibres in the central nervous system is not made much more distinct by staining with carmine. It is possible, however, by a method of staining with hæmatoxylin introduced by Weigert (1884), to color even the finest nerve-fibril a deep blue-black, and so, making use of Stilling's method, it is easy to trace the course of the fibres much farther than was formerly possible.

The stained sections are, in accordance with the special instructions of Clarke (1851), dehydrated by placing them in alcohol, and then cleared up in some ethereal oil or xylol. But unstained sections also reveal the course of the fibres if cleared up in xylol, as was done by Henle and Merkel. This, however, does not always succeed. Beautiful pictures may be obtained by using the gold staining methods (Gerlach, Flechsig, Freud, and many others). Also, by staining the nerve-fibres with osmic acid (Exner).

Stilling's method has been followed by most of the investigators of the latter half of this century. At the close of each lecture I will give you the names of those to whom we are indebted for the most important part of our knowledge of that portion of the brain which is under consideration at the time. But even now you must be made familiar with the names of two men, Stilling and Meynert, to whom we are under the greatest obligations, because to them we owe our knowledge of the finer structure of the brain and spinal cord, and all the later investigators start out from points which have been settled by them.

Benedict Stilling laid the foundations of our knowledge of the anatomy of the pons, the cerebellum, the medulla oblongata,

and the spinal cord, in a series of masterly works, showing an industry never surpassed, and which will surely remain forever a *monumentum ære perennius* of the great physician of Cassel.

Meynert, however, not only examined carefully and systematically every region of the brain and spinal cord, both by sections and by teasing; but by these means he made more new discoveries than had been made by any previous investigator with the exception of Stilling. He not only did these things, but, with the inspiration of true genius, he set up a theory of the structure of the brain, based on its finer anatomy, which still exerts an influence on the anatomy and psychology of to-day, and spurs us on to further discoveries.

It follows, from the very nature of Stilling's method, that the course of a nerve-tract can only be traced with certainty so long as the component fibres are not interrupted by ganglion-cells, do not pass out of the plane of the section, do not enter a plexus of fibres, or split up into innumerable fibrils to be disdistributed in every direction. Even in the spinal cord of the smallest animal it rarely occurs that a nerve-fibre can be observed running its whole course in the plane of one section. It is, on the contrary, the rule of the central nervous system that the nerve-tracts from periphery to centre are broken up by interpolated ganglion-cells, and rendered difficult to follow by the frequent interchange of fibres.

Efforts were made, therefore, particularly after we had begun to learn something in this difficult field from the works of Stilling, to devise further methods which would enable us to discover and locate the nerve-tracts. It is known that Waller, in 1852, showed that divided nerves degenerate in definite directions. Before this (1850), Türk had found that a break in the conductivity of the spinal cord led to degenerations which spread upward in different columns from those affected by the descending degenerations. By his labors, and those of Bouchard, Flechsig, Charcot, Monakow, and many others, it was ascertained that perfectly definite sets of fibres always occupy

the same relative position in both the brain and spinal cord; that these fibres, when degenerated, are easily distinguished from the surrounding healthy tissues, and so can readily be followed up along their whole course. The study of this secondary degeneration has been of value in the field in which we are now laboring. It promises still richer harvests in the future.

The tract of fibres along which such a degeneration commonly spreads is called a system of fibres. A number of diseases of the spinal cord, either at their beginning or throughout their whole course, involve only certain systems of fibres; for instance, the posterior columns of the cord. Such diseases are called systemic diseases. The investigation of such systemic diseases may also be of service in increasing our knowledge of the course of fibres (Flechsig, Westphal, Strümpell). By the accurate study of pathological changes Charcot and his pupils, especially Pitres, Férè, Ballet, Brissaud, and others have done fruitful work in the domain of brain anatomy.

Occasionally structural abnormalities make it easier to recognize one or another of the nerve-tracts than is the case in the normal brain. Thus Onufrowics and Kaufmann had the opportunity to examine cases of defective corpus callosum in which, owing to the absence of fibres of the latter, other bundles of fibres appeared with a distinctness never before seen.

It was a natural advance upon the study of these degenerations to perform section of definite parts of nerve-roots or of the spinal cord, for the purpose of studying the resulting artificial secondary degenerations, and thus pressing farther into the structure of the organs. Thus, for example, the section experiments of Schiefferdecker and Singer very materially increased our knowledge of the course of the roots of the spinal nerves.

If either peripheral or central nerve-substance is removed from newborn animals, the fibres connected with the part removed cease to develop and are gradually destroyed, apparently because the development of the medullary sheath is

stopped. In 1870 Gudden made use of this fact, and proposed a new method of investigation, which promises well for the future. For example, after the extirpation of an eye he followed up the resulting atrophies in the brain with sections, etc., and found the proximal central ending of the optic nerve. On whatever part of the brain he experimented and afterward examined by sections, he brought to light new and important facts. Besides Gudden, we owe much to Mayser, Ganser, Forel, Monakow, and Löwenthal for important knowledge gained by this method concerning the course of fibres in the spinal cord, the method of origin of different cranial nerves, the course of the lemniscus in the brain, and much more besides.

Occasionally cases present themselves where nature has performed Gudden's experiment on human beings; thus, I was once able to examine the atrophic nerve-tracts caused by the intra-uterine amputation of an arm, and to trace them high up into the spinal cord. At another time I had an opportunity to examine the nervous system of a child who had suffered an extensive softening of the cortex of the parietal lobe, either before or just after birth. The crossed pyramidal tract in the spinal cord was entirely wanting. If division of the peripheral nerves occur later in life, as in amputations, the central changes are not so marked that we can trace out the course of nerve-tracts in the spinal cord or brain. Friedlander and Krause, however, have cleared up the structure of the spinal nerve-roots and of the spinal ganglia by the study of these "amputation (spinal) cords."

Our knowledge of the course of fibres has advanced considerably by means of the study of secondary atrophies and degenerations. Still greater advances have been made, however, by a method based upon the study of the development of the medullary sheath.

P. Flechsig deserves the credit of introducing this method of investigation, which to-day appears to me to be the most promising of all methods in use.

In a series of communications (1872–1881) and later, in a larger work on "The Course of Nerve-tracts in the Brain and Spinal Cord" (1876), he has shown that the various tracts of fibres which look so much alike on all sections of the adult brain are markedly differentiated during the embryonic period,

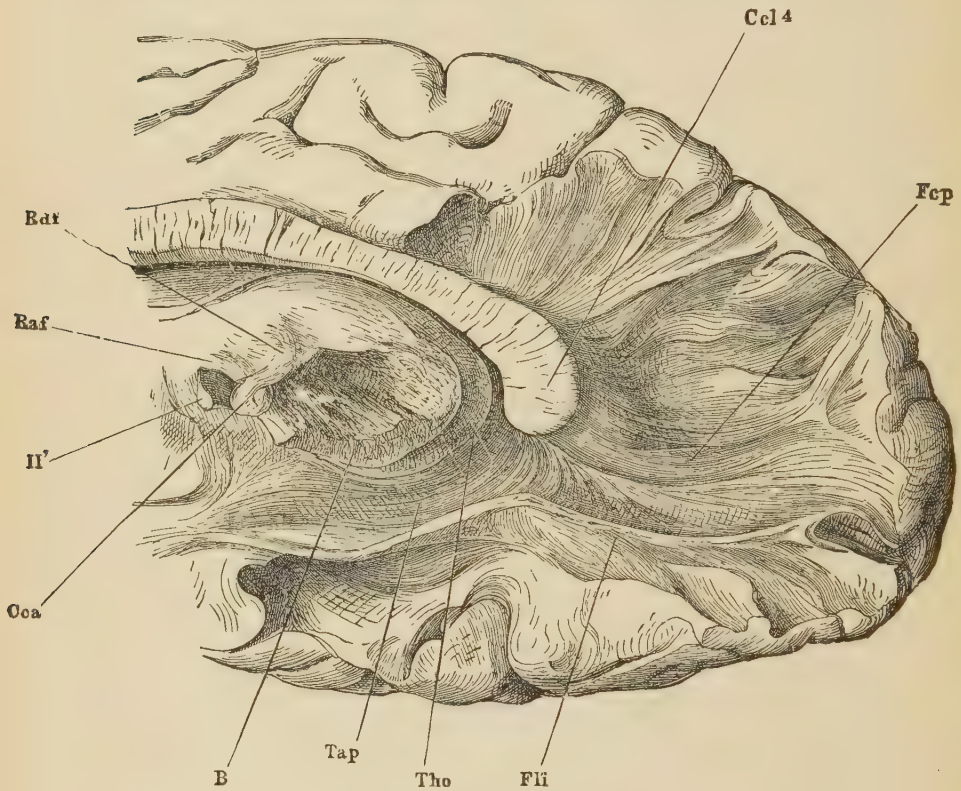

FIG. 1.

The fibres of the corpus callosum, shown by tearing the hardened specimen with forceps. (After Henle.)

by the fact that they acquire their medullary sheaths at different times. Whole "systems" in the cross-section of the spinal cord are still clear and transparent at a time when others are white and contain medullary substance. The following up of these white portions, in both cross and longitudinal sections, is very much easier, and gives very much more certain results than

tracing out a fasciculus of nerve-fibres in the fully-developed organ. In order to give you an idea of the peculiarities of the methods just mentioned, I will first show you a specimen which was obtained by teasing, and which shows the course of the fibres making up the corpus callosum (Fig. 1). The accompanying cut (Fig. 2) is made from a frontal section through the cerebrum of a 9 months' still-born fœtus. In the adult the whole field shown here is filled with fibres, which, crossing and anastomos-

FIG. 2.

Frontal section through the posterior portion of the fissure of Sylvius of the brain of a 9 months' still-born child. The medullary fibres are shown black. In reality they appear white upon a gray back-ground.

ing with each other, cannot be traced up. In the case of our fœtus, however, of all the various fibres of the cerebrum, only one bundle, the one called the tegmental tract, contains medullary matter. Nowhere in the cerebrum, except at this point, can we find medullated fibres. Hence, it was easy for Flechsig to discover and partly trace out the course of the fasciculus tegmenti as a distinct bundle among all the many little-known nerve-tracts of the brain.

The third figure shows you a cross-section through the cervical region of a spinal cord taken from a man who lost his left arm before birth. You see that the gray and white substances, particularly the former, are markedly atrophic on the left side. A more careful examination of the extent of this atrophy gave a clue to the location of the central termination of the divided nerves.

Our understanding of the general morphology of the central nervous system has been advanced by nothing more than by comparative anatomy and embryology. Questions of great importance have been solved on the brains of fishes and amphibians. Leuret and Gratiolet, Meynert, Gottsche, Fritsch, Miclucho-Maclay, Rabl-Rückhard, Rohon, Wiedersheim, Guldberg, Spitzka, and many others have rendered service in the field of comparative anatomy. What we know of the embryological development of the organs we are now studying we owe to Kölliker, His, Tiedemann, Reichert, von Mihalkovics, Götte, Dursy, and Löwe. The results of comparative anatomy have not been so great as might have been expected so far as marking out the course of nerve-fibres is concerned.

FIG. 3.

Section through the cervical cord of a man 45 years old, who suffered an intra-uterine amputation of the left forearm.

Unlike the outer configuration of the brain, the finer structure has awakened little interest; although the latter may be said to be the kernel of the matter, while the former is but the outside shell. It may be that this was largely due to the unsatisfactory nature of the methods of study available at the time. Only a few—among whom Stieda, Mayser, Fritsch, Osborn, Bellonci, and Ahlborn may be mentioned here—succeeded in distinguishing a few tracts and marking out a few ganglia and the origin of a few nerves among the complicated net-work of nerve-fibres which is present even in the lowest vertebrate. For, simple and easily understood as the outer config-

uration often is in the lower vertebrates, yet the inner structure, particularly of those regions of the brain lying caudad of the optic lobes, is often not less complicated than is the case in mammals. The cells and fasciculi of fibres which are necessary for the accomplishment of the simplest motor, sensory, or psychic function must everywhere be the same, and even in the larvæ of the cyclostomata they are no longer perfectly simple and easily comprehended. I have, therefore, endeavored, in order to come nearer to a solution of the questions before us, to unite the method of comparative anatomy with that of studying the development of the medullary sheath. We can now stain and trace out each individual medullary sheath. In fact, it was by the method of comparative embryology that we succeeded in discovering the desired primitive conditions in the embryos of the lower animals, and were able to distinguish a number of nerve-tracts which are common to all vertebrates.

You see, gentlemen, the goal can be reached in many ways. In the case of every new question proposed, we must ask ourselves which method is the best to use, and, above all, where we may expect to find the simplest conditions. Seldom will an examination of the adult human organ attain the object in view. More often we shall be compelled in some way to bring about by artificial means a less complicated state of affairs.

From time to time it has been attempted to embrace all that was known in regard to the finer structure of the central nervous system in a diagrammatic representation. The oldest diagrammatic representation of the fibres of the brain with which I am acquainted is to be found in Des Cartes' "Tractatus de Homine," which appeared in 1662. Of the newer works belonging to this category are the diagrams of the spinal cord by Kölliker, Ludwig, Bidder and Leydig, and the celebrated diagram of B. Stilling. The plates of Meynert embrace a larger field (from the spinal cord to the corpora quadrigemina), and those of Aeby, Flechsig, and Jelgersma (the whole central nervous system).

In the following lectures, gentlemen, you will regard

descriptions and drawings as somewhat diagramatic. They only serve the purpose of bringing to your attention, in the most comprehensive manner possible, the most important facts in regard to the course of fibres in the central nervous system. Much is still in dispute, but dimly marked out, with many details wanting. Wherever it was practicable I have given not only those facts which were discovered in a purely anatomical way, but also those tracts which have been determined by well-observed pathological facts. A diagram is not always a picture of the demonstrated course of fibres; it is often enough only a graphic representation of the conclusions which have been drawn from great numbers of observations.

A diagram is a changing structure. It must be improved, now here, now there. Certain parts often need to be torn down and rebuilt. It has been contended that we ought not to make use of diagrams in a subject so full of gaps as is our knowledge of the structure of the central nervous system. Let us rather hold, with old Burdach, who wrote in 1819, "The gathering together material for the building is not all that is necessary. Every time that a new supply is obtained, we should renew our attempts to fit it into the building. By thus giving it a form the spirit of investigation is not hampered in its advance; on the contrary, it is when we first obtain a view of the whole that we see the gaps in our knowledge and learn the direction which our investigations must take in the future. May the attempts at this structure ever be renewed. No one who works at it but adds something to our knowledge."

[Among recent treatises on the anatomy of the nervous system are the following:—

Kölliker, Handbuch d. mikrosk. Anat. Leipzig. 1854.—Meynert, Vom Gehirne der Saugethiere, Stricker's Handb. d. Lehre von den Geweben, 1870.—Meynert, Psychiatrie, I. Wien, 1884.—Henle, Handbuch d. Anatomie d. Nervensystems. Braunschweig, 1879.—Luys, Recherches sur le Systeme nerveux cerebrospinal. Paris, 1865.—W. Krause, Handbuch d. menschl. Anatomie, I Bd. Hannover, 1876.—Wernicke, Lehrb. d. Gehirnkrankh. I. Cassel, 1881.—Schwalbe, Lehrb. d. Neurologie. Erlangen, 1881. (Contains most of the literature up to 1881.).—Huguenin, Allg. Pathol. d Krankh. d. Nervensystems, I. Zurich, 1873.—Kahler, Nervensystem in Tolds. Gewebelehre, 2 Aufl., 1888.—Obersteiner, Anleitung beim Studium des Baues der nerv. Centralorg. Wien, 1888.—Mendel, Artikel "Gehirn" in Eulenburg's Realencyklopädie, 2 Aufl. Wien, 1886.]

LECTURE II.

EMBRYOLOGY AND COMPARATIVE ANATOMY OF THE BRAIN.

GENTLEMEN: The hollow medullary tube of the vertebrate embryo presents at a very early stage three vesicular enlargements at that end which later on develops into the brain. These

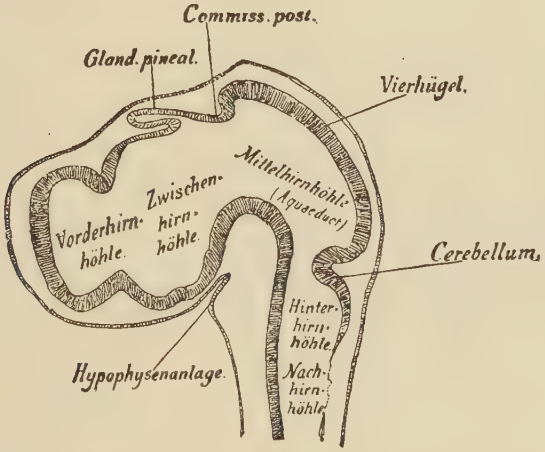

FIG. 4.

Longitudinal section through the head of an embryo chick of 4½ days. The five brain-vesicles are pretty clearly marked. In the roof of the inter-brain is a fold which later on becomes the pineal gland. The epithelium of the pharynx is being pushed up toward the base of the brain, and is the first rudiment of a portion of the hypophysis. (After Mihalkovics.)

Hinterhirnhöhle, Hind-brain cavity.
Hypophysenanlage, Rudiment of hypophysis.
Mittelhirnhöhle (*aquæduct*), Mid-brain cavity.
Nachhirnhöhle, After-brain cavity.
Vierhügel, Corpora quadrigemina.
Vorderhirnhöhle, Fore-brain cavity.
Zwischenhirnhöhle, Inter-brain cavity.

are the (primitive) fore-brain, mid-brain, and hind-brain. The latter is soon divided into two parts by the cerebellum growing out of the anterior portion of its roof. These two divisions eventually become the cerebellum and the medulla oblongata (after-brain).

The wall which closes the primary fore-brain in front is called the "embryonic terminal lamina." From this there are

developed at an early stage, in almost all vertebrates, two smaller vesicles,—the hemispheres or the secondary fore-brain. These, which at first are small, insignificant structures, soon grow to relatively enormous proportions in mammals, and, bending backward, cover most of the other brain-vesicles. At last they lie, cap-like, over the inter-brain (thalamus), the mid-brain (corpora quadrigemina), and the hind-brain (cerebellum and pons). Of course, in spite of this bending backward of the anterior vesicle, all the cavities (which are the ventricles of the adult brain) still communicate with one another. After the development of the secondary fore-brain, the primary fore-brain is called the inter-brain. The roof of this inter-brain remains throughout life as a simple layer of epithelium. At the point of confluence with the fore-brain numerous blood-vessels are developed downward from the cranial cavity, which push this epithelial layer on before them. This mass of blood-vessels covered with epithelium, which thus projects into the cavity of the brain, is called the choroid plexus. Inasmuch as the hemispheres have been developed from the inter-brain, their inner border must be continuous with this plexus.

FIG. 5.

Longitudinal section through the whole brain of a newborn cat. The inter- and mid- brains covered by the fore-brain. Magnified 1 : 2.

Hinterhirn, Hind-brain. *Mittelhirn*, Mid-brain.
Nachhirn, After-brain. *Vorderhirn*, Fore-brain.
Zwischenhirn, Inter-brain.

In the frontal section of an early human embryo, shown in Fig. 6, this is plainly to be seen. In this cut, too, you can see the cavity of the undivided primary fore-brain, as the ventriculus medius, while the cavities of the hemispheres are marked as ventriculi laterales. The choroid plexus sends processes into the lateral ventricles, which are called the lateral choroid plexuses. The point where the wall of the hemisphere merges

into the simple layer of epithelium is called the margin of the hemisphere. This margin is, at a later period, clearly marked throughout its entire length by a bundle of white fibres,—the fornix.

After the most important portions of the human cerebrum have begun to develop, it has the appearance represented in the accompanying Fig. 7. It has grown out backward and bent downward. At the point where the corpus striatum (which will be mentioned later) is situated internally, the outer wall has not expanded so rapidly as in the other regions of the hemispheres; so that there has developed or, rather remained a depression,—the fissure or fossa of Sylvius. There can now be easily distinguished an anterior or frontal lobe, a posterior or occipital lobe, and between the two a parietal lobe. That part of the hemisphere which lies below the fissure of Sylvius is called the temporal lobe. Internally the hemispheres are hollow, and naturally their cavities conform to the general shape of the brain. That part of the ventricle which lies in the frontal lobe is called the anterior horn, that which lies in the occipital lobe the posterior horn, and that which lies in the temporal lobe the inferior horn. At this stage of development the

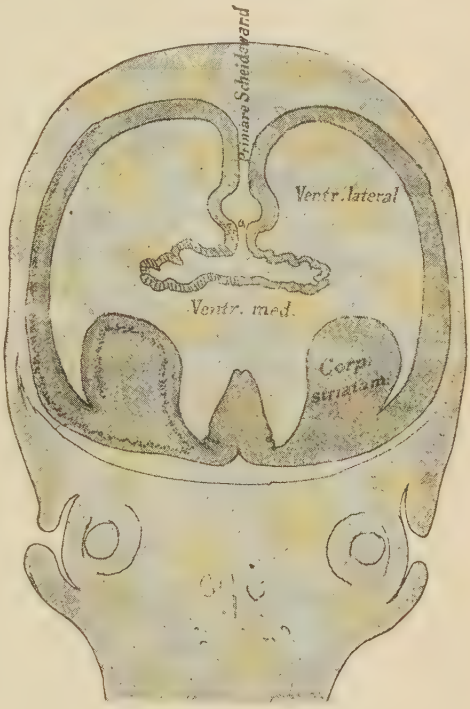

FIG. 6.

Frontal section through the head of a human embryo of 2½ months. Shows the involution of the forebrain vesicle and the rudiment of the corpus striatum. Observe the prolongation of the cortical layer into the latter, and see how it covers both the inner and outer surfaces.

Primäre Scheidewand, Primary division-wall.

median wall of the hemispheres demands our especial attention. That this wall along its ventral border is everywhere continuous with the epithelium of the choroid plexus has already been shown. This condition is not changed when it is carried downward along with the curving temporal lobe. From the base of the embryonic terminal lamina to the tip of the temporal lobe this border passes in a curve, marking the location of the fornix. In the anterior portion of the brain, somewhat dorsad of the fornix, the fibres of the corpus callosum are developed, evidently from a portion of the embryonic lamina terminalis. They pass across from one hemisphere to the other in a line which forms an acute angle with the fornix. The substance between the two,

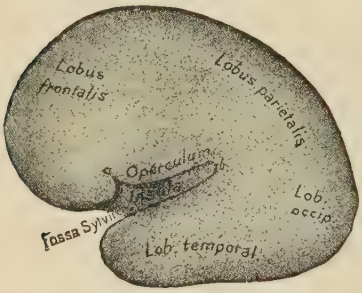

FIG. 7.

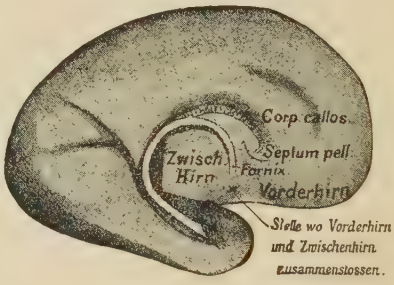

FIG. 8.

FIG. 7.—Brain of a human embryo of the fourth month.

FIG. 8.—Inner aspect of the embryonic hemisphere, shown in Fig. 7. Shows the inner lower border of the hemisphere, which becomes thickened into the white medullary line of the fornix. The latter, however, only becomes medullary after birth.

Stelle wo Vorderhirn und Zwischenhirn zusammenslossen, Point where the fore-brain and mid-brain meet.

which, of course, consists of the two thin layers of the primary division-wall between the hemispheres, is the septum pellucidum. These are important points, which I beg you to study carefully in the accompanying figures.

In the section shown in Fig. 9 you will observe an anatomical structure not before mentioned. On the floor of the cerebrum lies a thickening of the same, which projects, free, into the ventricle,—the corpus striatum. That layer of the brain-wall which later, as cortex, gives rise to the fibres of the cerebrum, has already begun to appear. You see that an analogous layer is present in the corpus striatum. In fact, in the adult animal nerve-fibres originate there just as in the cortex.

Many fibres which originate in the cerebrum and pass into the more deeply situated portions of the nervous system must,

FIG. 9.

Frontal section through the corpus striatum of a human embryo of 16 weeks. Between the rudiments of the nucleus caudatus and those of the nucleus lentiformis can be seen the internal capsule, in which also fibres can be seen passing from the wall of the hemisphere. Notice the arrangement of the cells and the course of the fibres.

Hemisphärenwand, Wall of hemisphere.

in order to reach their destination, pass directly through the corpus striatum. This structure is, therefore, divided into two portions, an inner and outer, by the mass of passing fibres.

The outer portion is called the nucleus lentiformis, and the inner the nucleus caudatus. The mass of fibres between them has received the name of internal capsule. This division of the corpus striatum is plainly to be seen in an embryo of four months, but its connection with the cortex of the hemisphere has already disappeared, and the nucleus lentiformis and nucleus caudatus appear as independent gray bodies. (See Fig. 9.)

The corpus striatum lies along the whole floor of the hemispheres. At its caudal end, however, it is very narrow, and only the inner portion is demonstrable at all points. This appears in all the cross-sections of the cerebrum as the tail of the nucleus caudatus. The outer portion, the nucleus lentiformis, is much shorter. As you see, the nucleus caudatus projects free and clear into the ventricle. The nucleus lentiformis also does at first. In later embryonic life, however, the narrow fissure between it and the hemisphere-wall becomes so small that it is no longer demonstrable. But we can always, even in adult life, separate the hemisphere-walls from the outer surface of the nucleus lentiformis without tearing any fibres. In the adult brain the situation of the former fissure is of importance, for here cerebral hæmorrhages easily occur, and the mass of effused blood, if it be not too great, fills up the space between the hemisphere-wall and the outer division of the lenticular nucleus.

The peripheral nerves appear very early. According to the extremely important discoveries of His, there are two methods of origin for the two kinds of fibres. All motor fibres arise as axis-cylinder processes from cells situated in the ventral portion of the medullary tube. Each cell sends out a fibre which passes to the surface, and there unites with neighboring fibrils, to form a ventral nerve-root. The sensory fibres, which, as a rule, emanate from the dorsal region, have an entirely different origin. They arise not in the central organ, but outside of it, in the ganglia which lie opposite it along its whole course. The cells of these ganglia (spinal ganglia and ganglia of the cranial nerves) send out fibres in two opposite directions. One of these

fibres passes to the central organ; the other grows toward the periphery as a sensory nerve.

The ganglia which are called upon to play so important a part in the peripheral nervous system first appear in the form of a groove, the sides of which, later, close so as to form a ridge (ganglionic ridge). This ridge lies on both sides of the central organ, and at a very early period becomes separated into the individual ganglia. From it, opposite the secondary fore-brain, is developed the olfactory fossa; opposite the inter-, mid-, and hind-brains, the complex of the trigeminus ganglia; opposite the after-bran we see the ganglia of the acustico-facialis, of the glosso-pharyngeus and of the vagus, developed from this ganglionic ridge. The auditory fossa, which lies between them, apparently originates in this ridge. (His, oppos. Beard.) Further caudad, the spinal ganglia replace the above-named ganglia of the cranial nerves, along the sides of the spinal cord. The roots of all the above-mentioned sensory cranial nerves and of the posterior roots of the spinal cord issue, therefore, from the ganglia and grow into the central organ. In the spinal cord there is a corresponding dorsal sensory root for each ventral motor root. In the brain, however, this is not the case. The distribution of the motor nuclei does not correspond closely to the divisions of the complex of ganglia. The ganglionic ridge has a greater number of segments, and several motor nuclei are equivalent to a single complex of ganglia. These are the main points in the development of the human brain.

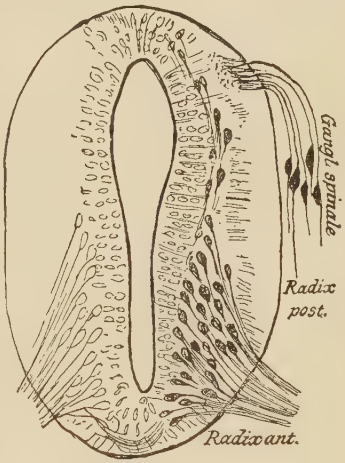

FIG. 10.

Transverse section through the spinal cord of a human embryo of 4 weeks. Ventrad we see the anterior roots developing from the cells of the cord. Dorsad (from an embryo of 4½ weeks) the posterior roots grow centrally from the cells of the spinal ganglion. (Combined from designs by His.)

It is, however, of no small interest to examine the manner in which the development of the brain takes place in animals, proceeding from the lowest to the highest vertebrates. The limits set to these lectures will not permit us to enter the sometimes very important details of the course of fibres and the finer structure. You will, perhaps, most easily get an idea of the difference in arrangement, and see how now this and now that portion of the brain is most prominently developed, if you will examine the figures, 11–17. These figures represent, in a slightly diagrammatic form, sagittal sections through the brains of the various vertebrate classes. If you will first make yourselves

FIG. 11.

Diagram of a sagittal section through the brain of a vertebrate.

Hinterh., Hind-brain.
Mittelhirn, Mid-brain.
Nachh., After-brain.
Prim. V. H., Primary fore-brain.
Schluss Platte, Embryonic terminal lamina.
Second. Vorderh., Secondary fore-brain.
Zw. Hirn, Inter-brain.

familiar with the general diagram of a vertebrate brain (Fig. 11) you will easily understand the other figures. You here see that the primary fore-brain gives origin to the secondary fore-brain (hemispheres), by a bulging out of the lateral portions of the embryonic terminal lamina. You see how it protrudes ventrad into the infundibulum, and how its dorsal wall (driven inward by blood-vessels) forms the choroid plexus.

Farther back the roof is elongated into two sacs, of which the anterior is called the cushion of the epiphysis, and the posterior the epiphyseal tube. We recognize next the roof of the mid-brain (the corpus opticum or corpora quadrigemina), and adjoining this the involuted layer of the cerebellum. This

passes caudad in a thin lamella, the velum medullare posticum, to the dorsal region of the spinal cord. The lateral portion of the inter-brain, the thalamus, is not visible in the plane of Fig. 11. Secondary fore-brains developed from the primary fore-brain vesicle are not found in all animals. In the ray the anterior wall of this vesicle simply becomes enormously thickened, until it is a large structure which also contains the corpus striatum (Fig. 12). But in many sharks we can see little swellings on each side in front of this mass, the first rudiments of the hemispheres. The fore-brain of bony fishes contains a large corpus striatum, but the dorsal portion of this vesicle, the pallium, has not advanced beyond the embryonic state of a simple layer of

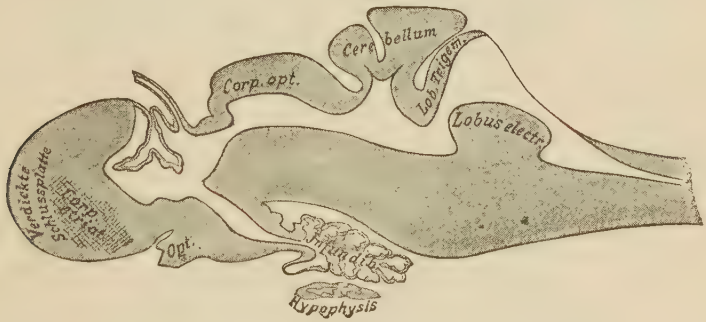

FIG. 12.

Brain of a ray.

Verdickte Schlussplatte, Thickened embryonic terminal lamina.

epithelium. From the fish up to the human being, the corpus striatum does not materially change its position or its relative size.

In the same region we find the same aggregation of ganglion-cells. In every case there arises from these cells a bundle of fibres which passes backward and terminates partly in the inter-brain, and in part passes farther back into the oblongata (basal fore-brain bundle). The pallium, however, must pass through many stages of development before there is evolved from the simple epithelial layer which we have just seen in fishes that massive structure which, in human beings, we call the hemisphere.

Even in the case of the amphibians, where two large, flat hemispheres, of an oval shape, spring from the primary fore-brain vesicle, their wall, composed of an outer layer of glia and an inner granular layer, contains only few and irregularly-distributed ganglion-cells. In reptiles we first meet with a deposit of pyramidal cells, disposed in several layers and covering most of the surface,—a true brain-cortex.

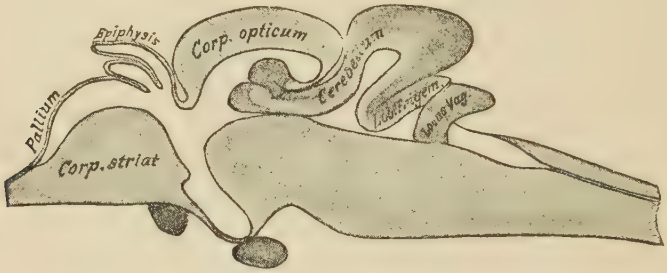

FIG. 13.
Sagittal median section through the brain of a bony fish.

This is most extensively developed in the median wall, and there are grounds for believing that this, the lowest cortical

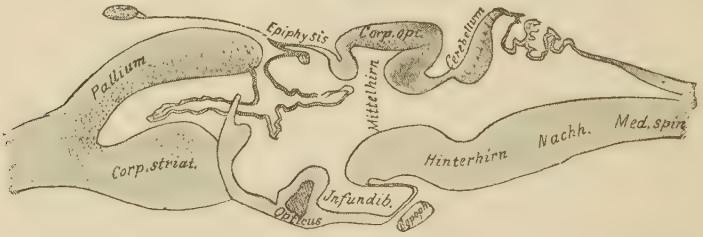

FIG. 14.
Amphibian brain. Diagram of a sagittal section.
Hinterhirn, After-brain. *Mittelhirn*, Mid-brain. *Nachh.*, After-brain.

formation, is the representative of the cornu ammonis in mammals (origin of the fornix, etc.). From this point on, the development of the fore-brain takes place in two different ways. In birds the corpus striatum attains a relative size and complexity found in no other class of animals, while the formation of cortex does not much increase. In mammals, however, the pallium, with its cortical layer, becomes a large structure, which causes the

corpus striatum to disappear in its depths, and, growing backward, envelops the more posteriorly situated inter- and mid-brains (in the human being the cerebellum as well).

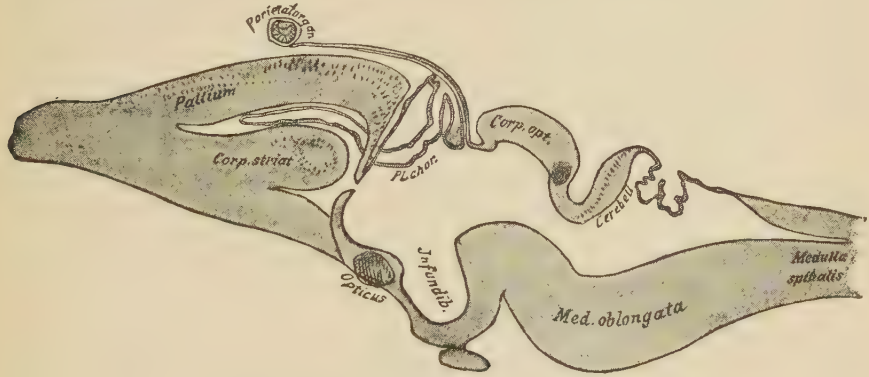

FIG. 15.
Brain of reptile. Diagram of a sagittal section.

The cortical layer which covers the pallium at almost all points must, on account of its great expanse, lie in numerous folds. These are absent only in the lowest mammals (lissencephalous

FIG. 16.
Brain of bird. Diagram of a sagittal section.
Mittelhirndach, Mid-brain roof.

mammals). In all others they are present in more or less abundance (gyrencephalous mammals). The arrangement of these folds, which is constant for the separate classes of animals,

depends on two factors,—the extent of the cortical layer which the particular class has acquired during the process of evolution, and the capacity of the skull.

This does not always keep even pace with the growth of the brain, inasmuch as it depends on other factors. The whole pallium of mammals not only grows backward, but it curves and swells downward as well (not visible in figure).

That portion of the hemisphere lying farthest forward, the frontal lobe, only comes into special prominence in the higher mammals, particularly man (Meynert). From this extensive cortical layer of the mammalian pallium arise a great mass of

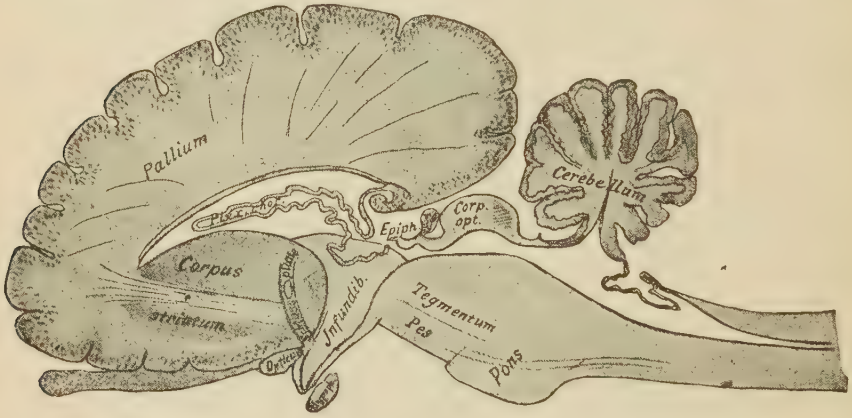

FIG. 17.
Mammalian brain. Diagram of a sagittal section.

fibres,—the corona radiata. These pass out of the hemisphere to terminate in the inter-brain, the hind-brain, the after-brain, and the spinal cord. Other large bundles pass through the hemispheres, connecting their different regions with one another. All these taken together form a great deposit of medullary matter under the cortex. The extent of this is relatively largest in human beings. In lower mammals it is only small. In the mouse, for example, it is insignificant. Besides this, there is developed in the cortex of all animals a thick net-work of medullary fibres, which serves to connect all parts with each other.

In all vertebrates, from the cyclostomata up to human beings,

there springs from the base of the fore-brain, on each side, a process whose cavity at first communicates with the cavity of the ventricles. These are the olfactory lobes. They are always covered with a cortex of peculiar structure, from which the non-medullary fibres of the olfactory nerves arise in many bundles. In the case of only a few animals (the cyclostomata, for example), a single olfactory nerve springs from each olfactory lobe, and, passing to the organ of smell, is divided into many branches. In mammals the anterior portion of the lobes becomes separated from the rest of the brain, and is known as the olfactory bulb. This is connected with the lobe proper by a long, slender process containing both cells and fibres,—the olfactory tract. In many mammals, and particularly in human beings, the olfactory lobe becomes atrophic, and little more is visible on the under surface of the brain than the olfactory bulb and tract.

The inter-brain is in all animals an elongated body, whose lateral walls contain, in the case of the lower vertebrates, two, and in higher several "thalamic ganglia." The walls thickened by these ganglia reduce the third ventricle, which lies between them, to the dimensions of a narrow slit. In the bony fishes the mid-brain grows to such a degree that it completely covers up and hides the inter-brain. The base of the inter-brain bulges out to form the infundibulum, which is a large process in the lower vertebrates, and which does not always become fused with the hypophysis, which grows toward it from the pharyngeal epithelium through the base of the skull. In many fishes, particularly the selacians, numerous blood-vessels grow into the infundibulum, and, pushing the epithelium before them, form the "saccus vasculosus,"—apparently a secreting organ. The roof of the inter-brain is formed anteriorly of the choroid plexus. Farther back it becomes elongated into a tube, which is directed forward,—the tube of the epiphysis. In some selacians, and in many reptiles, this passes through an opening in the skull to an organ of special sense, which strikingly resembles an eye. We can recognize a cornea and a lens, a retina

and a pigmentary layer lying in and under the latter, in this "parietal organ." We owe its discovery to Graaf and Spencer. In the other vertebrates we detect no relation between the epiphyseal tube and the organ of special sense in the adult animal. The tube has disappeared in the depths of the skull, and the parietal eye, as is shown by transitional forms in amphibians and reptiles, is so completely lost that no trace of it can be found in birds or mammals. The blunt, knotted end of the tube remains as a nodule, the "pineal gland," in front of the mid-brain. One of the thalamic ganglia, the ganglion habenulæ, demonstrable in all animals, is united with its fellow of the opposite side by a commissure. This commissura thalami dorsalis forms a part of the roof of the inter-brain in front of the epiphysis.

In all animals the optic tract, lying on the outside of the inter-brain, passes in a gradual descent from the mid-brain to the base of the brain. Between it and the inter-brain proper there is found, in fishes, amphibians, reptiles, birds, and mammals, another ganglion which lies more or less firmly imbedded in the mass of the thalamus (corpus geniculatum laterale). It is one of the points of origin of the optic nerve. The main point of origin of these nerves, however, is the roof of the mid-brain. This roof changes less in the different classes of animals than any other part of the brain. Only its relative size changes, and he who has only seen the small corpora quadrigemina of the human brain will be astounded when he sees the huge optic lobes of a fish or a bird; but the finer structure is always the same. From the dorsal layer of the hemispherical lobe, which is somewhat flattened by a sagittal furrow, the optic nerve always takes its origin. From the deeper layers arises a system of sensory fibres,—the deep marrow. The latter forms a network around the aqueduct of Sylvius, and the greater part of it passes caudad as the lemniscus, or fillet.

In the posterior part of the mid-brain roof there is in all animals a separate nucleus, fibres from which associate them-

selves with the deep marrow. This is the corpus quadrigeminum posticum. In mammals, in whom the anterior portion of the roof remains relatively small, this posterior quadrigeminal body reaches nearly the size of the anterior one. In all the figures it is marked by shading.

Not only in the bony fishes, but also in birds, the roof of the mid-brain has undergone special development. The simple hollow hemisphere grows outward and downward on both sides, so that the lengthened roof closes around the lateral portion. Inasmuch as this condition, peculiar to birds, would not be visible in a sagittal section, the mid-brain in Fig. 16 is not divided, but is left so as to show it as it appears in the uncut brain.

The base of the mid-brain is formed by masses of fibres which come from the fore- and inter- brain to pass farther back. To these masses are added the fibres springing from the roof of the mid-brain, and, lastly, there are found in this situation a number of nuclei from which bundles of fibres arise, which in part pass to the cerebellum, and in part reach the surface of the brain as peripheral nerves (oculomotor, trochlear). One condition, which is rudimentary in birds, is more developed in mammals. Many fibres from the cortex of the hemispheres are massed together and lie ventrad of the fibres at the base of the mid-brain. This mass, called the pes of the crus cerebri, or crusta, is very strongly developed in primates and in man. In such brains we call all that lies dorsad of it and beneath the roof of the mid-brain the tegmentum. Fishes, reptiles, and amphibians possess only the tegmental tracts; the fibres of the crusta are wanting, because in them no fibres pass downward from the cortex. The majority of the fasciculi of the crusta and tegmentum pass on to the base of the cerebellum and medulla oblongata, where many terminate. A part pass into the roof of the hind-brain.

This roof, which is continuous in front with the layer of the corpora quadrigemina, and behind, through the intervention

of a thin membrane (velum medullare posticum), passes into the posterior part of the spinal cord, contains the rudiments of the cerebellum. If you look at the sections shown in Figs. 12 to 17, it will strike you that with, perhaps, the exception of the fore-brain, no part of the brain shows so many changes in development as this. But the cerebellum is not, like the cerebrum, more developed in the higher classes of animals than in the lower. We find very remarkable differences in animals very nearly related to each other, and, on the other hand, in the lower selacians, for instance, an extremely good development of the organ. In the amphibians we meet with the cerebellum in its simplest form. The side of the roof of the hind-brain which faces the mid-brain is thickened into the form of a plate lying across the ventricle. Reptiles do not possess this organ in a very high state of development, but in those of them that swim (alligators) this plate is twice as thick as ordinary, and extends as far backward as the caudal side of the roof. Large swimming animals, the bony fishes and the selacians, possess a cerebellar organ which is so enormously developed that it must lie in huge transverse folds (Fig. 12), and even at times pushes itself forward under the roof of the mid-brain into the aqueduct of Sylvius (Fig. 13). Fishes living in mud (dipnoi) have a smaller cerebellum.

In fishes, amphibians, and reptiles, bundles of fibres pass from the inter- and mid- brain to the cerebellum, and from the spinal cord. We find these same bundles in birds and mammals, but in the former there are added very small, and in the latter very large, bundles of fibres from the fore-brain. These terminate in structures which we now meet for the first time, developing on each side of the middle portion of the cerebellum the hemispheres of the cerebellum. In birds these are still small, but in mammals they increase along with the development of the middle portion (from now on called the worm, vermis) until they far exceed the latter in size. The vermis, however, even in the human being, retains the transverse foldings which have

characterized the cerebellum in all classes above the selacians. Directly caudad of the cerebellum in the roof of the hind-brain we meet with ganglionic masses, which give off fibres to the trigeminal and the acoustic nerves. Fused closely with the cerebellum they are only small nuclei in mammals, but in fishes they form quite respectable lobes.

From the thalamic region to the end of the spinal cord the central cavity (ventricle, central canal) is surrounded with masses of gray substance, rich in ganglion-cells, and caudad of the mid-brain we find in this gray matter the peripheral nerves arising from their nuclei. In the gray substance of the floor of the hind- and after- brain arise a great portion of the fibres of the trigeminal and abducens, a part of the acoustic and of the vago-glosso-pharyngeal. Somewhat nearer the surface lies a column of nuclear cells, from the upper part of which the motor root of the fifth pair arises, and farther caudad the facial nerve. From the hind-brain to the sacral portion of the spinal cord there is an unbroken series of nuclei. There are really two series, one more ventral (zone of anterior horn, His) and the other more lateral (lateral zone). From the former arise the hypoglossal and all the anterior roots of the spinal nerves going to the muscles of the trunk. From the latter there arise (Gaskell) fibres which are concerned in the innervation of the muscular coat of the viscera. These lateral fibres leave the central organ along with the anterior-horn fibres, except in the region of the medulla, where they go to form the motor vagus and the accessory nerves. Farther down they leave the spinal cord in company with the other fibres of the anterior roots. According to Gaskell the latter pass into the mixed nerves, while the former are connected with the sympathetic.

In the ventral portion of the pons and oblongata there are situated many aggregations of ganglion-cells and nerve-fibres, whose relations, varying widely throughout the animal kingdom, cannot be discussed here. It is of importance that all the nerve-fibres which connect the brain with the centres situated below

pass through these parts. Through the presence of all these structures this portion of the brain is thicker than the spinal cord, which comes next to it. The latter forms a column from the segments of which there arise anteriorly the motor and posteriorly the sensory nerves. The space to the outside of the nuclei of the nerves is occupied by fibres which connect the spinal cord with the brain, and the different portions of the spinal cord with one another.

In the oblongata and spinal cord of certain animals we find peculiar structures, which have resulted from hypertrophy of some pre-existing organ. I will only mention, as examples, the great hypertrophy of the motor nucleus of the trigeminal in the ray,—the lobus electricus ; the enormous nucleus of the vagus of fishes, projecting high into the fourth ventricle, which, together with the trigeminal, provides for the sensation of the skin ; and the hypertrophy of the posterior horns of the spinal cord in certain fishes (Trigla).

LECTURE III.

THE GENERAL CONFORMATION AND HISTOLOGY OF THE BRAIN.

GENTLEMEN: Although these lectures are not addressed to beginners, but to those who have a general acquaintance with the coarser anatomy of the brain, it will not be entirely superfluous to review our knowledge and to form a clear image of brain-structure in our minds. The outlines of the map in which, later, we intend to mark out all the points and by-ways which are of importance, will be definitely fixed by a recapitulation of what has already been learned. Taught by embryology, you will easily understand the morphological conditions presented by the organ of the adult individual.

A fresh brain is laid on its base. You will easily discover the great fissure which separates the two hemispheres and the fissure of Sylvius which was originated by the growth of the temporal lobe. Inasmuch as the hemispheres have grown over most of the other portions of the brain (Fig. 5), we could get a view of the latter posteriorly by raising up the hemispheres and uncovering them. This could also be accomplished by removing a portion of the hemispheres. The latter method has the advantage of giving us a view of the lateral ventricles and the corpus striatum, and we will therefore follow it.

The knife held horizontally passes through both hemispheres at once and removes layers from 2 to 3 millimetres in thickness. The first and second of these layers contain much cortical matter and relatively little of the inclosed white substance; but in removing the third layer we have uncovered a large white field of medullary matter in the middle of each hemisphere, the centrum semiovale. In it run all those fibres which pass from the cortex downward, and a part of those fibres which connect the different portions of the cortex with one another.

On looking at Fig. 6, we should expect that on removing another layer we should find the hemispheres separated from the ventricle only by a thin layer of epithelium. This, however, is not the case. At a later period of embryonic development, thick masses of fibres have developed and pass from one hemisphere to the other at a point shown by the letter *a* in Fig 6.

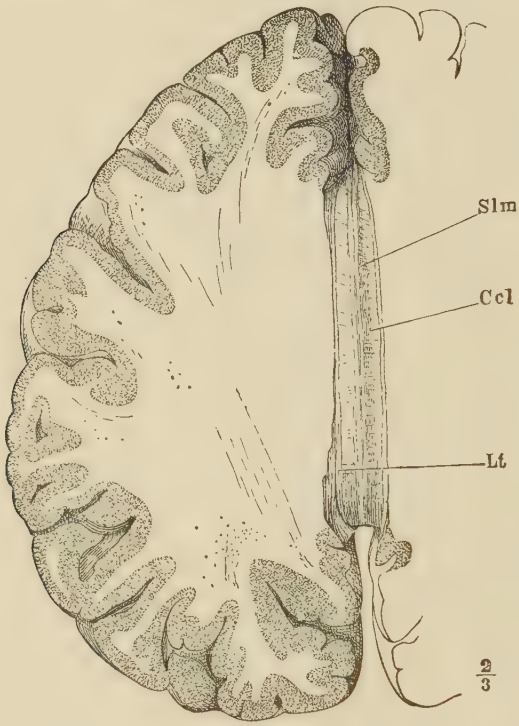

FIG. 18.

Fore-brain from above. The hemispheres have been removed at the level of the corpus callosum (*Ccl*). The white space between *Ccl* and the cortex is the centrum semiovale. *Lt*, ligamentum tectum or striæ longitudinales Lancisi, a part of the cortex which borders on the corpus callosum. *Slm*, striæ longitudinales mediales, white bundles of fibres which interlace on the middle of the corpus callosum. (After Henle.)

Thus, at the bottom of the great fissure we do not find the ventricle, but the corpus callosum, as the mass of transverse fibres is called.

The corpus callosum is now divided, and after the white substance which lies over the ventricles on each side has been removed it is cut off before and behind. Then it is seen that

its under surface is connected with some delicate masses of white fibres which, arching over the cavity of the ventricle, pass downward to the floor of the same before and behind. They belong to the fornix. After they and the adhering choroid plexus are divided and removed, we find ourselves looking into the cavity

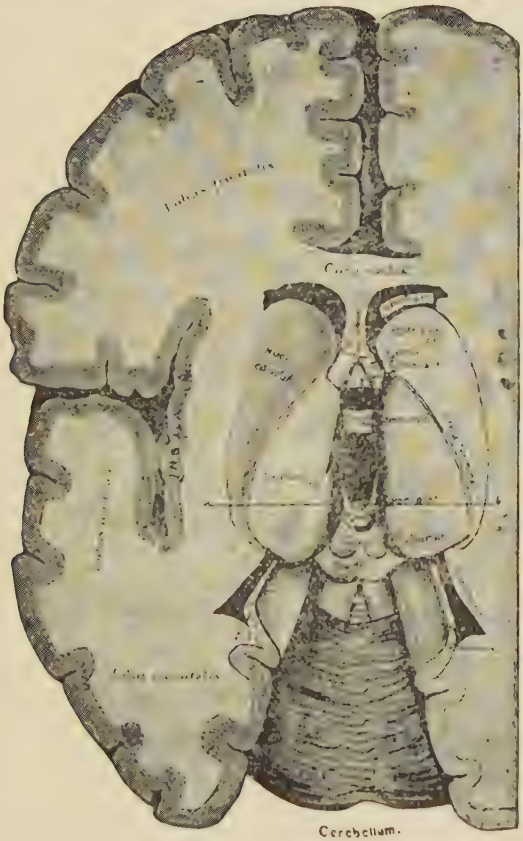

FIG. 19.
The brain opened by a horizontal section. Viewed from above. The two hemispheres are drawn somewhat apart.

Unterhorn, Inferior horn.

of the ventricle. The middle space is the cavity of the primary fore-brain, now called the third ventricle. From the depths of its anterior end ascends the margin of the secondary fore-brain, the fornix. It is directly continuous with the median wall. The latter is traversed by the fibres of the corpus callosum.

That part of the median hemisphere-wall which lies below the corpus callosum (it appears behind it in the cut) is called the septum pellucidum. That part of the original fissure between the hemispheres which remains between the right and left layers of the septum is called the ventriculus septi pellucidi. If you will imagine the corpus callosum removed from Fig. 19, the continuation of the hemisphere wall into the septum and the significance of the ventriculus will at once become apparent. It is no real ventricle, but only that portion of the fissure between the hemispheres which is covered in by the corpus callosum.

On each side of the fornix lies a passage from the third ventricle to the two lateral ventricles,—the foramen of Monro. That part of the lateral ventricle which lies in the frontal lobe is called the anterior horn, that which lies in the occipital lobe the posterior horn, and that lying in the temporal lobe the inferior horn. You can easily insert your finger into each of these horns. The basal regions of both hemispheres are connected with each other by the anterior commissure. You can see its bundles of white medullary fibres passing in front of the pillars of the fornix.

The nucleus caudatus emerges from the floor of the lateral ventricle. Farther back, however, parts come into view which no longer belong to the hemisphere,—the thalamus (inter-brain) and the corpora quadrigemina (mid-brain). Behind these appears the upper surface of the cerebellum (roof of the hind-brain).

Along the whole inner border of the hemispheres runs the thick mass of white fibres constituting the fornix. It arises from the boundaries between the hemispheres and the mid-brain on either side from the floor of the ventricle, and passes over the optic thalamus into the apex of the temporal lobe.

In removing the corpus callosum we removed also the middle portion of this arch of the fornix; so that we only see, anteriorly, close to the septum pellucidum, the ascending portion

of the arch (crura fornicis), and, posteriorly, the descending portion,—a white line of medullary matter, which, passing along the border of the hemisphere, bounds the temporal lobe on its inner aspect. If you connect the points *F.I* and *F.II*, in Fig. 19, with a gentle curve which passes over the optic thalamus, you will have restored the course of the fornix. In the accompanying median section of an embryonic brain you can easily distinguish the course of the fornix. In our dissection (Fig. 19) you can see the thalamus behind the nucleus caudatus. It belongs to the inter-brain, and has developed from its lateral walls. The space between the two thalami is the cavity of the former inter-brain vesicle. Of its roof only a thin layer remains, the most important part of which is the pineal gland. Fig. 4 shows how this arose by a process of protrusion. All the rest of the roof of the former vesicle is only present in the form of a thin epithelium, belonging to a plexus of vessels which cover the middle ventricle. The floor of the inter-brain, which is, of course, formed anteriorly of the embryonic terminal lamina, consists of a mass of gray matter, which is prolonged in a funnel-shaped manner toward the base of the skull. This projection is called the tuber cinereum, and its cavity the infundibulum. It is not shown in Fig. 19, but can be clearly seen in the median section (Fig. 17). At its extreme end the tuber cinereum is fused into the fold of pharyngeal mucous membrane which grows toward it, as shown in Fig. 4. At a later stage the latter is cut off from the pharynx and remains in the cavity of the skull, where, in connection with the tuber cinereum, it forms the hypophysis,—an

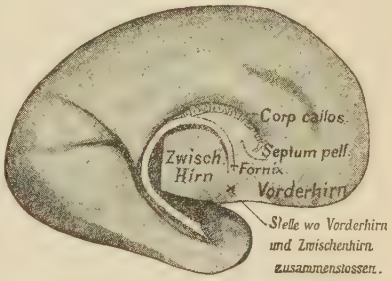

FIG. 20.

Inner aspect of the embryonic hemisphere, shown in Fig. 7. Shows the inner lower border of the hemisphere, which becomes thickened into the white medullary line of the fornix. The latter, however, only becomes medullary after birth.

Stelle wo Vorderhirn und Zwischenhirn zusammenstossen, Point where the fore-brain and mid-brain meet.

irregular, roundish, ball-shaped body, the size of a cherry, which is attached to the base of the inter-brain by a slender pedicle.

The thalamus is slightly separated from the nucleus caudatus by a bundle of fibres, called the stria terminalis. On the anterior portion of its surface the anterior tubercle is usually seen as a rounded swelling. It corresponds to a separate ganglion within. Still another ganglion belonging to the thalamus will be found if we follow up the white line which runs along the median ridge of the thalamus (stria medullaris). This ganglion is a small, club-shaped mass lying far back, just in front of the corpora quadrigemina, and is called the ganglion habenulæ. From this there arises on each side a thin, white bundle of fibres which passes to the pineal gland,—the pedunculus conarii. The gray mass of the thalamus is overlaid with white fibres (stratum zonale), which, in part, pass to the optic nerve. A principal point of origin for this nerve is a protuberance on the posterior part of the thalamus,—the pulvinar. Macroscopic observation alone would place the source of the optic nerve in this ganglion and in two nodules on its under side (corpus geniculatum mediale and laterale). Between the thalami there extends a thin, gray lamina,—the middle commissure. I have never failed to find it if the brain was carefully taken out.

The nerve-tracts from the hemispheres which lie deep down between them and the thalamus emerge, for the most part, caudad of the thalamus from the main mass of the cerebrum. They form thick strands, and lie exposed on the ventral surface of the mid-brain,—the corpora quadrigemina; taken together, they are called the crura of the brain (pedunculi cerebri).

Behind the pineal gland begins the roof of the mid-brain. We regard the posterior commissure as the most anterior portion of this roof, as, arising in the thalamus, it passes caudad through the mid-brain. The corpora quadrigemina, which appear just behind this commissure, we shall examine later on.

If the brain is opened from above, as we have done, only the inner portion of the corpus striatum—the nucleus caudatus—

can be seen. The outer portion—the lenticular nucleus—lies deeper, and is covered with medullary masses, which pass over it into the internal capsule. We could expose it by opening downward outside of the nucleus caudatus, but you will get a better idea of its form if a frontal section is made transversely through the whole brain at the point in Fig. 19 where the thala-

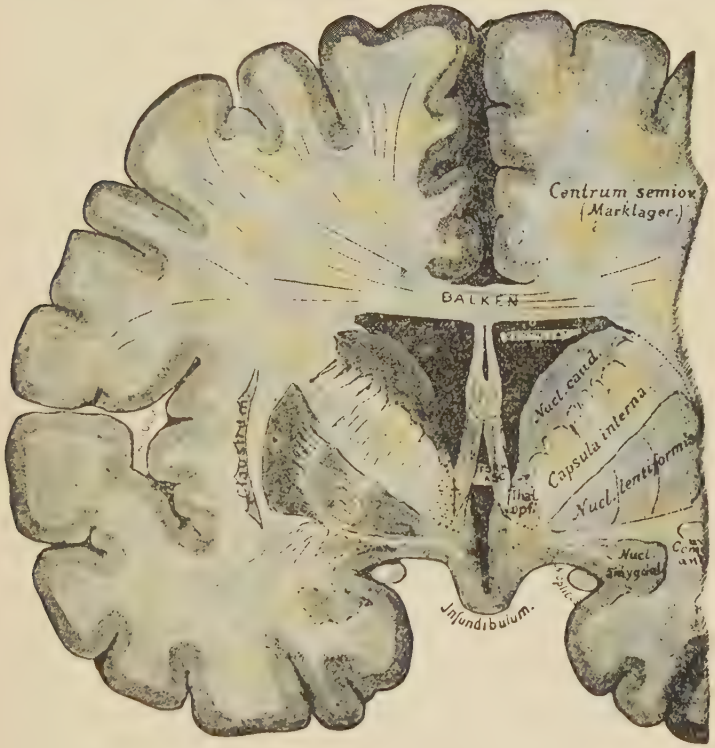

FIG. 21.
Frontal section through the adult brain. Explanation in the text.
Balken, Corpus callosum. *Marklager*, White substance.

mus begins, just behind the thickest part (caput) of the nucleus caudatus; that is to say, just behind the ascending pillars of the fornix.

It is not difficult to understand the cross-section (Fig. 21) if we keep in mind the conditions shown in Fig. 6. The brain-wall is decidedly thicker than at the fœtal period, but the corpus

striatum rises from the floor just as shown in that section. The outer fissure has now disappeared, but it may be considered as occupying the situation shown by the dotted line on the right side.

At the bottom of the great fissure you can see the ventricle covered by the thick cross-fibres of the corpus callosum. To these there pass from below the two pillars of the fornix, leaving the ventriculus septi pellucidi free between the thin layers of the septum pellucidum. They project freely into a cavity, the lateral ventricle. This cavity is bounded exteriorly by the corpus striatum. Just here you can see beautifully how the corpus striatum is penetrated by and apparently divided into two ganglia by the thick masses of fibres of the internal capsule. In the lenticular nucleus, that is, in the outer portion of the corpus striatum, you can easily distinguish three divisions. Only one of these three parts—the external, shown most deeply shaded, called the putamen—may be regarded as a source of origin of fibres, together with the nucleus caudatus. The function of the two internal divisions (globus pallidus) is still uncertain. The globus pallidus sometimes consists of three or more divisions. External to the lenticular nucleus there lies a thin, gray mass in the wall of the hemisphere,—the claustrum. The space between it and the lenticular nucleus is called the external capsule. Farther out still lies the cortex of the island of Reil. The gray mass on the floor of the middle ventricle belongs to the wall of the infundibulum,—the tuber cinereum. It and its continuation are called the central (ventricular) gray substance. At the point where this and the cortex of the temporal lobe become continuous there lies a large, roundish nucleus, —the nucleus amygdalæ. It probably stands in some relation to the origin of the olfactory nerve. In its finer structure it resembles the claustrum (Mendinol). Between the pillars of the fornix you see the anterior commissure. Its fibres curve backward as they pass through the corpus striatum. For this reason we again meet them on cross-sections of the brain, just below

the outer part of the lenticular nucleus (Fig. 21, below and to the right).

I cannot urge you too strongly, gentlemen, to look up in the fresh brain all the parts mentioned in to-day's lecture, and learn the situation of each by your own dissection. The representation by word and picture may give you a good idea of them, but it can never take the place of that which may be obtained by study of the fresh specimen.

The difference in colors which you have observed to-day in the fresh brain specimens is caused by differences in their finer structure. To this, the histology of the central nervous system, we will now, for a short time, turn our attention.

FIG. 22.
Isolated neuroglia-cells.

The brain is made up of nerve-tissue and a matrix. This matrix is composed of the walls of numerous blood-vessels which pass in every direction through the organ, and of the neuroglia, most delicate cells, with a net-work of fine ciliary processes, which, becoming intermingled with those of neighboring cells, are matted together into a sort of dense felt. This structure may well be likened to a mass of burrs stuck together with a few thicker strands, the blood-vessels, passing among them. The nerve-fibres are imbedded in the free spaces between the cells of the neuroglia.

The net-work of neuroglia is somewhat differently constituted in different parts of the central nervous system, and forms here and there thick masses, altogether free from nerve-substance.

Thus, for instance, a broad zone of almost unmixed neuroglia is spread over the whole surface of the brain and spinal cord. The larger ganglion-cells are often so entangled in neuroglia that they seem to be lying in a fine-meshed basket.

The nerve-substance proper which fills out the spaces in the above-described net-work consists of ganglion-cells and nerve-fibres.

The form of the ganglion-cells is extremely varied. Roundish, almost spherical bodies of small size are seen, together with multipolar cells with many processes, and twenty times the size of the smaller cells.

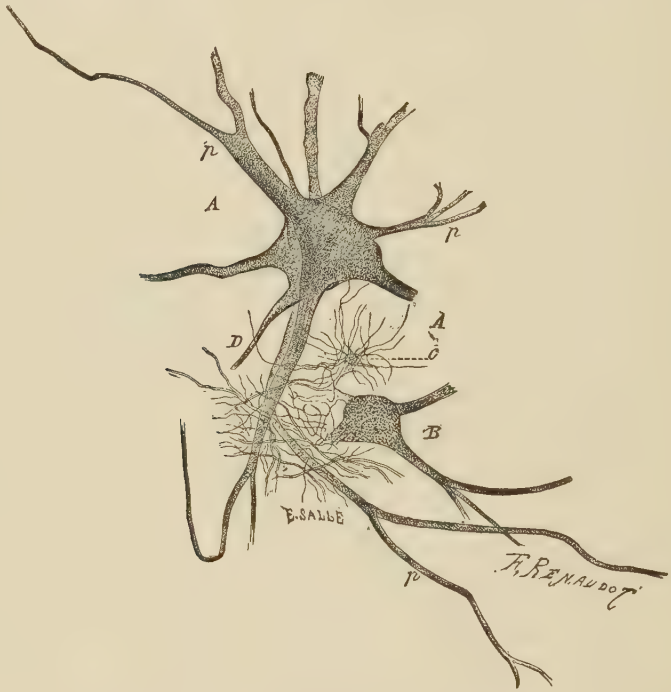

FIG. 23.
From a piece of spinal cord. *A* and *B*, ganglion-cells; at *D*, axis-cylinder; *p*, protoplasmic process; *c*, neuroglia-cells. (After Ranvier.)

In the lobus nervi vagi of the torpedo and in the medulla oblongata of the river lamprey are found such enormous ganglion-cells that they can readily be seen with the naked eye. In the spinal cord of the electric eel, the malaterus, are two isolated ganglion-cells of such a size that the huge single nerve-fibre which each gives off is sufficient to supply the very large electric organ of the animal.

The nerve-fibres arise from the ganglion-cells. R. Wagner first showed that but a single process of these cells could be traced directly into the nerve, and other investigators have confirmed this. The relations which the other processes of a multipolar cell and the processes of the cells which do not possess this "axis-cylinder" process have to the nerve-fibres remained in darkness until Gerlach, in 1870, showed that these processes form a net-work with each other, and that from this net-work nerves arise. It is only during the course of the past year that Bellonci first, and later, in a still more convincing manner, Golgi and Bela Haller succeeded in showing the method of origin of nerve-fibres from the central ganglionic cells. Golgi conducted his investigations on the cortex of human beings and of other animals, and, by frequent combinations of very complicated microscopical pictures, arrived at the same conclusions with Haller, who worked on mollusks, where the conditions were more simple, and the relations could be plainly seen. The most important of these discoveries, which, moreover, have been confirmed for other parts of the central nervous system by Golgi's pupils, is the now well-established fact that the nerve-fibres arise from the cells of the central nervous system in two ways; that there is a direct and an indirect origin of nerves.

FIG. 24.
From a section through the pleuro-cerebral ganglion of the fissurella. 1, net-work of nerves; 2, ganglion-cells; 3, nerve-fibres. (After Henle.)

The former we have already mentioned as having been discovered by Wagner. The axis-cylinder process of a ganglion-cell

passes directly into a nerve-fibre. Recent investigations have shown that before passing off it gives rise to minute fibrils, which form a fine net-work. This direct form of nerve-origin has been recognized in the great pyramidal cells of the cortex, and in the cells of Purkinje in the cerebellum, in the nuclei of the motor nerves in the brain and spinal cord, and in other places.

In many other cells, however, the processes, soon after leaving the cells, break up to form a fine net-work, which receives, also, the lateral fibrils of the axis-cylinder processes before mentioned, and from this net-work the nerve takes its origin. This net-work may contain the offshoots of a great number of ganglion-cells. In the accompanying section through the pleural ganglion of a snail you may see both methods of nerve-origin taking place side by side (Fig. 24).

What part is played by the cell processes which do not become connected with the nervous system—Golgi calls them protoplasmic processes—is not yet determined. There is ground for believing that they are connected with the fine net-work composed partly of glia and partly of connective tissue, which surrounds the blood- and lymph- vessels of the central nervous system; that is, that they bear some relation to the nutrition of the cells themselves. The fact that this fine net-work, which consists of all these processes of ganglion- and glia- cells, is so difficult to disentangle has naturally led to other views as to its composition than the one I have given you, but it is important to notice that all the later authors, whatever their differences of opinion in regard to the net-work (Leydig, Nassen), have observed the double method of origin of nerve-fibres.

It is probable that the difference in origin denotes a difference in function. We know that the motor roots of a peripheral nerve arise directly from the axis-cylinder of the cells, and it was in the sensory posterior roots that Gerlach observed the breaking up of the nerves into this minute net-work. The investigations of His, to which I referred in the last lecture, bear out the views we have adopted.

The nerve-fibres in the brain and spinal cord are of varying size in adult mammals, and all are probably surrounded with medullary sheaths.

Every nerve-fibre, as it enters the central organ, loses its sheath of Schwann. Only a thin layer, first seen by Ranvier, and which is present even in peripheral nerves, is left to cover the nerve-marrow after it enters the brain or spinal cord.

In general, the parts which consist only of medullary fibres appear white (white substance); those composed mainly of

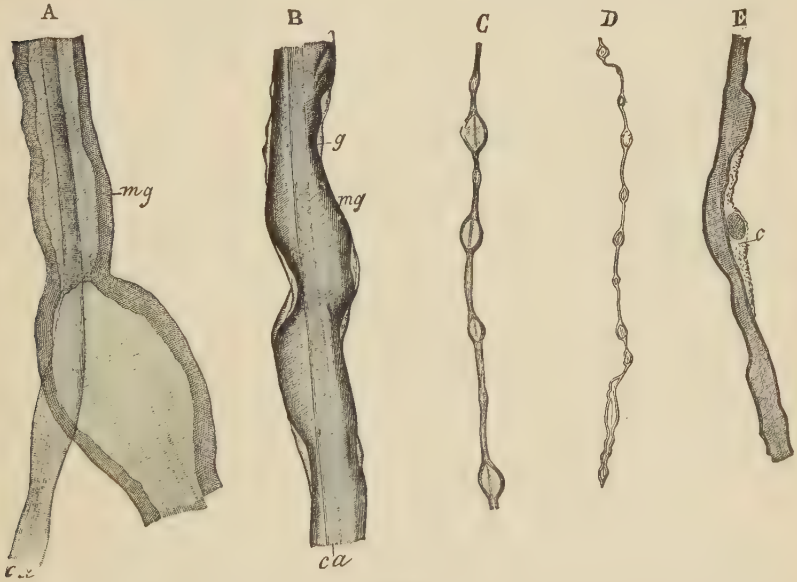

FIG. 25.

Different nerve-fibres isolated from the spinal cord of a dog. *ca*, axis-cylinder; *mg*, medullary sheath; *g*, peripheral membrane; *c*, nucleus and protoplasm to be seen on the surface of a few fibres. (After Ranvier.)

neuroglia, axis-cylinder, and ganglion-cells, gray (gray matter). The gray matter is more vascular than the white. During life it exhibits, in the presence of sensitive reagents, a slightly acid reaction.

We owe our first accurate knowledge of the histology of the central nervous system, as was stated in the first lecture, to Ehrenberg, Remak, and Hannover. After Hannover, Helmholz, in 1842, recognized in invertebrates the true relations between ganglion-cells and nerve-fibres. In 1844, Kölliker discovered that a double-contoured nerve might arise from a cell. In 1850 Rudolph Wagner dis-

covered, in working on the electric organ of the torpedo, that a single ganglion-cell may send out two sorts of processes, of which only one, the axis-cylinder process, is continued into a nerve; and in 1854 Remak observed the same thing in the great ganglion-cells of the spinal cord. Deiters, in 1865, proved that this was true of all ganglion-cells. Our knowledge of these conditions has been increased by the labors of Gerlach, Max Schultze, Waldeyer, Jolly, A. Key and G. Retzius, Betz, Bevan Lewis, Obersteiner, Freud, and many others. So many have turned their attention and efforts to this most difficult region of histology that a memoir which appeared at the beginning of 1887 (Napsen) enumerated 341 works on nerve-fibres and ganglion-cells. More recent and profound works on the neuroglia are those of Boll, Ranvier, and Gierke.

LECTURE IV.

THE CONVOLUTIONS AND FISSURES OF THE SURFACE OF THE CEREBRUM.

GENTLEMEN: It is not so very long ago that the study of the structure of the brain surface possessed very little interest for the anatomist and none at all for the practicing physician. Nor is it a very long time since order was brought out of the seeming chaos of the convolutions of the brain, so that clear and definite cuts have taken the place of the old plates, concerning which an author pertinently remarked that they were a better representation of a dish of macaroni than of the brain. Interest was first awakened in regard to the human brain after physiology and pathology had shown the different results of irritation, extirpation, and disease, varying according to the different convolutions attacked. It is, therefore, of importance, gentlemen, that you learn to know thoroughly the arrangement of these convolutions and the course of the fissures which separate them. By word and diagram alone it will be impossible for me to make you as thoroughly acquainted with these structures as you should be. Here again it is necessary for you to take a fresh brain, and, following my lecture, trace out for yourselves sulcus after sulcus and convolution after convolution.

FIG. 26.
Brain of human embryo of 13 weeks.

The primarily lens-shaped hemispheres grow, as you know, toward the front and backward. Only in the middle, at a point corresponding to the corpus striatum within, the surface does not expand as rapidly, and, hence, becomes more depressed than the surrounding parts. The depression which thus exists near the point of origin of the hemispheres is called the fossa or fissure of Sylvius, and that part which lies in the depression the

island of Reil. The island is, therefore, that part of the cortex which immediately adjoins the ganglia of the cerebrum. At first it lies on the surface, but little by little it is covered in by the overlapping hemispheres.

You will easily find the fissure of Sylvius in the adult brain. It is the largest of the sulci, and on separating its walls you will discover the island, and see that it is traversed by a number of perpendicular and oblique sulci. In the sixth month

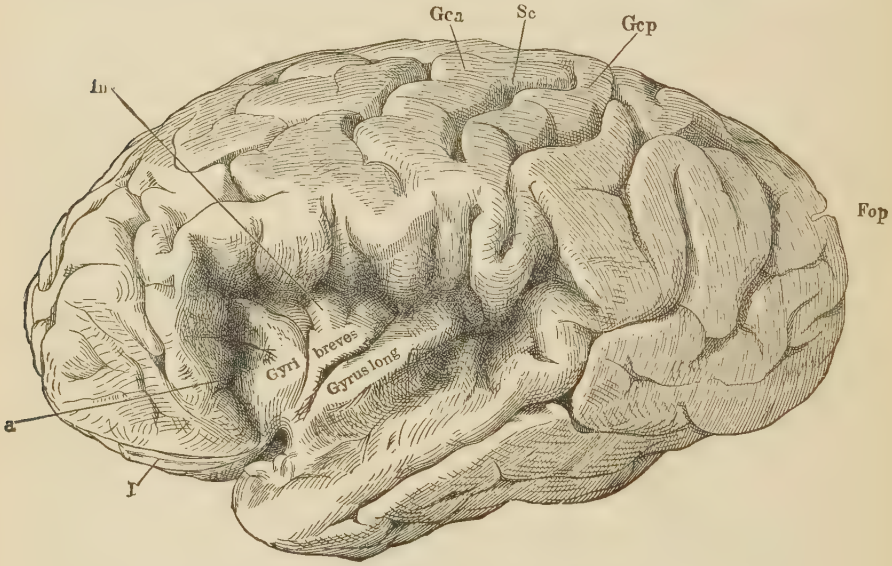

FIG. 27.

The left hemisphere with the fissure of Sylvius drawn apart in order to show the convolutions in the island of Reil (*In*). *Sc*, sulcus centralis; *Gca*, *Gcp*, gyrus centralis, anterior and posterior; *Fop*, fissura parieto-occipitalis. (After Henle.)

of pregnancy the two divisions of the fissure of Sylvius—the anterior and posterior—are plainly to be seen. All the rest of the brain is still smooth. (Compare Fig. 7.)

After this period, furrows (sulci or fissures) are developed on the surface of the hemispheres by means of local elevations which increase more and more during the later months of fœtal life until birth, at which time almost all the fissures and convolutions which the adult brain will possess are clearly marked out.

The following purely diagrammatic drawings may serve as

a guide in your study of the surface of the brain. Only the most important constant convolutions and fissures are therein considered. The simple diagram of Ecker, of which they are reproductions, impresses itself more easily on the memory than a representation of a real brain which shows all the shallower fissures, which are inconstant, alongside the deeper and more constant ones.

First, let us look up the fissure of Sylvius; it divides the

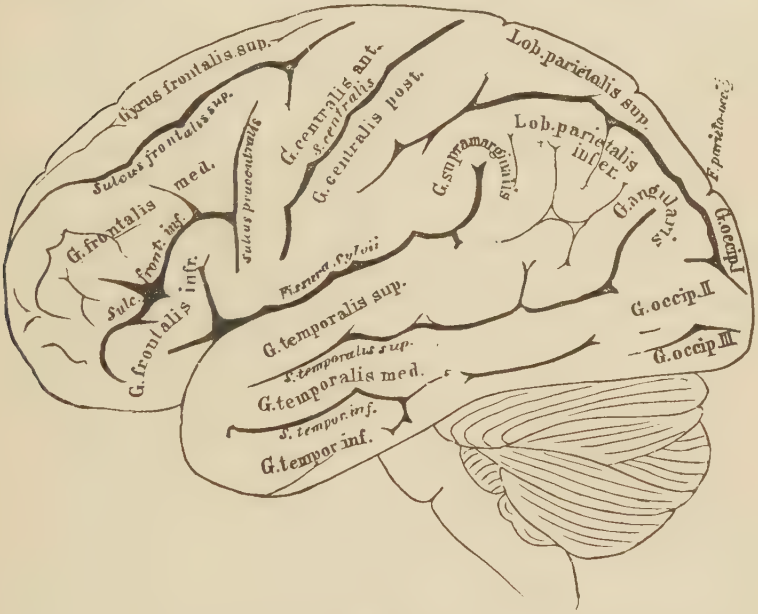

FIG. 28.

Lateral view of the brain. The convolutions and lobes are marked in Roman letters, the fissures and sulci in italics. (After Ecker.)

greater part of the temporal lobe from the rest of the brain. We can observe two branches—a long anterior and a short posterior and ascending branch. The mass of brain which lies at their junction and covers the island is called the operculum. If we separate those portions of the brain which surround the fissure of Sylvius, as is done in Fig. 27, the island lies in full view. We see that it is traversed by a deep fissure, passing obliquely upward and backward,—the sulcus centralis insulæ,—which

divides it into two lobules. The anterior lobule is divided by several perpendicular fissures into 3–4 gyri breves insulæ. The posterior lobule is, apparently, one single longer convolution,—the gyrus longus. It borders directly on the temporal lobe. In the operculum there begins an important fissure which ascends to the margin of the hemisphere, but is separated from the latter, as well as from the fissure of Sylvius, by brain-substance. This is the sulcus centralis, or central fissure. Observe it in Fig. 28; it divides the frontal from the parietal lobe. All that lies below the fissure of Sylvius is called the temporal lobe. In front of the central fissure lies the anterior central convolution; behind it, the posterior central convolution.*

The region in front of the anterior central convolution, the frontal lobe, is divided by two fissures, the superior and inferior frontal fissures, into three convolutions,—superior, middle, and inferior frontal convolutions. These are not always sharply defined along the whole length of the frontal lobe, inasmuch as the frontal fissures are often interrupted in their course by *plis de passage*. You will easily discover these three divisions of the frontal lobe lying next to each other in all brains, and will observe that the lower frontal convolution (also called third frontal convolution) takes part in forming the operculum. Very often there is found at the posterior end of the inferior frontal fissure another fissure at right angles to it, which bounds the anterior central convolution in front and is called the præ-central fissure.

[The lower frontal convolution is broader in Europeans than in other races. In the brain of Gambetta, who was a great orator, it was twice as broad as usual.]

The temporal lobe is traversed by several fissures, which run parallel to the fissure of Sylvius and divide the lobe more or less sharply into an upper (or first), a middle (or second), and a lower (or third) temporal convolution. Generally only the two first of these are clearly distinguishable throughout their whole length.

* Circonvolution frontale ascendente, } of the French writers.
Circonvolution pariétale ascendente, }

Observe now the region caudad of the central fissure and above the temporal lobe. It is called the parietal lobe. It is divided into a superior and an inferior parietal lobe by a sulcus, which passes in a curve around the end of the fissure of Sylvius and the end of the first temporal fissure, and is called the interparietal fissure. There is nothing to mark the division between the superior parietal lobe and the posterior central convolution, unless, as often happens, a branch of the interparietal fissure

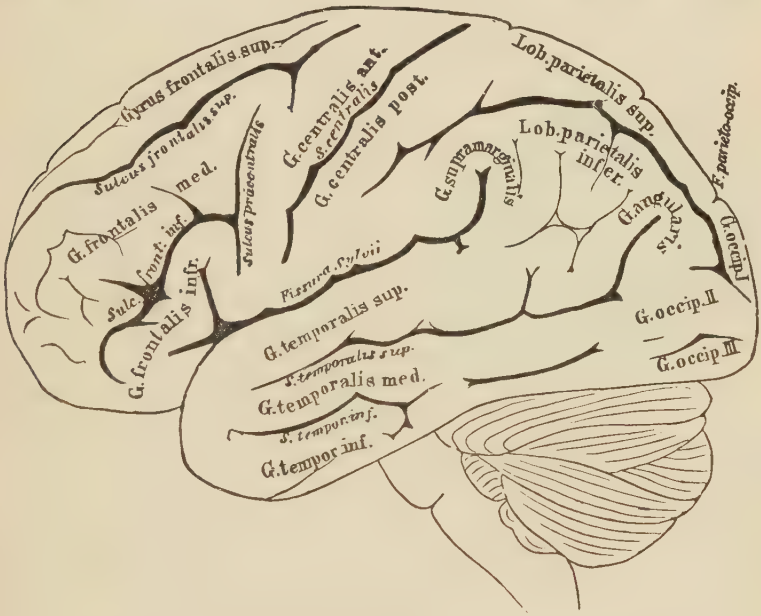

FIG. 29.
Lateral view of the brain. For explanation, see Fig. 28. (After Ecker.)

passes upward toward the margin of the hemisphere. In this case, of course, the connecting convolution is much narrower.

That part of the inferior parietal lobe which surrounds the fissure of Sylvius is called the gyrus marginalis.*

The part lying just back of this, and arching around the end of the superior temporal fissure is called the gyrus angularis. The former you will discover at once in every brain; the

* Marked "G. supra-marginalis" in the cut (Fig. 28).

latter you will have to be at some pains to distinguish. You will find it in the space which is bounded above by the interparietal fissure and below by the superior temporal fissure, its posterior portion, indeed, surrounding the end of the latter.

Do not always expect, gentlemen, to find the interparietal fissure running its whole course without a break. Often enough it is broken into two or more parts by *plis de passage*, which are usually found in its posterior third. Its posterior portion extends into the occipital lobe.

This occipital lobe is not in all brains so uniformly divided by its sulci that we can always find the three convolutions described by writers, viz., first (upper), second (middle), and third (lower) occipital convolutions, easily and without artificial refinement.

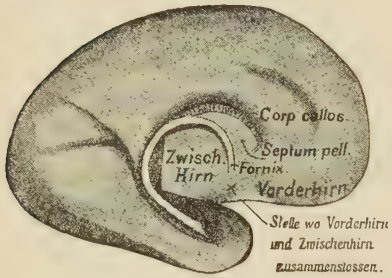

FIG. 30.

Inner aspect of the embryonic hemisphere, shown in Fig. 7. Shows the inner lower border of the hemisphere, which becomes thickened into the white medullary line of the fornix. The latter, however, only becomes medullary after birth.

Stelle wo Vorderhirn und Zwischenhirn zusammenstossen, Point where the fore-brain and mid-brain meet.

It is often separated from the parietal lobe by an additional occipital fissure (not shown in the figure), which passes up perpendicularly behind the gyrus angularis. The line of division from the temporal lobe is a horizontal fissure, appearing like a continuation of the inferior temporal fissure, and called the inferior occipital sulcus. The angle between these occasionally continuous fissures bounds the temporal lobe. At the upper and anterior part it is continuous with the parietal lobe. This connection is divided into the bridging convolutions by the interparietal fissure, which passes through it longitudinally.

After noting all these convolutions and fissures, divide the brain into halves by cutting down through the great fissure and study the median surface.

The most important parts of the median hemisphere-wall have been described in the preceding lecture, while we were studying its development. I will only remind you that we then learned that the margin of the hemisphere thickened into the fornix, followed the growing hemisphere in a curve; that forward, where the corpus callosum passes through, that portion of the inner wall which lies between the latter and the fornix, remains as the septum pellucidum.

Taught thus by the history of its development, you will

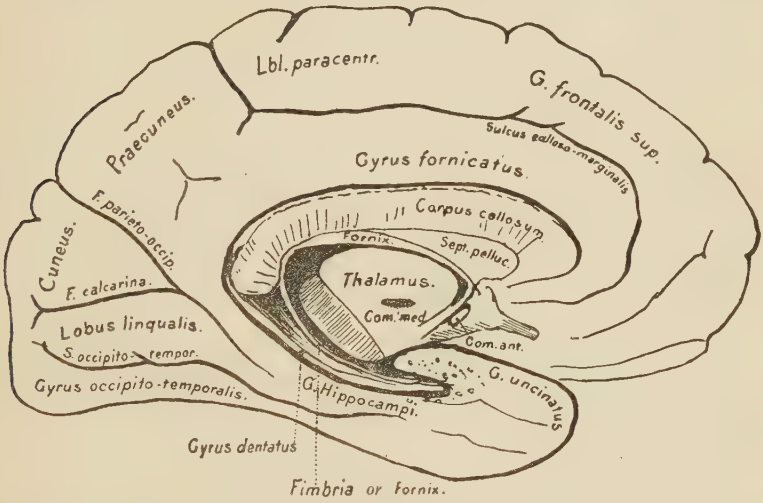

FIG. 31.

Sagittal section through the middle of an adult brain. The posterior portion of the thalamus, the pedunculus cerebri, etc., have been removed in order to show the inner surface of the temporal lobe.

understand the sections made through the adult brain. In the specimen from which Fig. 31 is taken, as well as in the embryonal brain (Fig. 30), all parts lying caudad of the middle of the thalamus are cut off, because they cover the under side of the temporal lobe and prevent us from following up the course of the fornix.

Now, on the longitudinal section, you see in the centre the inter-brain, or, rather, the thalamus, which has developed from its lateral wall. Along the boundary between it and the cerebrum lies the curved margin of the hemisphere, thickened to a

white band of medullary substance,—the fornix. Near the junction of the thalamus and mid-brain it rises close to the base of the brain, passes dorsad as the pillars of the fornix, accompanies the margin of the hemisphere still farther, curves around it into the temporal lobe, and ends in the apex of the latter.

The horizontal mass of transversely divided fibres above it belongs to the corpus callosum. In its anterior part you will distinguish the knee, in its posterior part the splenium, and be-

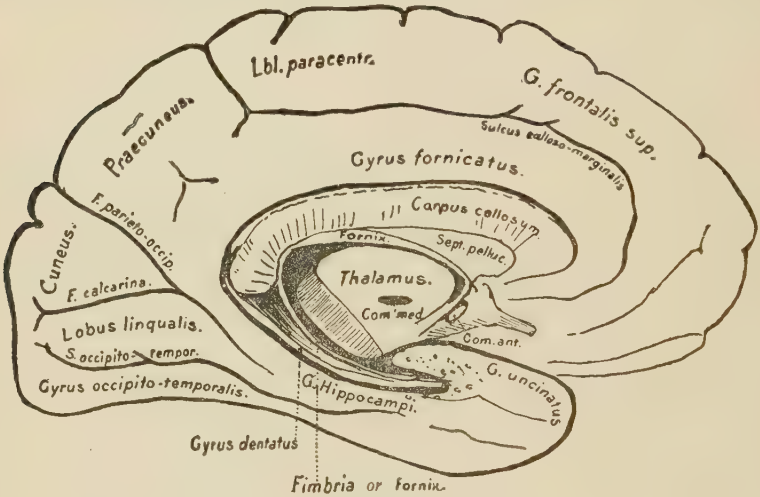

FIG. 32.

For explanation, see Fig. 31.

tween the two the body. Between the fornix and the corpus callosum lies the triangular field of the septum. Besides this, you can see, just in front of and below the fornix, the anterior commissure, and in the middle the commissura media,—both, of course, in cross-section.

That portion of the hemisphere-wall which lies above the corpus callosum is traversed by few and rather constant fissures. First, parallel with the corpus callosum, is the sulcus calloso-marginalis. Behind, it turns upward to the crest of the hemisphere and terminates in a little indentation behind the posterior

central convolution. That part lying in front of and above this fissure is considered as belonging to the superior frontal convolution. The convolution between it and the corpus callosum is called the gyrus fornicatus. A glance at a specimen, or at our cut, shows that the gyrus fornicatus becomes widened posteriorly, and passes up over the crest of the hemisphere to become continuous with the superior parietal lobe. This widened portion is called the præcuneus. Directly in front of the præcuneus lies a region of the cortex which, exteriorly, is continuous with both central convolutions and connects them. It is called the paracentral lobule. Posteriorly, the præcuneus is bounded by a deep fissure, which usually passes over somewhat to the exterior surface of the hemisphere. It is called the parieto-occipital fissure. This parieto-occipital fissure sometimes passes beyond the inner surface of the brain, and runs out over the outer surface as a deep perpendicular fissure. This is especially apt to occur in the brains of idiots.

The fissura calcarina joins the parieto-occipital sulcus at an acute angle. This fissure lies exactly in the wall of the posterior horn of the lateral ventricle, which has been mentioned before. The brain-wall, displaced inward by it, can be seen as an elongated swelling in the posterior horn. This swelling is known as the calcar avis or pes hippocampi minor. The triangular portion of cortex inclosed between the fissures last described is known as the cuneus. Examine the point of this region and, superficially or deeply, you will find a little convolution connecting it with the gyrus fornicatus, which passes by in front of the wedge-shaped cuneus. Notice this comparatively narrow part of the gyrus fornicatus. You see that it passes on as a rapidly-broadening convolution to the apex of the temporal lobe, where it ends in a hook-shaped process,—the uncus or gyrus uncinatus. This part of the gyrus fornicatus lying in the temporal lobe is called the gyrus hippocampi. Posteriorly (as you see in the cut), a small, longish convolution of the occipital lobe joins the gyrus hippocampi. It is called the lobus lingualis.

As I showed you before, the fornix forms the margin of the hemispheres. The first convolution outside of this margin —a convolution, therefore, which lies close to the fornix—is the gyrus hippocampi just mentioned. To the other side of it lies the cavity of the ventricle,—the inferior horn. At this point the ventricle is separated from the general cavity of the skull by a thin membrane, bearing the continuation of the choroid plexus, which is attached to the fornix throughout its entire course.

The gyrus hippocampi may be regarded as the marginal convolution of the hemisphere. This margin, a long, thin, white stripe, is directly continuous with the fornix above. It is called the fimbria (Fig. 19, *F.I*).

The gyrus hippocampi is pushed out into the cavity of the inferior horn by a fissure on its outer surface,—the fissura hippocampi. The swelling which is thus produced and which extends along the whole floor of the inferior horn has for ages been called the cornu ammonis, or pes hippocampi major.

From the fact that the cortex of the gyrus hippocampi is doubled in by the fissura hippocampi before it ceases and leaves the medullary matter bare, a peculiar and complicated appearance is presented on cross-section. Over the general surface of the brain the gray matter is continuous, as shown in Fig. 33 A; but on the gyrus hippocampi it ceases close to the ventricle, as shown in Fig. 33 B, and leaves the white, somewhat curved edge (the fimbria) free. The bending or doubling in which it undergoes before it ceases is shown in Fig. 33 B. Between the gyrus hippocampi and the free medullary margin of the hemisphere (fimbria—fornix) there lies a small convolution (purposely not mentioned before), which passes from the end of the corpus callosum to the apex of the temporal lobe, and therefore takes part in the configuration of the cornu ammonis. You will please look up this convolution in the sagittal section (Fig. 32) in order to make clear its situation in relation to the fornix and the cornu ammonis. It is called the gyrus dentatus, or

fascia dentata. As you see, it lies just in front of the involution of the cortex of the gyrus hippocampi, by the fissure of the same name, and its cross-section, therefore, is not correctly represented by Fig. 33 B, but rather by Fig. 34.

The cornu ammonis is, therefore, the bulging in the floor of the ventricle, which is caused by the pushing in of the gyrus hippocampi by the fissure of the same name. From the cessation of the cortex just at this point, from the fact that the margin of the hemisphere (fimbria and gyrus dentatus) runs along over this involution, arises the complicated cross-section of the cornu ammonis.

FIG. 33 A.

FIG. 33 B.



FIG. 34.

Unter, Inferior.

The relation of the gyrus hippocampi to the inferior horn of the lateral ventricle is made clear by Figs. 19, 32, and 38.

The gyrus fornicatus and its continuation, the gyrus hippocampi, are developed early in fœtal life. Dorsad of the margin of the hemisphere (arch of the fornix), there is developed in all mammals a furrow which lies parallel with the fornix and accompanies it into the temporal lobe,—the fissura hippocampi. The convolution between it and the fornix is the gyrus hippocampi. Anteriorly, the fibres of the corpus callosum pass transversely through it, and in this region it is called the gyrus fornicatus. Farther back, however, it is called the gyrus hippocampi, and lies next to the fornix. In the lower animals the

corpus callosum and the gyrus fornicatus are very short. Only in men and apes is the corpus callosum so long that the beginning of the gyrus hippocampi lies in the temporal lobe. If you will look at the upper surface of the corpus callosum, you will see on each side of it a thin, gray, longitudinal line (Fig. 18, *Lt*). It is the continuation of the atrophic convolution met in the pes hippocampi major,—the gyrus dentatus. We call it the stria longitudinalis Lancisi.

All the convolutions which lie near the margin of the hemisphere—the gyrus fornicatus, the gyrus hippocampi, the stria longitudinalis Lancisi, and the fascia dentata—are very strongly developed in animals having highly perfected organs of smell. In those which, like human beings, have small olfactory lobes, they are somewhat atrophied, and in the dolphin, which has no olfactory lobe, they are totally undeveloped (Zuckerkandl). At the posterior end of the corpus callosum we sometimes see a short convolution which passes in the direction of the fornix and becomes incorporated with it; it is the gyrus callosus, which is only present in man as a very atrophic, imperfect, and inconstant structure.

On a fresh brain you may see the gyrus unciatus at the apex of the temporal lobe, and from there follow the gyrus hippocampi upward. Then observe the prominent arch of the fornix as it passes over the posterior part of the thalamus, and note how it ends in the fimbria, which is visible nearly to the end of the gyrus hippocampi as a white medullary line. Lastly, make a cross-section, which may explain the relations of the foregoing structures.

On the base of the brain, with the exception of the hippocampal fissure, which really belongs to the median surface, there are few sulci of importance. On the under surface of the frontal lobe are the orbital and the olfactory fissures. The convolutions between them are regarded as continuations of the frontal convolutions, and receive the names of the frontal convolutions with which they are respectively continuous. The under surface of

the occipital and temporal lobes is fissured mainly in an antero-posterior direction. A third and fourth temporal sulcus is often found. The latter, which extends over into the temporal lobe, is called the occipito-temporal fissure. It separates the gyrus hippocampi from the convolutions of the temporal lobe. The temporal convolution lying just outside of this fissure (fourth temporal convolution) has received the name of gyrus occipito-temporalis.

Our knowledge of the course of the convolutions comes from Burdach (median surface), Leuret, Gratiolet, Meynert (comparative anatomy), Bischoff, Ecker, Pansch (growing and adult brain). Besides these there are numerous investigators as to separate localities, e.g., *Broca and Zuckerkandl on the convolutions near the margin of the brain, Eberstaller and Guldberg on the island, and Rüdinger on the interparietal fissure. Again, we possess a considerable number of monographs on the surface of the brain of many mammals. (Anthropomorphous apes, by Bischoff; lemurs, by Flower and by Gervais; whales, by Guldberg; ungulates, by Krueg; carnivorous animals, by Meynert and Pansch, and many others.) The numerous variations in the course of the individual convolutions and fissures which may occur in man are not only mentioned by a majority of the above writers, but have found an investigator of their own in D. Sernow.*

It does not lie within the scope of these lectures, gentlemen, to impart the rich store of facts which physiology has brought to light respecting the various cerebral structures. Our knowledge of the functions of the cortex is, as yet, in its infancy, and is in no respect complete. I must refer you to the text-books of physiology, in many of which you will find excellent chapters on the subject. In general, it may be said that, so far as the phenomena which follow an injury to the cortex are concerned, more is positively known about human beings than about animals. The following is a short summary of these symptoms:—

Injuries which involve the normal structure and function of the cortex give rise in the human being to symptoms differing according to the part injured. Up to the present time there have been several hundred carefully observed cases of disease of the cortex, and by comparing them with one another we can arrive at the following conclusions:—

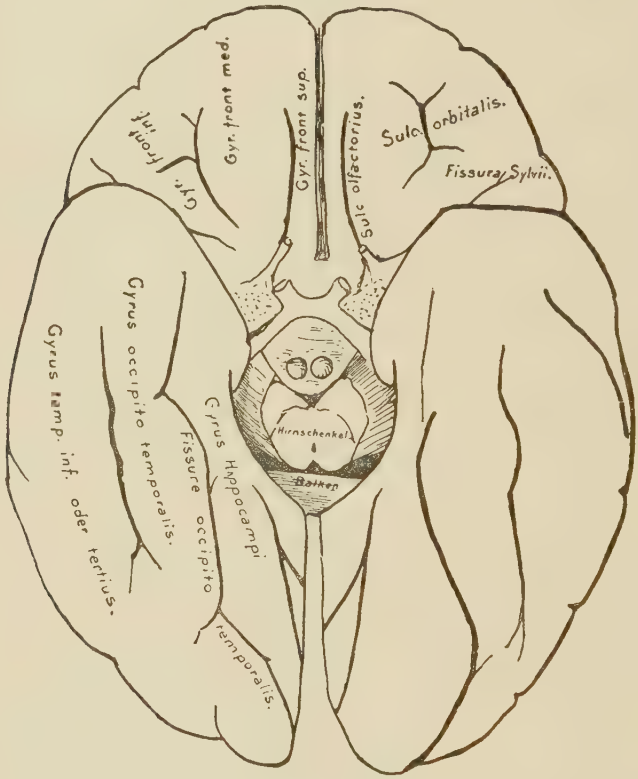

FIG. 35.
The convolutions on the base of the brain (diagrammatic). (After Ecker.)

Motor symptoms of irritation (from the twitching of single muscles up to epilepsy) may arise from any part of the cortex, but there exists a zone of the brain embracing both central convolutions, injury to which is almost always accompanied by motor disturbances on the opposite side of the body. The disturbances may be divided into symptoms of irritation and symp-

toms of degeneration. The symptoms of irritation are shown by convulsive movements; the symptoms of degeneration by a greater or less inability to set the muscles in motion at will, oftentimes only in a sense of weakness, or by awkwardness in executing some complicated movement.

From careful analysis of known cases of disease, it is certain that, in injury of the upper part of both central convolutions and the paracentral lobule, the motor disturbances are most

FIG. 36.
Lateral view of brain. The "motor region" shaded. (After Exner.)

prominent in the legs, that when the lower end of the central convolutions is involved the regions supplied by the facial and hypoglossus suffer most, and that motor disturbance of the upper extremities follows when the middle and a part of the upper third of these convolutions are involved. The divisions between these separate "centres" are not sharply drawn.

Complete destruction of separate portions of the cortex in the human being may lead to permanent paralysis of the muscles

standing in relation to the affected part. The paralyzed muscles almost always fall into a contractured state.

Injuries which involve the cortex of the inferior frontal convolution or the island of Reil, if situated on the left side, generally result in the more or less complete loss of speech, although the vocal organs may still be normally innervated and the person affected may perfectly understand all said by others. It appears that the ability to understand whatever is said in a loud voice is lost when the superior temporal convolution is involved.

Disease in the region of the occipital lobe may lead to disturbances of vision, which may be present only as a dimness of vision or as a blindness on the outer side of the eye on the affected side and on the inner side of the opposite eye.

Sensibility may also suffer from affections of the cortex of the brain. The most commonly observed symptoms are feelings of numbness, heaviness, and marked disturbance of the muscle sense. The sense of touch is, as a rule, dull so far as the judgment of the patient is concerned, but very slight sensory irritations may still be felt, if they are of a simple character (touching with a feather, point of a needle, etc.). We do not know of any particular parts of the cortex disease of which especially leads to disturbances of sensation. At all events, such disturbances may follow diseases of the central convolutions and their vicinity.

The paralyses which follow disease of the cortex are hardly ever so complete as those which are caused by destruction of the peripheral nerves or their proximal end in the spinal cord. In animals it is generally impossible to produce a permanent paralysis by removing the cortex of the motor zone or the whole portion of the brain which contains that zone. We can, however, almost without fail, produce contractions of definite muscles by irritating certain circumscribed portions of the cortex.

This much, however, has been made certain by experiments upon animals and by pathology, that the actual motor centres

lie far back between the corpora quadrigemina and the spinal cord; that they are, however, so connected with centres situated in the cortex that irritation of the latter gives rise to movements. There is a conflict of opinion as to the nature and importance of the influence exercised by the higher centres over the lower. For this reason we study with the utmost scrupulousness those phenomena which follow the removal of portions of the cortex. Doubtless the importance of the rôle played by the cortex differs in different animals. While in the lower animals the removal, even of the whole cerebrum, does not prevent the vigorous execution of coarser movements, yet in mammals the destruction of even circumscribed portions of the motor zone gives rise to temporary paralysis, and in the human being disease of relatively small parts of the cortex often leads to a permanent paralysis. It is evident that all motor and many sensori-psychic functions may start from deep-lying centres, but the higher we ascend in the scale of animal life the more is the cortex concerned in cerebral activity, and consciousness plays a more prominent part. Man has reached a stage in this connection in which many of the functions cannot be performed without the participation of the cortex. In mammals all possible degrees of variation are observed. Thus is explained the fact that irritation of certain tracts of cortex will give rise to muscular action, and yet movements may be executed after those particular parts of cortex have been removed. In man the greater part of the surface of the hemispheres has become indispensable to the proper performance of such movements.

LECTURE V.

THE CORTEX OF THE FORE-BRAIN, THE WHITE SUBSTANCE OF THE HEMISPHERES, THE COMMISSURES, AND THE CORONA RADIATA.

GENTLEMEN: In the previous lecture you were taught the appearance of the surface of the brain, the fissures which traverse it, and the convolutions situated thereon.

To-day's lecture is intended to give you a more intimate knowledge of the structure of the cortex, and to place before you a general view of the connections of the various cortical regions with one another and with the deeper-lying structures.

We know the elements only which go to make up the finer structure of the cortex. The actual connections between these elements are still hidden from us, and therefore, unfortunately, we are deprived of the very essentials for a correct understanding of the anatomical substratum of the great organ of the mind. There is scarcely a doubt but that the cortex, taken as a whole, may be regarded as the region where most of the conscious mental processes take place; that in it is the seat of thought, and that from the cortex all conscious voluntary acts proceed. The whole hemisphere is covered by the cortex. This, however, has not the same structure at all points of the convexity, and although we can make out a sort of fundamental type, yet there is a wide departure from this type in different parts of the cortex, particularly in those layers which contain the ganglion-cells and nerve-fibres. One structural type never passes abruptly into another. Inasmuch as the significance of these anatomical variations is unknown, let us to-day only consider the cortex of one region,—of the frontal lobe. Here, just under the pia mater, lies a layer of neuroglia with numerous glia-cells. It contains a thick net-work (*l* in the accompanying

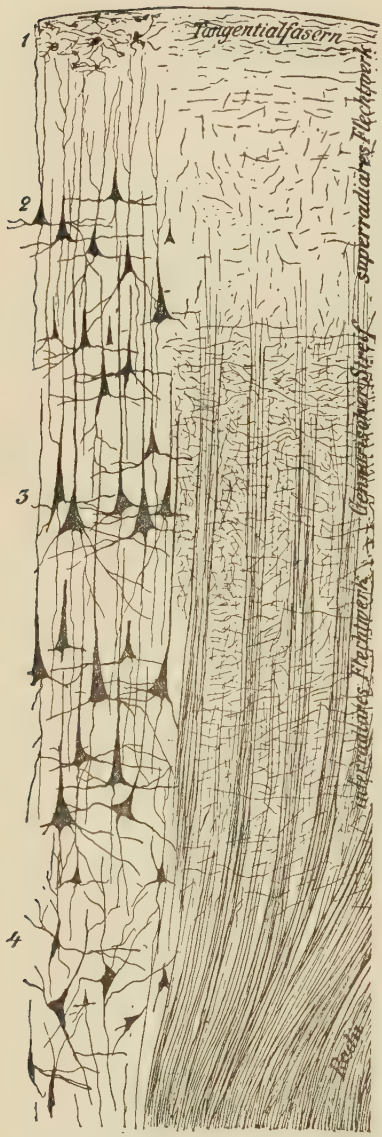

cut) of very fine medullated fibres. Not until we pass this layer of neuroglia do we meet with the real ganglion-cells of the cortex. They all have a more or less clearly defined pyramidal shape, and send out apex processes, lateral processes, and axis-cylinders. The location and appearance of the first two are made clear in the cut, but it is more difficult to recognize that process which becomes an axis-cylinder. According to Golgi there are everywhere in the cortex cells with branched and those with unbranched axis-cylinders. The majority of the processes are directed inward toward the white substance of the hemispheres. The deeper we go into the cortex, the larger do the pyramidal cells become and the longer are their apex processes. We can divide the cortex into several layers, according to the size of the cells. Under the glia layer (marked *1*) comes the layer of small cells (*2*). This passes imper-

FIG. 37.—Section through the cortex of a frontal convolution. On the right the cut is taken from a specimen stained by Weigert's hæmatoxylin method; on the left, from specimens treated, according to Golgi, with sublimate. On the right only the fibres, on the left only the cells, are to be seen. The latter were present in greater abundance than as shown in the cut. Inasmuch as the spaces around the cells are filled in when Golgi's method is used, the latter appear larger than they really are.

Gennarischer Streif, Line of Gennari.
Interradiäres Flechtwerk, Inter-radial net-work.
Superradiäres Flechtwerk. Super-radial net-work.
Tangentialfasern, Tangential fibres.

ceptibly into the third layer (*3*), which contains the large cortical pyramids. The next layer (*4*) consists of smaller and irregularly pyramidal cells. Possibly, however, these may be similar to those lying more superficially, except that they have not reached their full development, for they lie wedged in between the masses of medullary fibres which pass into the cortex. These fibres, after reaching the cortex, break up into numerous fine fibrils, and are gradually lost in finer and more superficial net-works, or become continuous with the axis-cylinders of the cells. Aside from these we see vast numbers of other medullated nerve-fibres in the cortex. Whence they come or whither they go is still utterly unknown.

Even though the explanation of the ultimate mechanism of the organ of mind is wanting, still we have of late years come nearer to it, chiefly by means of the finer technical methods in use. As long as we cannot give all these fibres a name corresponding to their function, it will be better for the sake of clearness (for instance, in researches in pathological anatomy) to give them provisional names. Let us distinguish (1) radiating medullary fibres, (2) inter-radial net-work consisting mostly of fibres parallel to the surface, (3) super-radial net-work, and (4) tangential fibres. Along the boundary between the inter-radial and super-radial net-works the former becomes markedly thickened. This layer, everywhere visible as a white line, is so strongly marked in the vicinity of the cuneus as to be easily recognized. It is called the line of Gennari or, after its later describers, the line of Baillarger, and, in the vicinity of the cuneus, the line of Vicq d'Azyr. In the occipital lobe this line lies deep in the third layer, nearer the fourth than is shown in Fig. 37, which represents the frontal lobe.

As was previously stated, the cortex has not the same structure at all points of the surface. Besides the peculiarities imparted to it in the vicinity of the calcarine fissure by the line of Gennari, the cortex of the gyrus hippocampi presents a characteristic appearance on account of the involution in the region of the

cornu ammonis and the intercalation of the atrophic cortical bundle of the gyrus dentatus.

The pyramidal cells of the cornu ammonis are not directly continuous with those of the gyrus dentatus, as might be

FIG. 38.

Section through the base of the brain and the subjacent gyrus hippocampi. The choroid plexus is drawn somewhat simpler than it really is in the adult. Notice how it separates the ventricle from the cavity of the skull.

Oberflächliches Mark, Superficial medullary matter.

expected from the diagram, Fig. 34. They end rather by being massed irregularly together (at *a* in Fig. 38), and this irregular mass is surrounded by the regularly placed cells in the curve of the gyrus dentatus. These and the other layers which

arise from the involution have, unfortunately, received special names. As we, however, know what portions of the general cortex are represented by the different structures of the cornu ammonis, it is better to regard the latter genetically and not disturb our comprehension of its arrangement by using the old names. Let us follow the cortex from below upward in the accompanying figure. You see that the superficial layer of medullary fibres becomes thickened far ventrad of the point where it is rolled in. Nowhere else in the brain so well as at this point can it be seen that these fibres, which in great part run in the longitudinal axis of the brain, originate in the radiating fibres below. Near the gyrus dentatus a portion of these fibres pass to a somewhat deeper layer of the cortex, while the rest remain superficial and become blended with the adjoining analogous layer of that structure. Here, as everywhere else, the radiating fibres pass inward from the cortex. In the vicinity of the gyrus hippocampi, however, so few of these fibres arise that they do not form a thick medullary deposit underneath the cortex, but only a thin layer. This thin coating covers the side of the cornu ammonis which is toward the ventricle, and at the tip of the fold is gathered up into a medullary bundle, no longer covered with gray matter. This is the fornix. Into it pass also the few fibres which spring from the little gyrus dentatus.

The course of many of the cortical fibres differs in the cornu ammonis from their course in other regions of the cortex. Inasmuch, however, as the origin and significance of the whole net-work shown in Fig. 37 is so uncertain, you will not be specially interested in the analogous structures of the cornu ammonis. Of the greatest importance was the discovery of Tuczeck, that in progressive paralysis of the insane the net-work of fibres in layer *1* is destroyed, and that the fibres in the deeper layers, down to layer *4*, successively disappear.

The nerve-fibres of the cortex receive their medullary investment at a very late period. This takes place first in the superior parietal lobe during the ninth fœtal month. In the

first month of post-fœtal life a few fibres of the anterior central convolution receive their medullary sheaths. Later, in the second to third month, the medullary sheaths are developed in the cortex of the occipital lobe. It is probable that these conditions correspond to the time when the individual first begins to retain memory-pictures in the different regions of the brain; that, for instance, the cortex of the visual centres is developed as soon as conscious visual impressions are received.

In later life still more extensive tracts become medullary. After the third year it is impossible to trace this increase for the reason that the medullated fibres have already become too universal. Nevertheless, there is a great probability that this additional development of medullated fibres continues for many years, and that new nerve-tracts are continually developed as new regions of the cortex are brought into activity.

Below the cortex lies the white substance of the hemispheres. The homogeneous white mass which is revealed by a section through the centrum semiovale is resolved by the microscope into a great number of fibres crossing each other in every direction, and defying our attempts to differentiate them. Let us endeavor to ascertain what is at present known about these white fibres.

If we make a section through the fresh brain of a newborn child we shall see that below the cortex there lies almost everywhere a peculiar, glistening, reddish-gray mass, in which at only one point—underneath the posterior central convolution and its vicinity—medullary fibres can be found. It is only in the course of the first months of the post-natal period that other nerve-tracts become invested with medullary substance. This takes place first in those bundles of fibres which pass downward from the cortex, afterward in those which connect the different regions of the cortex with each other. The latter, the fibræ propriæ of the cortex, are especially abundant in the adult brain. They extend everywhere, from convolution to convolution, connecting parts which lie near each other as well as those which are widely

separated. They connect whole lobes with one another. Apparently these "association-fibres" are developed when two different regions of the cortex are associated in a common action, or they are developed into medullary fibres from among the surrounding mass of indifferent bundles when they are brought into more continuous use than the latter. The association-fibres lie, in great part, close under the cortex; some of them also lie partly in the white substance of the hemispheres. This system of fibres is, as you see, especially adapted to bring all parts of the brain into communication with each other. The manifold processes of association which are indispensable to thought, motion, and sensation possibly have their anatomical substratum in these elements of the brain. It is not improbable that these fibres play an important part in generalizing the movements of epileptic seizures.

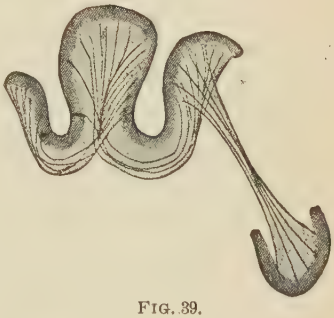

FIG. 39.
Diagram of the fibræ propriæ of the cortex.

It is possible, in animals, to produce contractions of the associated muscles by irritating certain regions of the cortex, and, by increasing the irritation, to produce convulsions of the whole affected side. The order of these convulsions corresponds to the arrangement of the affected centres in the cortex. As this irritation extends it never skips a neighboring motor centre. The convulsions, when they have affected one-half of the body, pass over to the other half (under certain conditions, intensity of the irritation, disposition of the animal experimented on, etc.). Removal of single motor centres from the cortex causes the muscles directly controlled by them to be omitted from the general convulsive seizure. It is not necessary that the point of cortex so irritated should belong to the motor region. The convulsions thus brought about show the greatest analogy to a partial or general epileptic attack in human beings. Since the writings of Hughlings-Jackson, we are acquainted with forms

of epilepsy which begin with contractions or convulsions in one limb and spread to other members, or over the whole body; in the latter instance presenting a typical picture of an epileptic seizure. Consciousness does not always disappear so long as the attack remains partial. After the attack there sometimes remain paralyses, which are generally confined to the regions first attacked. This partial or cortical epilepsy cannot be differentiated from the classical epilepsy. The latter is apparently

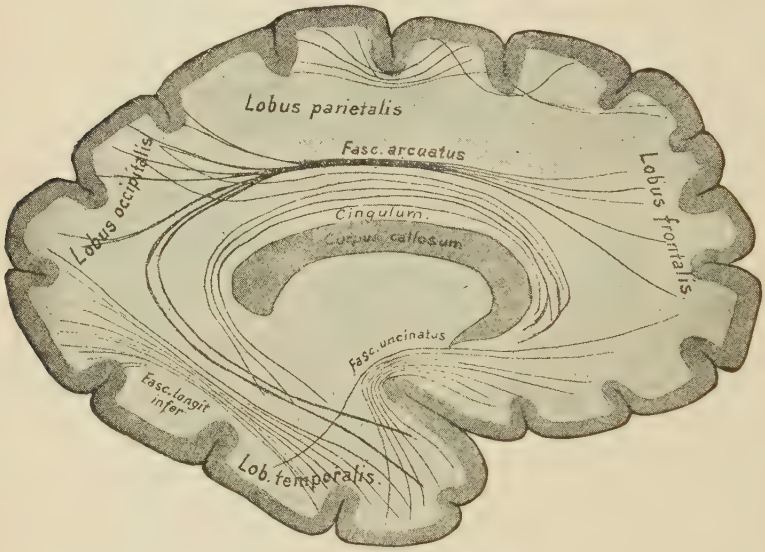

FIG. 40.

Diagrammatic representation of a part of the association fibres of one hemisphere.

only a form in which the initial symptoms succeed each other with greater rapidity.

It is, however, not necessary that an irritation should spread from a given point over the rest of the brain by way of the fibræ propriæ. There are many other ways offered by which this might be accomplished. For instance, through the fine network of nerve-fibres on the surface of the brain; then, too, the whole cortex may be influenced by fluctuation in the blood-pressure, and many other ways might be thought of.

It is not very difficult to trace the course of the fibræ pro-

priæ between two neighboring regions of the cortex by teasing. The representation of the connections existing between more widely separated regions is much more difficult, and the figures must be at least partly diagrammatic, not representing the actual course of fibres. A few bundles only can be easily discerned. Such are the fasciculus uncinatus, the fasciculus arcuatus, the fasciculus longitudinalis inferior, the cingulum, and a few more. You may see the course of these bundles in the accompanying diagram. Among these larger association-bundles there are few that contain very long fibres. They consist rather of numerous shorter fibres, which run in the same direction, each covering a certain part of the whole distance to be traveled. These fibres, which connect the different parts of one hemisphere with each other, are mixed with fibres which connect the corresponding portions of the two opposite hemispheres. These latter fibres run almost exclusively in the corpus callosum and the anterior commissure, thus passing transversely through both hemispheres, from one to the other.

FIG. 41.

Frontal section through the fore-brain. Diagram of the course of the corpus callosum and the anterior commissure.

Inasmuch as you are probably acquainted with the general macroscopic appearance of the corpus callosum, at least that portion of it which is distinct from other parts of the brain, I shall have only a few words to say concerning the accompanying Fig. 41.

You must keep in mind that, just as you see the fibres passing from side to side in this section, which is made about transversely through the chiasm, so they are to be seen in the whole region of the brain over the lateral ventricles. Fibres also pass into the corpus callosum from the anterior and posterior regions. The course of the fibres of the corpus callosum,

which can be plainly seen on the median surface of the brain, is shown in Fig. 42, with the help of which you will easily be able to form a general idea of the distribution of the fibres of this body. Only the fasciculus, called the tapetum, does not belong to the corpus callosum, as was formerly thought. It is present in cases where the corpus callosum is wanting (Kaufmann, Onufrowics). In those cases it is apparent that it is the caudal radiation of the fasciculus arcuatus.

Near the floor of the third ventricle a second mass of fibres passes transversely across in front of the anterior ventricular wall and the crura of the fornix. This is the anterior commissure. It cannot be traced on a cross-section, as is shown in the partly diagrammatic Fig. 41. Its fibres are much more curved, inasmuch as they pass arch-like through the corpus callosum on each side, curving downward and backward, and are lost in the white substance of the temporal lobe. In Fig. 46 this arch has been cut through, on both sides, external to and below the nucleus lentiformis. A part of the anterior commissure, which is only slightly developed in human beings, but strongly developed in lower animals, connects the two points of origin of the olfactory nerves (olfactory-lobe division of the anterior commissure). It is the little bundle which passes downward into the gray matter in Fig. 41.

From every part of the cerebral cortex numerous fibres arise, which connect the cortex with the deeper-lying portions of the central nervous system. Very many pass into the thalamus, others may be traced to the gray masses of the mid-brain and to the nerve-nuclei of the pons, in which they seem to terminate. A number pass farther back through the capsule, the crus cerebri, the pons, and the medulla oblongata to the spinal cord, where they enter the gray matter at different levels.

Taken together, these fibres which pass downward from the cortex are called the corona radiata. You will form no bad idea of these if you can imagine the thalamus placed free under the overarching dome of the cortex, and then assume that fibres

pass from every part of the latter to terminate in the former. Bundles of fibres pass to it from the temporal and occipital, the frontal and parietal lobes. Perhaps, also, bundles from the cortex at the entrance to the fossa of Sylvius and from the cornu

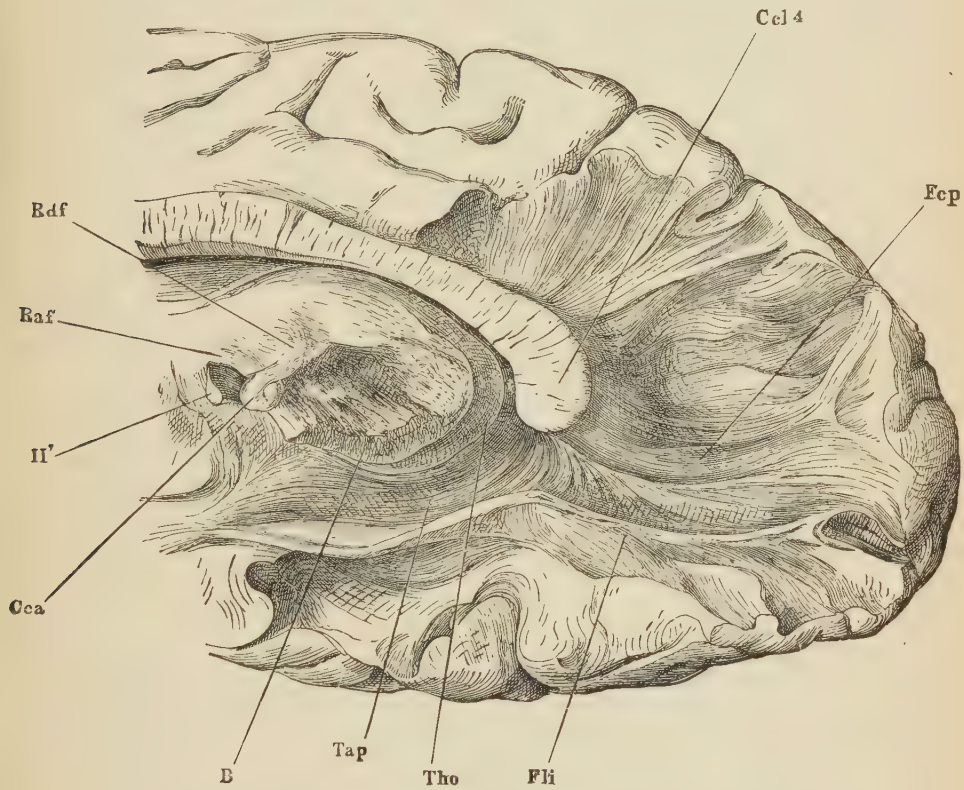

FIG. 42.

Posterior portion of right hemisphere, internal surface. By teasing out with forceps the fibres of the posterior extremity of the corpus callosum (splenium *Ccl*[4]) is shown. The round mass under the corpus collosum is the thalamus opticus, *Tho.* From the wall of the surrounding ventricle the tapetum, *Tap*, passes to the corpus callosum. In the cut, too, is shown a portion of the fasciculus longitudinalis inferior, *Fli.* Beneath the thalamus is the crusta, *B.* The other letters refer to parts which will be explained in the text later on. *Rdf*, Vicq d'Azyr's bundle; *Raf*, fornix; *Cca*, corpus candicans; *II'*, optic nerve. The bundle of fibres called the forceps, *Fcp*, belongs to the radiation of the corpus callosum. (After Henle.)

ammonis (running their course in the fornix). A part of the bundles of the corona radiata, however, do not go to the thalamus, but pass in front to the outside and back of it, to terminations which lie deeper.

The corona radiata, therefore, consists of fibres which pass to the thalamus, and of fibres which pass to deeper regions.

Fibres pass to the thalamus from almost all the surface of the cortex, and not in a few bundles merely, as is shown in the following diagram. They unite near the thalamus to form thick strands, which are called the pedicles (stilus) of the thalamus.

Among fibres passing farther caudad are:—

1. Fibres from the cortex of the central convolutions and the paracentral lobule; that is, from the motor region of the brain to the nuclei of the motor nerves in the brain and the spinal cord (pyramidal tract).

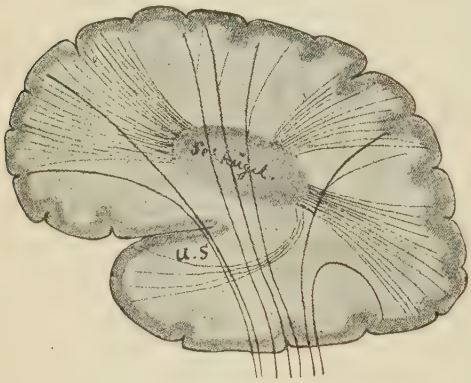

FIG. 43.
Diagram of the fibres of the corona radiata, especially the coronal fibres to the thalamus. *u.s.*, inferior pedicle.
Sehhügel, Thalamus.

2. The speech-tract, to the nuclei of the nerves in the oblongata which have to do with speech. Its origin in the cortex of the third frontal convolution, its course through the white substance to the outside of the tail of the nucleus caudatus, and its termination in the nuclei above mentioned, have all been inferred from carefully-observed clinical cases, verified by autopsies. It has not yet been actually demonstrated by dissection. The speech-tract in passing over the anterior portion of the nucleus lentiformis lies very near the central hypoglossal tract.

3. Bundles from the cortex of the frontal lobe to the pons or, rather, to its ganglion-cells (anterior cortical tract to the pons). They pass, in all probability, from the pons into the cerebellum.

4. Bundles from the cortex of the occipital and temporal lobes, also ending, apparently, in the ganglion-cells of the pons (posterior cortical tract to the pons).

5. Bundles run from the cortex of the superior parietal lobe (and the posterior central convolution?) and perhaps, also, from more posterior cortical regions, to the internal capsule, and in part pass under the thalamus to the spinal cord, and partly enter the lenticular nucleus. They pass through both inner divisions of the latter, and become united near the base of the brain to form a thick strand, whose course we shall have occasion to study later on (tegmental radiation). These latter are the first cerebral fibres to receive their investment of medullary sheaths. They alone at the eighth to ninth fœtal month may be recognized as a thin, white bundle in the internal capsule, which latter, at this period, appears gray.

6. Fibres pass from the occipital lobe to the points of origin of the optic nerve. They connect the real optic nucleus with the cortex. In Fig. 44 this optic radiation is shown in a horizontal section of the brain of a nine-week-old child.

Its destruction in human beings leads to disturbances of vision, which will be described later on. In animals it does not appear to be so important, for in them the occipital cortex can be destroyed on both sides without producing blindness. The actual centres for the sense of sight lie deeper; sight continues if only they are preserved intact, but it is diminished to a certain extent if the connection between these lower centres and the cortex is destroyed. This connection, which evidently subserves some psychic process, is most important in human beings; it is apparently less so in the other mammals. In the lower animals, fishes, for instance, it is altogether wanting. These latter see, at least in the case of teleostians, without anything more than a thin, epithelial vesicle in place of a cerebrum.

Doubtless there are a great number of other systems in the corona radiata. Observations bearing on this point must be undertaken on the brains of very young children. The fibres receive their medullary investment at different periods, and, so far as we know, the whole corona radiata is medullary at the end of the second year.

On their passage downward, the fibres of the corona radiata enter into important relations with the corpus striatum and the optic thalamus.

They naturally converge, and so reach the space outside the thalamus. The fibres from the anterior portion of the brain must, in order to reach this point, pass through the corpus

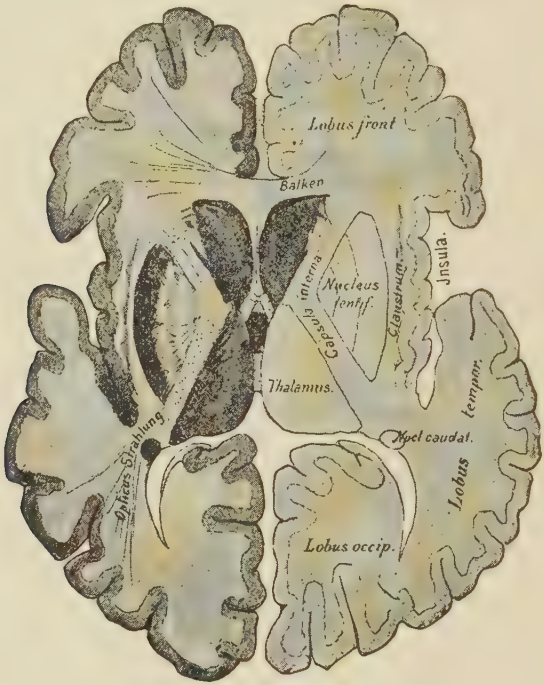

FIG. 44.

Horizontal section through the brain, trending downward on each side.

Balken, Corpus callosum. *Opticus Strahlung*, Optic radiation.

striatum. This is made clear in the accompanying horizontal section through the cerebrum.

This section is made about a finger's breadth lower down than the one shown in Fig. 19. You must understand that the two hemispheres have been partly removed, and that their coronal fibres pass from above downward through the knee-shaped white line of the inner capsule. That portion of the capsule which comes from the frontal and occipital lobes lies partly in the plane

of this section. A few words now in explanation of this figure.

You will at once recognize the frontal, occipital, and temporal lobes. The latter is placed over the island of Reil and in part covers it. As in Fig. 19, you see, in front, the transversely divided corpus callosum, the septum pellucidum adjoining, and, at the posterior termination of the latter, the ascending pillars of the fornix.

Anterior and external to the septum is the head of the nucleus caudatus, which, in this section, has been cut into. Its tail, which, in Fig. 19, passes along the side of the thalamus,

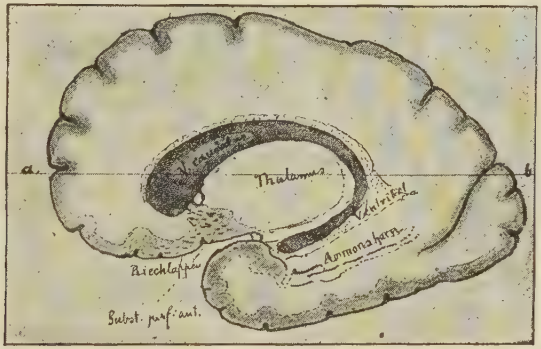

FIG. 45.

Nucleus caudatus dissected out along its whole length. (Diagrammatic.)

Ammonshorn, Cornu ammonis. *Riechlappen*, Olfactory lobe. *Ventrikel*, Ventricle.

can no longer be seen. It lies in the part of the brain which has been removed. A small portion of it only is left, posteriorly and exteriorly, near the cornu ammonis. The above cut, which represents a nucleus caudatus dissected out, shows how this condition is brought about.

The tail of the nucleus caudatus is bent in a curve around the whole brain-axis, and can be traced almost to the apex of the inferior horn of the lateral ventricle. The whole nucleus, therefore, must appear twice on any deep horizontal section of the brain, as is shown by the line *a* to *b*, in Fig. 45.

Outside the head of the nucleus caudatus we see some

thick masses of white fibres. They come from the frontal lobe, and contain the corresponding portions of the coronal fibres to the thalamus (thalamic radiations) and the anterior cortical tract to the pons. These fibres must, as you see in the cut, in order to reach the thalamus and the pons, pass through the interposed corpus striatum. The part which remains lying nearer the

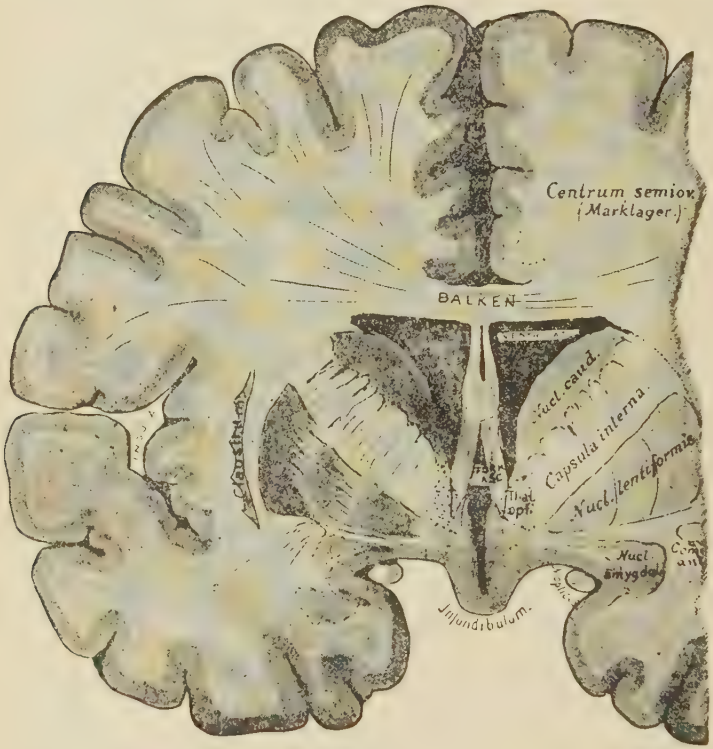

FIG. 46.
Frontal section through the fore-brain just back of the ascending pillars of the fornix.
Balken, Corpus callosum. *Marklager*, White substance.

median line is the nucleus caudatus; the external part is the nucleus lenticularis. The two are not absolutely and totally divided by these frontal-lobe fibres; on the contrary, numerous connecting fibres pass between them. The above-named thalamic radiations, the anterior cortical tract to the pons, the bundles passing between the head of the nucleus caudatus and the

lenticular nucleus, and, lastly, fibres from the nucleus caudatus to the inner divisions of the lenticular nucleus, all go to make up the internal capsule,—the white mass of fibres shown in the horizontal section.

Fig. 46 is intended to complete the picture of those parts given in the horizontal section. It strikes the ganglia of the corpus striatum far forward, and clearly shows the manner of their separation by the interposed fibres of the internal capsule.

The form and situation of the nucleus caudatus will now be clear to you, but it will be more difficult to form an idea of the peculiar wedge-shaped figure of the lenticular nucleus. A study of the horizontal and of the vertical sections shown in Fig. 46 will materially aid you. This ganglion is intimately associated internally with two somewhat lighter, grayish ganglionic masses, which are closely connected to it by nerve-fibres. We speak ordinarily of the three divisions of the lenticular nucleus, whereas it is probable that only one—the broad, dark, outer portion (the putamen)—is morphologically analogous to the nucleus caudatus. The latter, as above stated, sends its fibres through the anterior branch of the internal capsule to the two inner divisions of the lenticular nucleus, and, perhaps, through them and farther caudad. The fibres of the putamen run an exactly similar course.*

In all vertebrates, from fishes up to birds, a thick bundle of fibres can be seen, arising in the corpus striatum and ending partly in a thalamic nucleus and partly passing farther back. It can only be found with difficulty in human beings, because too many bundles from the cortex are united with it. Still, I have recognized this basal fore-brain bundle in early embryos, and it is apparently these fibres which Wernicke and Flechsig have described as springing from the corpus striatum. The latter, indeed, recognized their connection with the thalamus.

* The fibres arising in the ganglia of the corpus striatum receive their medullary sheaths at a much later period than the tegmental radiation which passes through the inner divisions of the nucleus lentiformis. Hence, we have succeeded in distinguishing these two sets of fibres, which are closely intermingled in the adult.

External to the corpus striatum lies the cortex of the island of Reil. In the narrow band of white substance which lies between the ganglion and the cortex—that is to say, in the external capsule—is placed an elongated collection of ganglion-cells, —the claustrum,—which is anatomically somewhat different from the neighboring cortex.

Caudad of the nucleus caudatus the horizontal section (Fig. 44) passes through the thalamus,—the inter-brain. In front of this the pillars of the fornix ascend from below; the

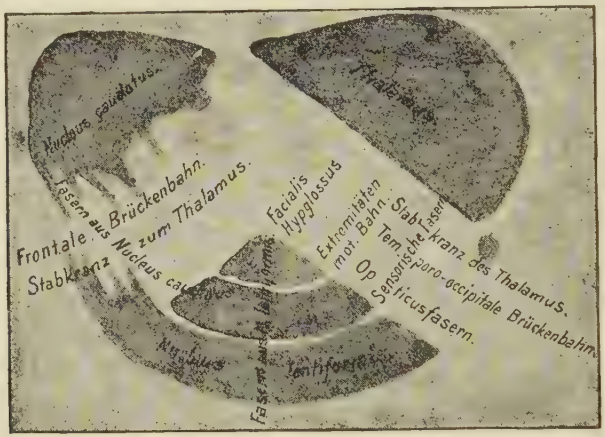

FIG. 47.

Diagram of the internal capsule. The situation of most of the tracts of fibres which compose it is indicated by the names.

Extremitäten mot. Bahn, Motor tract to the extremities.
Fasern aus Nucleus Caudatus, Fibres from nucleus caudatus.
Fasern aus N. lentiformis, Fibres from nucleus lentiformis.
Frontale Brückenbahn, Anterior cortical tract to the pons.
Opticusfasern, Optic fibres. *Sensorische Fasern*, Sensory fibres.
Stabkranz zum Thalamus, Coronal fibres to the thalamus.
Temporo-occipitale Brückenbahn, Posterior cortical tract to the pons.

commissura media, a thin band of gray matter, extends from one thalamus to the other. External to the thalamus passes the posterior branch of the internal capsule. The point where the two branches meet is called the knee (genu). Impress this peculiar angular form of the inner capsule well upon your memory. The relation of the different coronal bundles to the two angles is particularly important and very nearly constant. In the posterior branch, not far from the knee, lie the fibres from the motor zone to the extremities (pyramidal tract); just

in front of them are situated bundles which connect with the nuclei of the facialis and hypoglossus, and have their origin in the lower portion of the anterior central convolution.

Behind the pyramidal tract, near the last third of the posterior branch, or, perhaps, somewhat more anteriorly, we meet with the bundles known as the tegmental radiation, and back of and adjoining them the tract from the occipital lobe to the origin of the optic nerve. Judging from clinical facts there must be in this region fibres passing from the temporal lobes to the auditory nuclei, and others, also, which are related in some way to the sense of smell. Thus, in the terminal third of the posterior branch of the internal capsule there is a confluence of all the sensory fibres and of the fibres to the nerves of special sense. Besides these, moreover, we here find coronal fibres to the thalamus from the cortex of the temporal and occipital lobes, and the occipito-temporal tract to the pons. The preceding figure gives a diagrammatic view of the separate bundles which compose the internal capsule.

Numerous investigators have turned their attention to the histology of the cortex and to the conditions of its finer structure. However great the labor expended in this field, by just so much does the difficulty of the problem appear to increase. Newer and more complicated conditions are continually being discovered. Baillarger, Bevan Lewis, Clarke, Gerlach, Meynert, Golgi, Bellonci, and many others have attempted to throw light upon the most important points. The cortex of the cornu ammonis in particular has been investigated by Kölliker, Henle, and Duval. Many facts concerning the course of fibres in the white substance of the hemispheres were discovered by F. Arnold, Reil, and Burdach by the teasing method; while the microscopic investigations of Meynert, and more particularly the embryological studies of Flechsig, and the numerous experimental works of Gudden, Löwenthal, Monakow, and many others have materially advanced our knowledge in this respect. We must not undervalue the advantages which have accrued to this portion of brain anatomy from pathological investigations. Such investigations have been instituted by Wernicke, Charcot, Féré, Pitres, Friedmann, Sioli, Monakow, Richter, and others.

All the masses of fibres emerge from the cortex and converge toward the region external to the thalamus. A portion of them enter the thalamus (corona radiata of the thalamus); another portion, and that the larger, pass under the thalamus to terminate in ganglia there situated, or to run still farther

caudad to the spinal cord. Any foci of disease, therefore, which are situated in the centrum semiovale must involve some of the coronal fibres. They, however, do not always give rise to symptoms which would lead us to suspect a break in the conductivity from cortex to periphery. This may be because the coarser and more striking lesion-symptoms, the only ones which can be detected by our present means of diagnosis, require for their development the destruction of the whole tract involved. Apparently a small remnant of a tract suffices to conduct voluntary impulses from the cortex to deeper-lying points, and to convey sensory impressions from the periphery to the cortex.

Lesions, in particular, which do not lie in the white substance under the central convolutions—that is to say, lesions which involve the tract from the cortex to the pons and the tegmental radiation—often give rise to no symptoms. On the other hand, lesions which involve the pyramidal tracts produce paralyses of the opposite half of the body. Disease of the white substance under the cortex of the inferior frontal convolution often leads to aphasia. In addition to these there are a number of conditions known which make it very probable that an interruption of the tegmental radiation may bring about a loss of sensibility in one-half of the body.

It is pretty well established that diseases which involve the region just back of the knee of the internal capsule, diseases, at least, which render the fibres incapable of conveying nervous impulses, suspend the motility of the entire opposite half of the body, and that lesions situated in the terminal two-thirds of the posterior branch may destroy the sensation of the opposite side of the body, or at least very much diminish it. In most cases the sense of sight also suffers, and occasionally the sense of hearing. The injury to the sense of sight takes the form of hemiopia.

If you bear in mind that, as has been repeatedly stated, all the fibres converge radially from the cortex to the capsule, you will easily understand that a small lesion in the capsule may give rise to the same symptoms which would be produced by a

larger one in the centrum semiovale, or by a still more extensive one in the cortex. In the capsule the fibres are crowded closely together, which, higher up, are spread over a greater surface. For example, a great extent of cortex (both central convolutions and the adjoining portions of the frontal and parietal convolutions) would have to be destroyed in order to produce a complete opposite hemiplegia. The same effect might be caused by a smaller lesion in the centrum semiovale under the central convolutions, whereas the symptom-complex in question could be produced by a very small lesion in the posterior branch of the inner capsule. In cases of hemiplegia, therefore, we at once

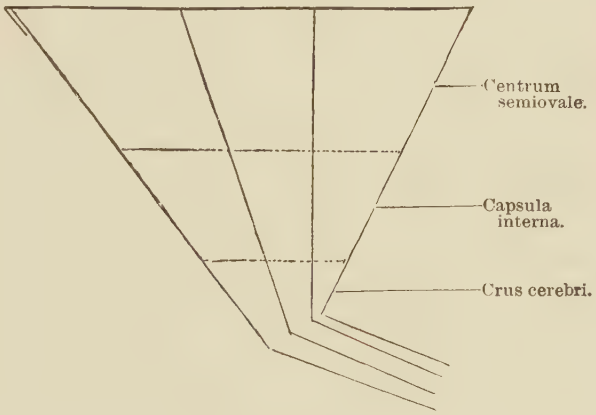

FIG. 48.

suspect that the disease is located in the neighborhood of or in the internal capsule, unless additional symptoms point directly to some other region of the brain. Hemiplegias from disease of the cortex are very rare. Hemiplegias arising from diseased foci in the deeper-lying portions of the central nervous system are still rarer, and are generally associated with cranial-nerve symptoms, which indicate the seat of the lesion.

On the other hand, both anatomical considerations and clinical experience teach us that cerebral diseases which affect single members of the body (one hand, for instance) very seldom have their seat in the capsule, because the fibres there are so

closely crowded together that a focus of disease could scarcely involve individual fibres without affecting others. Disease of the cortex, however, not infrequently causes monoplegias and monospasms. In this portion of the brain a relatively large area may be involved without impinging on an adjoining centre. The accompanying diagram will effectually impress these statements upon your mind. It shows why monoplegias most frequently have a cortical origin, whereas hemiplegias generally result from disease of the deeper-lying portions of the brain. We see at a glance that a lesion of a given extent, situated in the cortex, may easily affect only one centre, whereas the same focus, more deeply situated, might affect the radiating fibres of many centres.

We have not yet learned what symptoms would arise from involvement of the association-fibres alone, because these fibres are so closely blended with those of the corona radiata. Possibly certain forms of disturbance in speaking, reading, and hearing belong in this category. We know, too, very little concerning the symptoms arising from destruction of the corpus callosum. It appears that this may, under certain circumstances, be entirely destroyed without giving rise to disturbances of motility, of co-ordination, of sensibility, of the reflexes, or of the special senses, and without any material disturbance of the intellect. One case of disease of the corpus callosum has been observed accompanied by an uncertain gait, but without vertigo or ataxia.

LECTURE VI.

THE CORONA RADIATA, THE CORPUS STRIATUM, THE THALAMUS, AND THE SUBTHALAMIC REGION. THE STRUCTURES AT THE BASE OF THE BRAIN.

GENTLEMEN: As you saw in the last lecture, a great part of the coronal fibres terminate in the inter-brain, in the optic thalamus. The rest pass farther caudad and ventrad in the capsule. Thus they reach the region back of the thalamus and for the most part lie free on the under surface of the brain. This thick bundle of white fibres emerging from the base of the brain is called the foot of the crus cerebri, pes pedunculi, or crusta.

As you see in the accompanying frontal section, this free portion of the capsule, whose fibres curve backward in the crus cerebri, lies ventrad of the thalamus. Into this, the pes pedunculi or crusta, pass the fibres of the frontal tract to the pons, of the temporal tract to the pons, and of the pyramidal tract. The coronal optic fibres and the tegmental radiation do not enter the crusta. Farther back under the corpora quadrigemina, just over the crusta, in the same relative position here occupied by the thalamus, lie the fibres which spring from the thalamus and other regions of the brain, and the fibres of the tegmental radiation. At this point the mass of fibres from the fore-, inter-, and mid- brains are divided into a ventral portion (the pes or crusta) and a dorsal portion (the tegmentum). First let us turn our attention to the crusta. The accompanying cut (Fig. 50) is an endeavor to show you the transition of the internal capsule into the pes by a diagrammatic horizontal section. The thalamus is represented as transparent. Posteriorly the section trends sharply downward; otherwise it would not show the crusta, which is situated at the base of the brain.

In the diagram you see a tract descending from the ganglia of the corpus striatum. It lies above the tracts from the cortex. In all probability this terminates in the pons.

The relations borne by the fibres from the ganglia of the

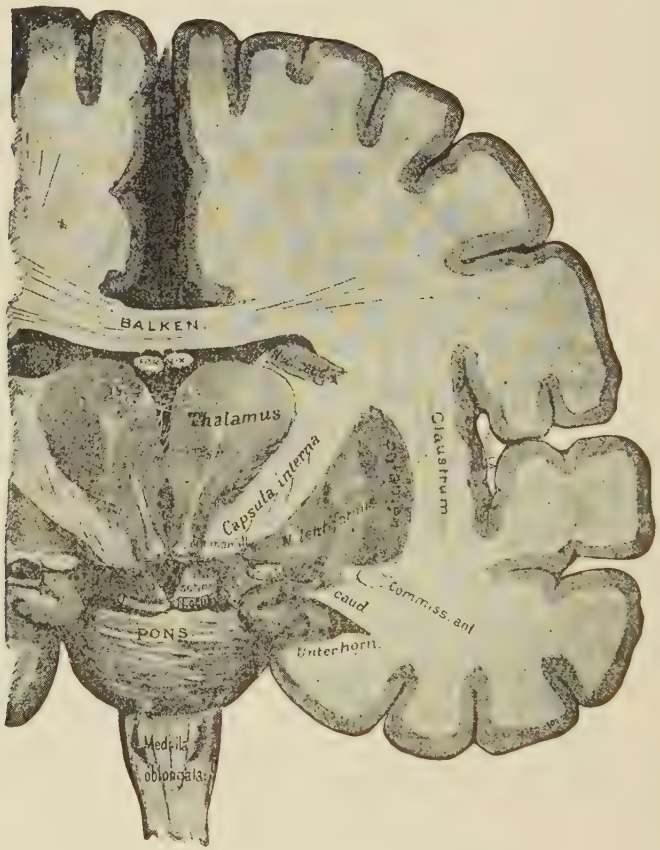

FIG. 49.

Frontal section through the fore- and inter- brains at that point where the fibres of the internal capsule become the crusta.

Balken, Corpus callosum. *Hirnschenkel*, Pedunc. cerebri. *Unterhorn*, Inf. horn.

corpus striatum to those from the cortex are in many respects still unknown. The following are the most important points which have been definitely settled. The nucleus lentiformis consists of an outer division (the putamen) and two or more inner

divisions (the globus pallidus). From the putamen and from the nucleus caudatus fibres arise which pass through both the inner divisions and emerge from the base and apex of the nucleus lentiformis. You will remember from the second lecture that the nucleus caudatus and the putamen are genetically related to

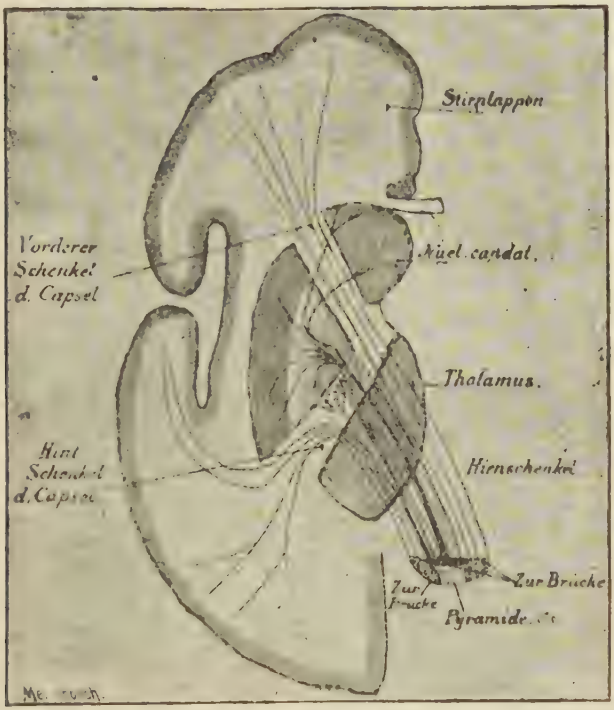

FIG. 50.

Diagram of the course of fibres from the internal capsule into the crusta. (Modified from Wernicke.)

Hirnschenkel, Pedunc. cerebri.
Hint Schenkel d. Capsel, Post. branch of capsule.
Pyramide, etc., Pyramids, etc.
Stirnlappon, Frontal lobe.
Vorderer Schenkel d. Capsel, Anterior branch of capsule.
Zur Brücke, To the pons.

the cortex. Now you see that they also give off fibres just as does the latter.

Besides these fibres, others pass from the cortex to the lenticular nucleus. They are fibres from the tegmental radiation. These emerge from the internal capsule along the whole inner border (see Fig. 51) and pass into the two inner divisions.

traverse them, just as do the fibres from the nucleus caudatus and the putamen, and again, like the latter, they are gathered up into a thick bundle below the nucleus lentiformis, in which situation they are called the ansa lenticularis. Most of the fibres of the ansa lenticularis, after passing through the capsule, extend to the region below the thalamus, called the regio subthalamica. The accompanying cut represents a section through the brain of an eight months' fœtus, and shows the relations of the teg-

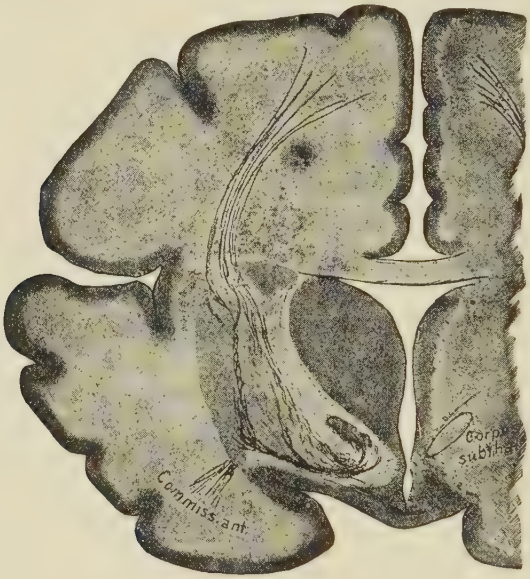

FIG. 51.

Frontal section through the brain of a fœtus of about 32 weeks. All the medullary fibres stained black by hæmatoxylin. The tegmental radiation (above), crusa lenticularis (below), and anterior commissure (below and externally) are medullary. There are as yet no medullary fibres in the putamen or nucleus caudatus.

mental tract to the nucleus lentiformis. At this period of development there are, with the exception of those shown in Fig. 51, no medullary fibres in the brain. The fibres which arise in the putamen and the nucleus caudatus have not yet appeared. It was only possible to gain an insight into the relations between the nucleus lentiformis and the tegmental radiation by studying the fœtal brain.

In this figure the bundle which passes directly from the

tegmental tract to regions farther back (dorsad of the gray mass marked "corpus subthal.") is not visible because it does not fall within the plane of this section. Compare the line in Fig. 52, marked "to the fillet," which represents the course of this bundle. Compare also Fig. 54.

You have now, gentlemen, learned the origin and the first part of the course of a good share of those fibres which go to make up the fore-brain. Let us now turn our attention to the region where a majority of the cerebral medullary tracts terminate.

Back of the hemispheres comes the inter-brain. From each of its lateral walls have developed the optic thalami. These consist of several gray nuclei, which are not sharply divided from one another. Some white medullary fibres, the stratum zonale, pass over the thalamus. A part of these can be traced in a direction toward the base of the brain in the optic nerve, while another part seems to originate from the caudal portion of the internal capsule, perhaps from the optic radiation. All of them pass deeply into the thalamus and are massed together between its ganglia, which they apparently separate from one another. Microscopic examination shows that they enter into the fine network of nerve-fibres which penetrates these ganglia. We can distinguish in every thalamus a median (internal) nucleus which projects into the ventricle, becomes thickened posteriorly, and forms the pulvinar, a lateral or external nucleus, and between the two an anterior nucleus. The lateral nucleus is the largest, while the anterior nucleus may be compared to a wedge driven in between the other two with its broad end to the front. This anterior, thickened end, which is visible as an elevation of the surface of the thalamus, we have already met with under the name of tuberculum anterius. On the median border of the internal nucleus lies the ganglion habenulæ, which has been mentioned before. In the posterior portion of the thalamus below and external to the pulvinar lies a ganglion of a peculiar grayish appearance,—the corpus geniculatum laterale; it projects

far into the substance of the thalamus and gives off a great many roots to the optic tract.

Externally, the thalamus borders on the internal capsule (Fig. 52). Numerous bundles pass from the latter into the

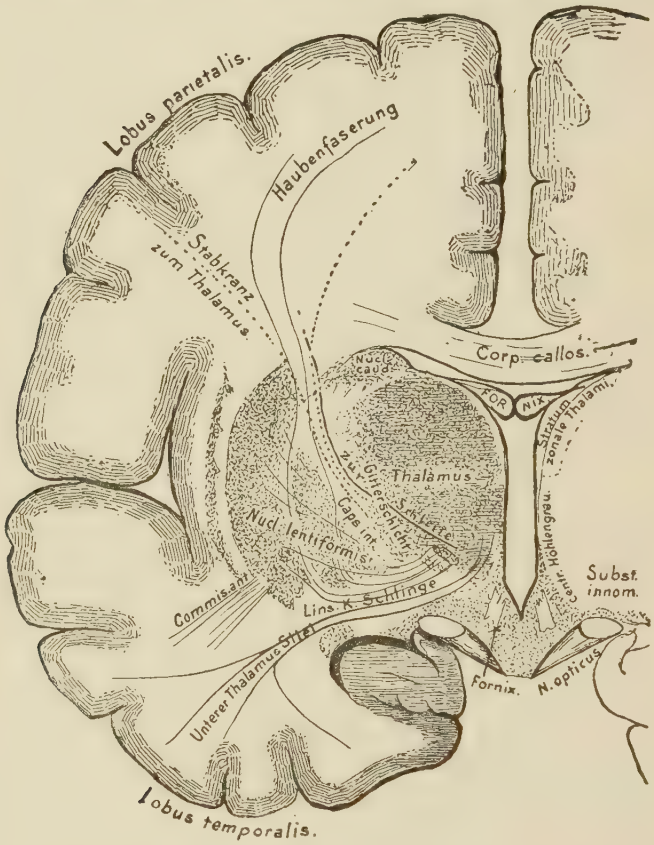

FIG. 52.

Frontal section through the brain in front of the section shown in Fig. 49, just behind the chiasm. (Diagrammatic.)

Centr. Höhlengrau, Central (ventricular) gray matter.
Gitterschicht, Latticed layer.
Haubenfaserung, Fibres to the tegmentum.
Lins. K. Schlinge, Ansa lenticularis.
Stabkranz zum Thalamus, Coronal tract to the thalamus.
Unterer Thalamus Stiehl, Inf. pedicle of thalamus.
Zur Schleife, To the fillet.

former. They come from different directions, and cross each other on entering the thalamus. In this net-work of decussating fibres are found small aggregations of gray matter. The outer zone of these crossed fibres is called the latticed layer.

From the fact that the majority of the medullary fibres pass into the external nucleus, this body has a somewhat lighter appearance than the other nuclei of the thalamus.

The inner surface of the thalamus is separated from the ventricle by an evenly distributed layer of gray matter. This is called the central gray matter of the middle (third) ventricle. In the median line of the brain the central gray matter forms the floor of the ventricle. Between the two thalami lies the middle commissure. In human beings it consists of only a few nerve-fibres passing across in the midst of a large mass of central gray matter. In the lower animals it contains a relatively larger number of medullary fibres, arising in the central gray matter of the ventricles, in which they run parallel to the long axis of the brain.

In the following highly diagrammatic figure we may see the relations of the thalamus to the base of the brain, to the central gray matter, to the internal capsule, and to the nucleus lentiformis.

Let us study in this figure a subject which hitherto has only been touched upon. I refer to the region internal to the lenticular nucleus and ventrad of the thalamus. Here are to be seen several bundles of fibres running parallel with each other, which in part cross the internal capsule at an angle and in part pass over it. The upper of these bundles belongs to the system of fibres of the lenticular nucleus; it is the previously-described ansa lenticularis. The lower bundles are coronal fibres to the thalamus, which, coming from the occipital and temporal lobes, are called the inferior pedicle of the thalamus (*u.s.*, Fig. 43). Taken together the mass of fibres shown in Fig. 52, ventrad of the lenticular nucleus, is called the substantia innominata. Just back of the substantia innominata the fibres of the capsule, which go to make up the crusta, emerge free on the base of the brain. The substantia innominata, therefore, bounds the pedunculus cerebri anteriorly. It is laid like a loop over it, and is on that account called the ansa peduncularis.

Back of and underneath the thalamus there lie alongside it a number of small nuclei whose functions and significance are almost wholly unknown. Their anatomical relations are as yet in great measure unexplored. On the base of the brain, just back of the plane of the section in Fig. 52, where the central gray matter forms the floor of the ventricle, there lies, on each side under the thalamus, a small, white tubercle,—the corpus mamillare or corpus candicans. In Fig. 49 it falls just in the plane of the section. The mammillary body may be regarded as the boundary-point between the fore- and inter- brains, for from

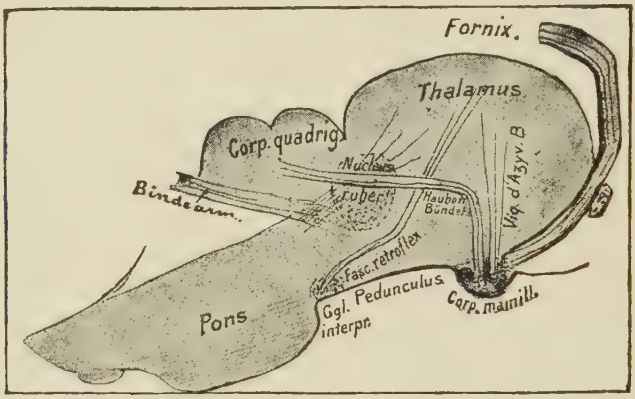

FIG. 53.

Frontal section through the thalamus and the corpus mamillare to show a portion of the fibres originating in this region. (Diagrammatic.)

Bindearm, Anterior cerebellar peduncle. *Haubenbündel*, Fasciculus to tegmentum.

it appear to emerge, partly crossed and partly direct, those bundles to the fornix which follow along the free border of the hemisphere, and whose further course is shown in Fig. 30.

The corpus candicans consists, according to the researches of Gudden, of three nuclei. The most lateral sends a pedicle (pedunculus corporis mamillaris) far back into the medulla oblongata. From the more caudad of the two median nuclei arises a thick bundle, which passes up into the thalamus and is lost in the tuberculum anterius. One portion of its course is shown in Fig. 49. It was formerly thought that it arose in the

thalamus, bent around in the corpus candicans, and passed into the fornix. The investigations of Gudden, however, have disproved this; therefore, its old name, fornix descendens, is not justified, and it is now called, after its discoverer, the bundle of Vicq d'Azyr.* Arising from the more anterior of the nuclei, a little strand of fibres ascends toward the thalamus alongside the last-described bundle, but soon changes its course and passes backward, curving caudad until it reaches the tegmentum back of the region of the corpora quadrigemina, where it can be traced into ganglia that lie under the aqueduct of Sylvius. This is called the tegmental bundle of the mammillary body.

If you will examine Fig. 46 or 49 you will see that the thalamus lies directly upon the internal capsule. Farther back this condition of things ceases. Here several small, gray, ganglionic masses are interposed between the capsule and the thalamus. Into these ganglia numerous bundles of fibres radiate from the nucleus lentiformis, the capsule, and the thalamus itself. The posterior basal inter-brain region where this occurs is called the regio subthalamica. The regio subthalamica was first accurately known through the researches of Luys and Forel, and later by the works of Flechsig and Wernicke. We are, however, still far from a comprehension of the complicated conditions which are presented to us in this little space, where fibres of such widely different origin meet, interloop, and cross each other, and where gray masses lie which are themselves in part permeated by a fine-meshed net-work of crossing and intermingling medullary fibres.

Fig. 54 shows a few details of a section through this region. Below the thalamus is a rounded ganglion,—the nucleus ruber, the red nucleus of the tegmentum. External to it lies the lenticular-shaped corpus subthalamicum (body of Luys). You recollect the bundle of coronal fibres which we called the

* Compare Fig. 42, where by dissection a perceptible loop is brought into view between the two portions of the fornix in the corpus candicans.

tegmental radiation. Its fibres pass out of the internal capsule, and, to a great extent, lie outside of and above the red nucleus, surrounding about a third of that ganglion like a capsule; passing back of the red nucleus they form a tract of fibres which we shall learn to know as the lemniscus, laqueus, or fillet. In Fig. 52 the course of these fibres is shown in diagram. At the

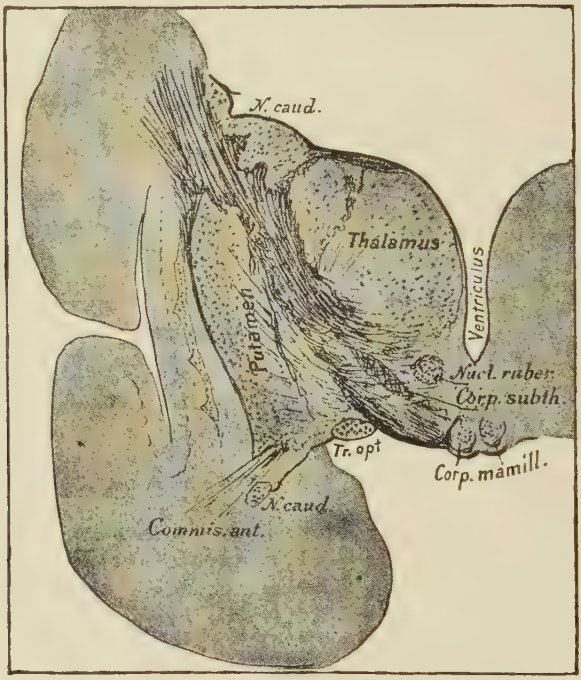

FIG. 54.

Subthalamic region of a 4-week-old child. Frontal section. Compare Fig. 51, where only the tegmental tract is clearly visible.

tip of the lenticular nucleus the fibres from its different divisions and from the ansa lenticularis unite to form a thick bundle. This passes through the capsule (Fig. 52) in numerous fasciculi and enters into a net-work which closely surrounds the corpus subthalamicum. From this net-work most of these fibres pass into the ganglion itself; a few, however (but of this I am not firmly convinced), pass directly from the nucleus lentiformis to

the tract called the fillet without entering into any relation with the interior of the corpus subthalamicum.

Fibres from the optic thalamus run to the red nucleus. Posterior to the accompanying figure the latter becomes much larger, so that it occupies a greater area in cross-section (Fig. 59). Posterior to and below the corpus subthalamicum, just over the fibres of the internal capsule, which at this point are beginning to form the pes pedunculi, there is situated an aggregation of gray, pigmented cells (the substantia nigra), just at the point where the corpus subthalamicum is represented in Fig. 54. From the subthalamic region downward to the termination of the mid-brain this dark, ashen-gray ganglion is always demonstrable just over the crusta.

The fibres passing backward from the fore- and inter- brains are divided by the substantia nigra into two portions, corresponding to their physiological significance,—the crusta and the tegmentum. The former we have already considered at the beginning of this lecture, and we shall often have occasion to refer to it; the latter contains, in the posterior thalamic region, which we are now considering, the pulvinar, the nucleus ruber, the corpus subthalamicum, the fibres from the lenticular nucleus and that part of the tegmental radiation which has not united with the fibres of the lenticular nucleus.

We are now to consider the structures which appear in a transverse section made at a point in Fig. 55 indicated by the line *a* to *b*.

You see that just back of it the mid-brain—the corpora quadrigemina—begins. The thalami at this point become separated and between them the central gray matter increases somewhat, and the middle ventricle thereby becomes much more shallow.

Behind this point the roof of the brain-vesicles, which, in the vicinity of the thalamus, consisted only of the epithelial covering of the choroid plexus, once more becomes distinct. The ventricle is closed above by a roof composed of nerve-

substance, which, from now on, is not lost sight of until we reach the spinal cord.

In the anterior part of this roof are situated the fibres of the posterior commissure, and just behind these are the corpora quadrigemina. The ventricle, which is here contracted to a narrow passage, extends under this roof, and that portion of it which traverses the mid-brain has received the name of the aqueduct of Sylvius. The entrance to the aqueduct lies just under the posterior commissure. It is entirely surrounded by the central gray matter. As it passes over the after-brain the canal again becomes widened, and in this situation is called the ventriculus quartus. Its floor is formed by the fossa rhomboidalis and its roof by the cerebellum.

It will be well for you to study the appearance of the mid-brain roof, verifying the foregoing statements on the sagittal section (Fig. 56).

Only a few words concerning the pineal gland, which, with its two pedicles running along the inner surfaces of the thalami, forms a part of the roof of the inter-brain. (See Fig. 11.) It consists mainly of a dense mass of epithelial tubules which have arisen by proliferation from the primitive fold. The pedicles—the pedunculi glandulæ pinealis—convey a few medullary nerve-fibres. These apparently originate in the ganglion habenulæ and (as may be demonstrated in all the lower vertebrates) in the thalamus. I must again remind you of what was said in the second lecture concerning the significance of the pineal gland in reptiles. Besides the tubules, the pineal gland contains numerous blood-vessels and the "brain-sand,"—little concretions of a laminated structure, which consists mainly of calcareous salts and a small amount of organic matter.

Fig. 55 will show you the situation of the pineal gland at the posterior end of the thalami and between the corpora quadrigemina.

We have hitherto had no opportunity to examine carefully the base of the brain. Now that the source of some of the

structures which are there situated is known to us, let us turn a brain bottom upward, and, having cleared away the pia mater and blood-vessels, study the specimen carefully.

The figure given later on (page 99) will serve as a guide. First, we see the crura cerebri emerging from the mass of the

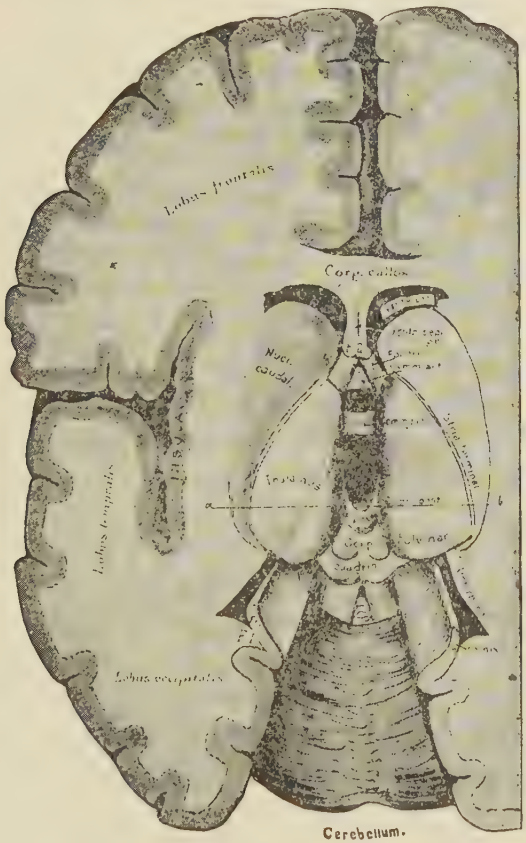

FIG. 55.
The ventricle opened from above.
Unterhorn, Inferior horn.

brain. Just in front of them, in the space which, in the cut, is occupied by the optic nerve, lies the substantia innominata, which contains the ansa lenticularis and the inferior pedicle of the thalamus. Previous frontal sections have taught you that the white mass visible here is the pes pedunculi, which is the

direct continuation of the internal capsule. After passing backward a short distance, the pedunculus cerebri is covered in by a thick mass of fibres, which appear to run transversely across it from one-half of the cerebellum to the other. These are called the fibres of the pons (fibræ pontis).

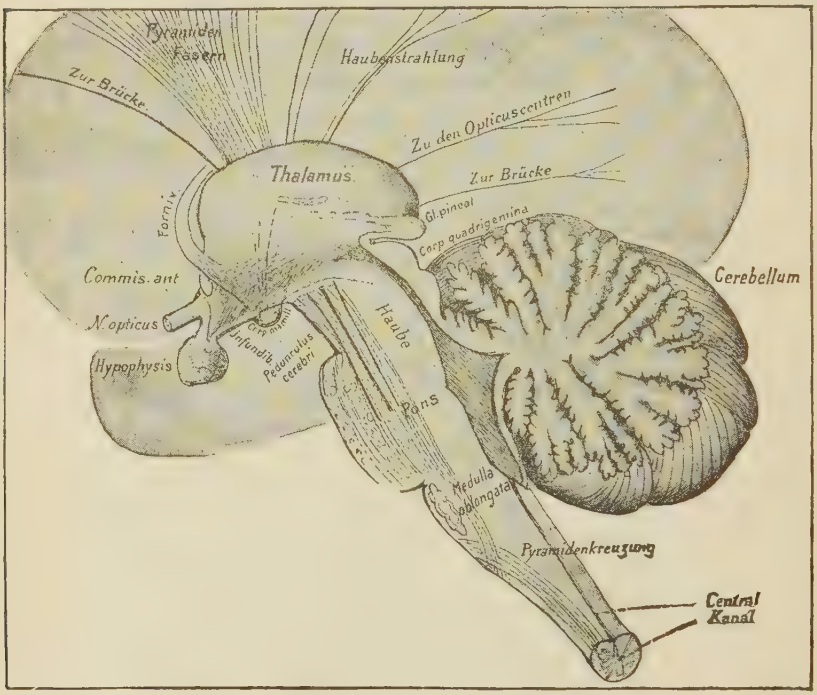

FIG. 56.

Sagittal section through the inter-brain and the structures lying back of it, exactly in the middle line. The course of many fibres of the corona radiata is indicated by lines.

Central Kanal, Central canal.
Haube, Tegmentum.
Haubenstrahlung, Tegmental radiation.
Pyramiden Fasern, Pyramidal fibres.
Pyramidenkreuzung, Pyramidal decussation.
Zu den Opticuscentren, To the optic nuclei.
Zur Brücke, To the pons.

Below the pons a portion of the fibres of the peduncle again comes into view, forming the pyramids. Another portion of the peduncular fibres terminates in ganglia which are located among the fibres of the pons.

The gray matter between the crura cerebri is called the substantia perforata posterior. Internally, it borders on the sub-

thalamic region. In front of it lie the mammillary bodies,—those two roundish ganglia which we studied in cross-section. To these ganglia the bundle of Vicq d'Azyr passes from the thala-

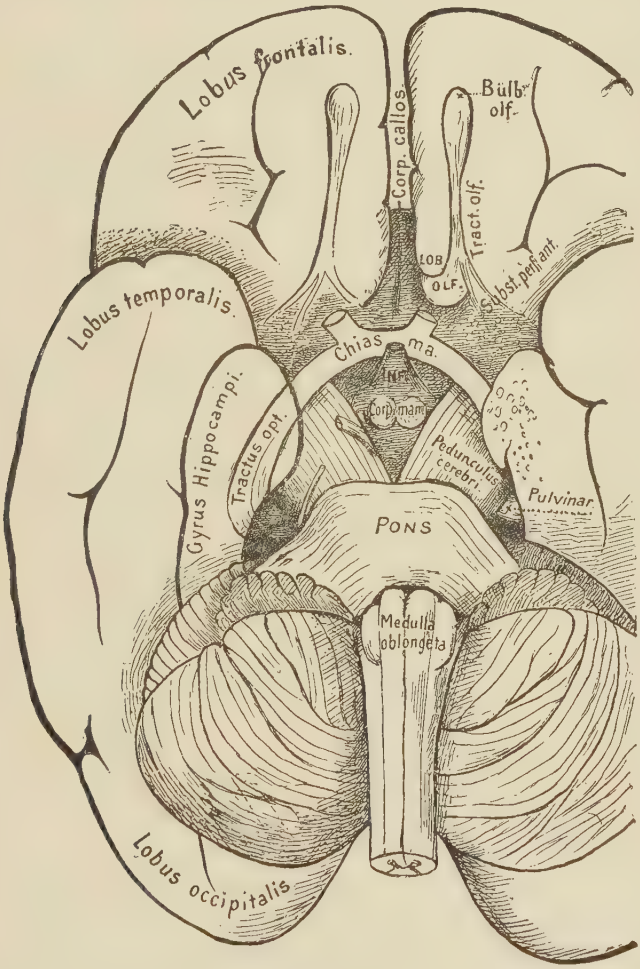

FIG. 57.

The base of the brain. The left temporal lobe represented as in part transparent in order to show the whole extent of the optic tract.

mus, and from them the ascending fornix appears to emerge. In front of the mammillary bodies we find a bulging downward of the floor of the middle ventricle, which is called the

tuber cinereum; thus a funnel-shaped body is formed, the lumen of which is a continuation of the ventricle. At the lower, pointed end of this structure (infundibulum) the hypophysis is attached.*

The optic tracts pass in a broad curve around the infundibulum and over the pedunculi toward the pulvinar of the thalamus. Covered in on both sides by the temporal lobes, they curve upward and outward around the origin of the pedunculi to reach the corpus geniculatum laterale and the pulvinar.

Farther forward in front of the infundibulum they are united and form the chiasm from which, after the decussation of their fibres, the optic nerves arise.

In front of the optic tract, external to the chiasm, just under the anterior part of the corpus striatum, lies the substantia perforata anterior,—a grayish mass penetrated by numerous blood-vessels from the pia. In front of it is the region of the lobus olfactorius.

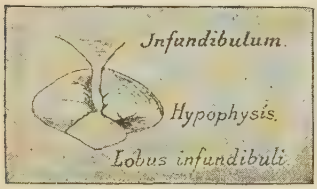

FIG. 58.

The hypophysis seen from behind. (After Schwalbe.)

The olfactory lobe, in many animals, is a large organ on the base of the fore-brain; in water mammals it is entirely wanting, while in human beings and apes it is very much atrophied.

Its anterior, bulbous extremity is called the bulbus olfactorius, and its posterior portion, which is continuous with the cortex of the frontal lobe, has received the name of tuber olfactorium. That portion which lies between the two has become atrophied to a thin pedicle,—the tractus olfactorius. The

* The hypophysis (Fig. 58), an appendix to the base of the brain, about the size of a cherry, consists, first, of a prolongation of the floor of the ventricle (lobus infundibuli), which is not positively proved to consist of nerve-substance, and, secondly, of a tuft of epithelial tubules which are firmly attached to the lobus infundibuli, and which, as you know, is derived from the mucous membrane of the pharynx. In vertebrates other than mammals this epithelial portion of the hypophysis is not attached to the lobus infundibuli at all. Later researches (Flesch, Darkschewitsch) have shown that it contains two forms of cells,—small hyaline and large, granular, nucleated cells. Inasmuch as very similar elements are found in several very active glands, it is probable that the hypophysis has some physiological function to perform.

cortex, too, which covers the whole lobe is atrophic in the olfactory tract. The fibres of the actual olfactory nerves arise from the olfactory bulb.

The olfactory-lobe cortex has numerous connections with regions of the brain which lie farther back. Some of these are plainly visible on the base of the brain. They pass over the substantia perforata, and in part penetrate it. Formerly these were thought to be real nerve-roots, but, according to our present views, it is much more probable that they are tracts which serve to connect the olfactory lobe with more central portions of the brain. The most external of these bundles can be traced into the tip of the temporal lobe. The results of physiological experiments make it probable that it terminates in the cornu ammonis. The investigations of Zuckerkandl in comparative anatomy show that these olfactory nerve-roots have their termination not only in the cornu ammonis, but probably in the cortex of the whole gyrus hippocampi and the lobus lingualis, which is associated with it.

In the olfactory nerves of the lower animals there has been demonstrated an extensive system of commissures and a chiasm between them. We only know that fibres from the anterior commissure pass into the region of the olfactory lobe. These fibres, which can be plainly seen in Fig. 41, form, as it appears, a commissure between the olfactory lobes. The other fibres of the anterior commissure connect the two lobi linguales (which are also points of origin for the olfactory nerve) with each other.

The gray lamina between the two olfactory lobes is directly continuous in front with the knee of the corpus callosum. It is called the lamina terminalis. It is the remnant of the embryonic terminal lamina,—that wall which closed the primitive fore-brain, and from which the massive hemispheres have been developed. At present it is only a small, unimportant gray area, which lies at the most anterior point of the base of the brain.

The thalami are everywhere in such close juxtaposition to the internal capsule that we very seldom see cases of disease which involve them alone. Even in these cases it is doubtful to what extent the symptoms present depend upon involvement of the neighboring fibres of the internal capsule. It is, therefore, impossible to determine the symptom-complex presented by disease of the thalami. According to Meynert the sensations of innervation of the upper extremities are injured. As a result we would have delusions as to the position of the limb, and, in consequence of these delusions, forced attitudes would be assumed. Neither motor nor sensory paralyses seem to be caused by injuries to the thalami. Injuries to sight in the form of homonymous, lateral hemianopia, and, perhaps, also of crossed amblyopia, have been repeatedly observed. In disease of the thalamus there have often been observed symptoms of hemichorea, athetosis, and tremor of one side of the body. These last symptoms, however, have also been observed in disease of other parts of the brain.

The same obstacles present themselves in attempting to define the symptoms of disease in the corpus striatum. Those symptoms, which were formerly considered as indicating disease at this point (hemiplegia, for example), may equally well be caused by disease of the neighboring internal capsule. One case of disease of the putamen is known to have run its course without giving rise to symptoms which pointed to trouble in that locality.

If an affection of the base of the brain only involves that part which lies in front of the pons, the symptoms caused by the irritation or paralysis of the nerves in that region are far more important, for diagnostic purposes, than anything else. If the pedunculi are also involved there may be associated with these symptoms motor and sensory disturbances of the extremities. A careful analysis of the symptoms, in connection with an accurate knowledge of the anatomy of the base of the brain, often leads to very clear and exact diagnosis as to the locality affected.

LECTURE VII.

THE SUBTHALAMIC REGION, THE CORPORA QUADRIGEMINA AND THE ORIGIN OF THE OPTIC NERVE.

GENTLEMEN: In the last lecture we postponed tracing the fibres of the brain downward, in order to consider the structures at the base of that organ. Let us again take up the thread of our discourse. We had learned that, in the posterior thalamic region, the bundles of the internal capsule (except so far as they were distributed to the thalamus itself, or to the subjacent ganglia) emerge free on the base of the brain and form the pes pedunculi. Caudad and ventrad of the thalamus are located the nucleus ruber and the corpus subthalamicum. From the internal capsule a bundle of the tegmental radiation passes directly caudad to these structures, while another first passes through the corpus striatum, and then enters into relation with them, after passing through the internal capsule.

Those bundles of tegmental fibres which passed through the corpus striatum may be traced in part to the body of Luys (corpus subthalamicum). Another portion of them, together with the fibres originating in the putamen and the nucleus caudatus, seem to pass into the stratum intermedium, which lies dorsad of the substantia nigra.

The fibres of the regio subthalamica should be examined anew, with the help of all available methods of investigation. Hitherto they have been examined chiefly by means of sections taken from the adult brain. (Meynert, Forel, Wernicke.) The embryological researches of Flechsig and myself had already enabled us to distinguish the tegmental fibres amidst the chaos which prevails in that region.

That bundle of tegmental fibres which passes external to

the red nucleus apparently becomes the upper lemniscus. This is clearly defined and medullated in a fœtus of seven months. At that time the thalamus contains no medullary fibres except the bundle of Vicq d'Azyr, and the internal capsule none except the tegmental radiation.

Fibres pass from the thalamus to the red nucleus, laminæ medullares thalami, while others go to the corpus subthalamicum. Between the pes pedunculi and all this mass of ganglia and fibres, which, taken together, are called the tegmentum, is situated the substantia nigra.

We now pass into the region of the mid-brain. To this region belongs (embryologically considered) that thick bundle of white fibres which passes across the ventricle at the point where it becomes the aqueduct of Sylvius; that is to say, the posterior commissure (Fig. 59). It can be more easily demonstrated in the lower vertebrates than in mammals that this commissure originates in ganglia which lie on each side, deep in the inter-brain, near the median line. But, even in mammals, Meynert has shown that its bundles are evolved from the thalamic nuclei. They then pass dorsad, reach the surface, and cross to the opposite side, in front of the corpora quadrigemina. They run horizontally only a very short distance, and then dip down into the depths of the mid-brain tegmentum, in which they pass still farther caudad. The majority of the fibres under consideration (as I have seen with peculiar distinctness in the lower animals) pass laterally and ventrad of the posterior longitudinal fasciculus, into the medulla oblongata. The last-mentioned fasciculus, which we shall study later on, only attains a considerable size after receiving these fibres from the commissura posterior. Spitzka and Darkschewitsch have seen a similar condition in mammals. According to the views of the latter, the more median of these fibres pass into the nucleus of the oculo-motor nerve. Certain it is that they pass so near to it that a part of them seem to terminate there. The fibres can be seen passing into the nucleus from the same and from the opposite half of the

brain. In Fig. 72 these fibres originate in the substantia reticularis and the posterior commissure, and this is probably the truth. In all vertebrates the posterior commissure is one of the first bundles to become medullary. Its development, from the simple cyclostoma up to human beings, is always conducted in the same way.

Under the aqueduct the structures of the tegmentum and the fibres of the pes pedunculi extend farther back. Above

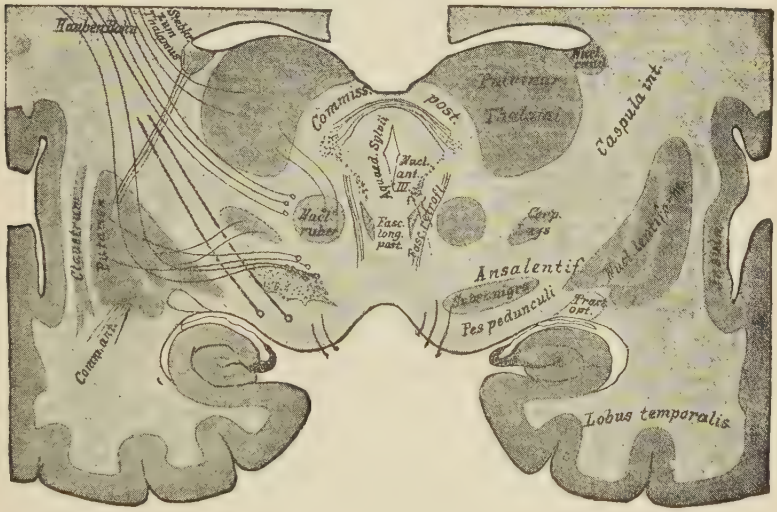

FIG. 59.

Diagram of a section through the vicinity of the posterior commissure. Shows the ganglia and the course of some of the fibres of the subthalamic region.

Hauben Bahn, Tegmental tract. *Stabkr. zum Thalamus*, Coronal fibres to the thalamus.

them lie the corpora quadrigemina developed from the roof of the mid-brain. The following cut shows the corpora quadrigemina viewed from above. They lie on the crura, and seem to be crowded in between the thalami. Ventrad of them appears, on each side, a thick strand of fibres from the depths below, which extend into the cerebellum. They are the anterior or superior peduncles of the cerebellum. In Fig. 53 you can see how they arise in the red nucleus, which is situated in the tegmentum beneath the thalamus and the corpora quadrigemina. Behind

the latter bodies it emerges from the tegmentum and lies on the surface.

We distinguish the anterior and the posterior quadrigeminal bodies. This distinction is only visible to the naked

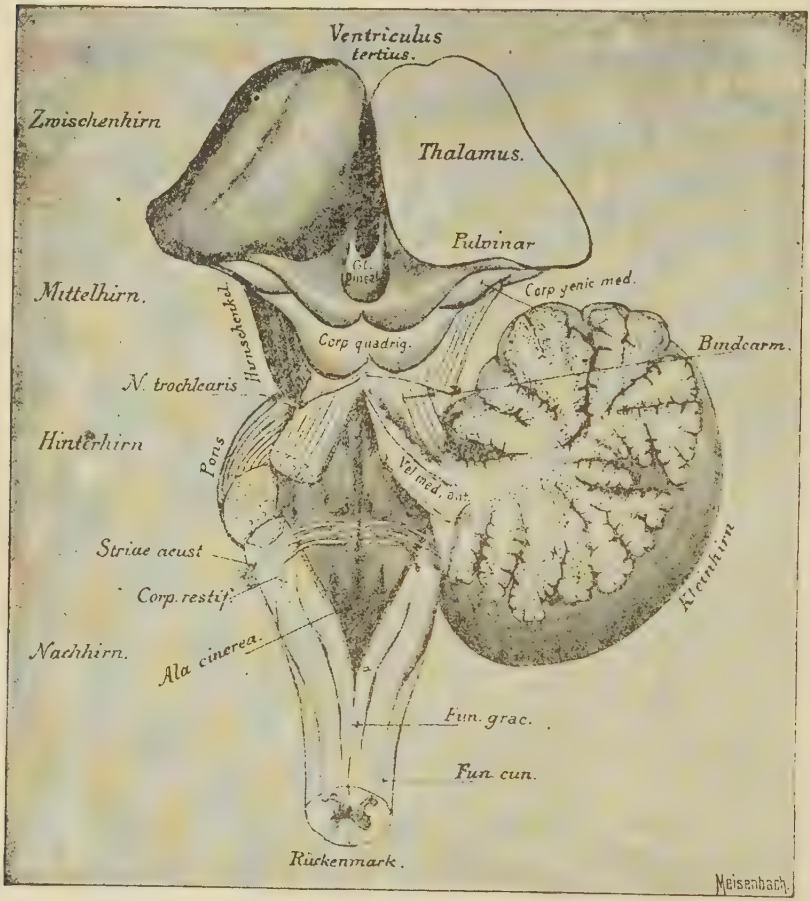

FIG. 60.

The brain-structures from the thalamus to the spinal cord. The cerebellum is divided and the left half removed.

Bindearm, Peduncle.
Hinterhirn, Hind-brain.
Hirnschenkel, Pedunc. cerebri.
Kleinhirn, Cerebellum.
Mittelhirn, Mid-brain.
Nachhirn, After-brain.
Ruckenmark, Sp. cord.
Zwischenhirn, Inter-brain.

eye in the case of some mammalians; in all other vertebrates the anterior quadrigeminal bodies are so large that the posterior ones disappear beneath them, and seem like a little ganglion

attached to the anterior pair. (Compare Lecture II, Figs. 11–17.) From the anterior quadrigeminal bodies arise a large portion of the optic nerve-fibres. They, like the thalamus, receive fibres from the region of the occipital lobe, which run in the optic radiation to the internal capsule, and from there pass upward to the thalamus in the brachium of the anterior quadri-

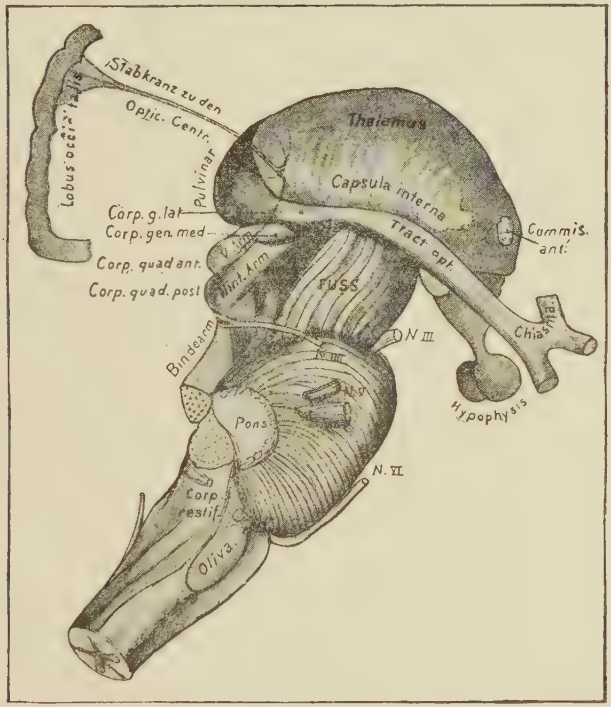

FIG. 61.

Thalamus and corpora quadrigemina seen from the side. The fore-brain has been removed at the point where the fibres of the corona radiata enter the internal capsule. The relation of the optic radiation to the posterior part of the capsule and to the optic centres is shown in diagram.

Bindearm, Peduncle. *Fuss*, Crusta. *Hint. Arm*, Post. brachium.
Stabkranz zu den Optic Centr., Coronal fibres to the optic centres.
V. Arm, Ant. brachium.

geminal body. In this brachium anterius the fibres pass downward to the optic tract. The brachium anterius, which is, therefore, composed of fibres *from* the cortex and of fibres *to* the optic tract, passes, with the fibres from the cortex only, into the corpora quadrigemina. The fibres to the optic nerve spread

over the gray surface of the quadrigeminal body (stratum zonale) and end in a fine net-work, which apparently takes its origin in the numerous delicate cells which are found in this locality.

The posterior quadrigeminal body appears also to stand in some relation with the optic tract, but it is very improbable that it contains fibres which are of any use in the visual act. Its brachium originates in the corpus geniculatum mediale and in the hitherto unmentioned commissura inferior (Gudden's commissure), which passes along with the optic tract to the posterior angle of the chiasm. (See Fig. 66.) It may also, perhaps, contain fibres from the temporal lobe. The extraordinary development of the posterior quadrigeminal body in cetaceans, and the huge bands of fibres which pass from it to the nucleus of the acoustic nerve, make it probable (Spitzka) that this ganglion stands in some relation to the sense of hearing. The results of experiments undertaken to elucidate the point seem to agree with this. After destruction of the acoustic nerve the posterior quadrigeminal body is said to become somewhat atrophied (Baginski). It seems to me, however, that this special point needs further investigation.

Viewed laterally the relations of the quadrigeminal brachia to the ganglia and the optic tract are plainly seen; also the situation of the corpora geniculata; the corpus geniculatum mediale lying close to the posterior brachium, and the corpus geniculatum laterale seeming to be thrust between the pulvinar and the optic tract. The corpus geniculatum laterale was mentioned when we were describing the thalamus. From the latter ganglion fibres pass to the optic tract aside from those which issue from the pulvinar and the stratum zonale. The optic fibres, from the anterior quadrigeminal body, have already been described. They run their course, to a great extent, in its brachium. Besides these the nerve receives roots from the region of the corpus subthalamicum, and from the gray matter in the vicinity of the infundibulum (basal optic root). Compare Fig. 66.

We have now reviewed the origin of the optic nerve as shown in dissections of the adult human brain. According to J. Stilling, there is added still another root which ascends in the pedunculus cerebri from the medulla oblongata. However, all these fibres and nuclei are so difficult to locate and follow out in the human being that we must ask ourselves the question how far these discoveries are borne out by investigations on the lower animals. Comparative anatomy furnishes us an opportunity to study optic tracts of such a comparatively huge size (in fishes and birds) that the relations of these parts can be much more easily determined. From the study of these animals, as well as of reptiles and amphibians, we can see that the optic nerve, as a whole, certainly originates in the anterior quadrigeminal body; that in its course past the lateral geniculate body it receives fibres from that ganglion; and that, finally, a basal root from the region behind the infundibulum is associated with it. Experimental researches on mammals (Gudden, Ganser, Monakow) show that the early extirpation of an eye is followed by degeneration of the anterior quadrigeminal body, of the corpus geniculatum laterale, and of fibres from the pulvinar. The pulvinar is, however, very small in most mammals, and first attains a considerable size in the primates.

We may regard it as definitely settled that the optic nerve has its origin in the anterior quadrigeminal body, the corpus geniculatum laterale, the pulvinar, the stratum zonale, and the base of the brain. The roots from the corpus geniculatum mediale, the corpus subthalamicum, and the pedunculus cerebri have not received the necessary corroboration by the various methods of investigation.

The connections between the cortex of the occipital lobe and some of the points of origin of the optic nerve have already been discovered. These connecting fibres make up the optic radiation, which passes from the occipital lobe to the most posterior part of the internal capsule, and from this point can be traced into the thalamus and the brachium of the anterior quadrigeminal body. It is shown in Fig. 44. Its fibres, however, do not end as there represented, in the lateral portions of the occipital lobe, but trending toward the median line, in planes which lie outside of this section, extend as far as the cuneus. In destructive disease of the occipital lobe and of the posterior part of the internal capsule the same symptoms appear as in similar lesions of the optic tract on the same side. The outer half of the retina of the eye on the injured side and the inner half of the retina of the opposite eye degenerate.

Let us, now that we have learned something concerning the region of the corpora quadrigemina, take up the study of a section made perhaps 5 millimetres behind the structures shown in Fig. 59. This section divides the two pairs of quadrigeminal bodies, passes through the underlying tegmentum, and lastly through the pedunculus cerebri.

Let us first study those structures which we have already

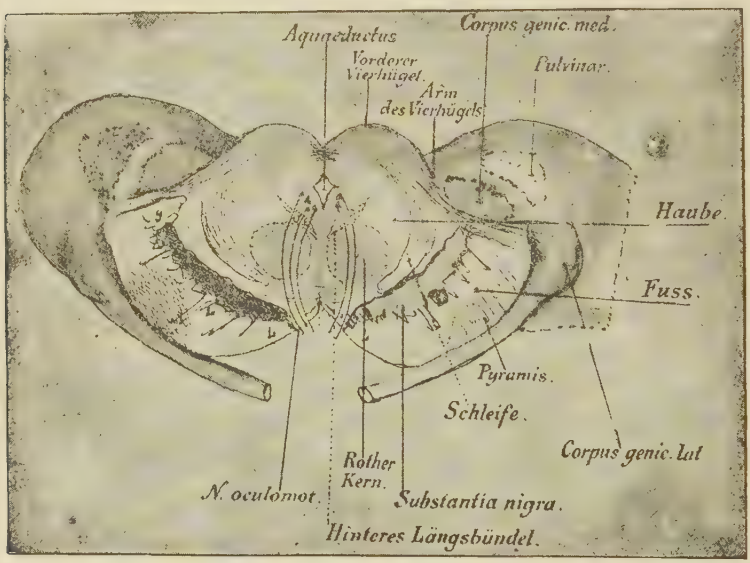

FIG. 62.

Cross-section through the anterior quadrigeminal bodies (somewhat diagrammatic).

Arm des Vierhügels, Brachium of corpus quadrigeminum.
Haube, Tegmentum. *Hinteres Längsbündel*, Post. longitud. fasciculus. *Fuss*, Crusta.
Pyramis, Pyramid. *Rother Kern*, Red nucleus. *Schleife*, Fillet.
Vorderer Vierhügel, Anterior quadrigeminal body.

met with. Externally on each side is the pulvinar thalami, from which the optic nerve seems to arise, the corpus geniculatum laterale, as it were, inserted into its course. It receives a thick auxiliary bundle from the brachium of the anterior quadrigeminal body (shown most clearly on the left), above which you will recognize the corpus geniculatum mediale, which has been cut into by the section.

Below the pulvinar arises the pedunculus cerebri. At this

point it contains the following tracts: 1. The fibres from the motor region of the cortex, which we have learned to know as the pyramidal tract in both the corona radiata and the internal capsule. They lie near the middle and are slightly shaded in the cut. 2. The fibres from the frontal lobe to the pons, situated internal to the pyramidal tract. 3. The fibres from the occipital lobe to the pons. They are situated external to the pyramidal tract. Above these three divisions of the pes pedunculi, of which the first mentioned earliest receives a medullary covering, are found fibres apparently from the corpus striatum, which are not designated in the cut (compare Fig. 50),—Meynert's stratum intermedium,—and then comes the substantia nigra, an aggregation of fine nerve-fibres and ganglion-cells whose significance is wholly unknown. External to this (*g*, in Fig. 62) lies another little ganglion, which, so far as I know, has never been described.

FIG. 63.

Commencement of the pons in a newborn child. Hæmatoxylin staining. Decussation of the cerebellar peduncles.

In the tegmentum you will at once notice the two large, round, gray bodies; they are the red nuclei (compare Fig. 59); the corpus subthalamicum, which is shown near it in Fig. 54, has disappeared when we reach this level.

The red nucleus, which receives fibres from the thalamus (and tegmental radiation?), is, at this point, *i.e.*, under the corpora quadrigemina, very rich in medullary fibres. These pass under the posterior quadrigeminal body toward the middle line, and decussate with the fibres of the opposite side. They belong to the superior peduncles of the cerebellum. The decussation is called the decussation of the superior cerebellar peduncles. It is shown in Fig. 63. Farther back the crossed cerebellar pedunculi develop into thick bundles of fibres, which lie external to the red nucleus; they gradually attain a still more external

position, and finally reach the surface. From here they pass backward to the cerebellum, as is shown in Fig. 60.

A section made almost horizontally through the thalamus, the corpora quadrigemina, and the cerebellum, following the course of the superior cerebellar peduncles, would give us the relations between the thalamus, the nucleus ruber, tegmental

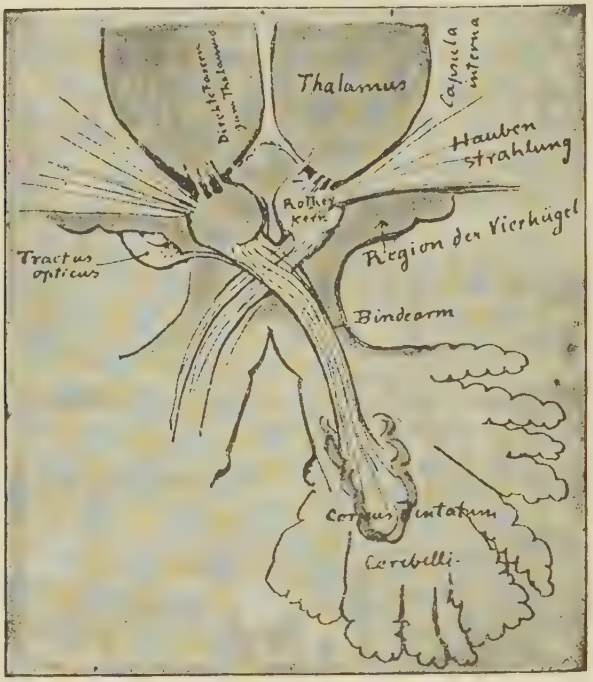

FIG. 64.

A diagrammatic horizontal section through the decussation of the anterior cerebellar peduncles and its vicinity. The tract of fibres to the optic nerve is doubtful.

Bindearm, Peduncle.
Direkte Fasern zum Thalamus, Direct fibres to thalamus.
Region der Vierhügel, Quadrigeminal region.
Hauben Strahlung, Tegmental radiation.
Rothen Kern, Red nucleus.

striation, pedunculus cerebelli superior, and the cerebellum, somewhat as they are depicted in Fig. 65.

In the cerebellum the superior peduncles enter the corpus dentatum.

External to the red nucleus there is shown in Fig. 62 a bundle of fibres which appear to emerge from under the corpora

quadrigemina, and which have been cut off obliquely. They pass backward in the region over the substantia nigra. These fibres arise in great part from the ganglia of the corpora quadrigemina. They are called the lower fillet. The upper fillet, which arises mainly from the tegmental striation, or, rather, from the ansa lenticularis, lies, at the level which we are now considering, just outside of and below the red nucleus, and appears as a separate bundle of transversely divided fibres. To

FIG. 65.

A frontal section made in an oblique direction trending downward and backward (direction of section shown in small figure). It contains the greater part of the origin of the mid-brain fillet. Hæmatoxylin stain.

Centr. Höhlengrau, Central gray matter.
Schleifenschicht des Pons, Stratum lemnisci of the pons.
Schnittrichtung, Plane of section.
Tiefes Mark, Deep marrow.

the inner and outer sides of it the fibres of the lower fillet are joined to it. Thus it comes that there is a wide area of transversely divided fibres just above the substantia nigra, and this is called the layer of the fillet (stratum lemnisci).

The greater part of the layer of the fillet can be traced caudad to the nuclei of the sensory nerves and of the posterior column. Meynert first showed that this was a portion of the sensory tract. Embryology and comparative anatomy equally bear out this view. We shall study the course of the fillet later.

The stratum lemnisci, then, contains two elements,—the upper and the lower fillets. The lower (better, mid-brain) fillet arises chiefly from a system of fibres which has not been mentioned before, the deep marrow of the roof of the mid-brain ; but it also arises in part from the ganglion of the posterior quadrigeminal body. This is clearly shown in an oblique section downward through both pairs of quadrigeminal bodies, as represented in Fig. 65. The ganglion above mentioned consists of a large, roundish nucleus permeated by a net-work of fine fibres. This is the only ganglion situated in the posterior quadrigeminal body ; the latter, therefore, does not present that stratified appearance, alternately gray and white, which is characteristic of the anterior quadrigeminal body,—the ganglion opticum. It is connected with its fellow of the opposite side by the fibres running over the aqueduct of Sylvius.

Phylogenetically the deep marrow is a very old system. It is present even in the simple brains of the lower vertebrates, and in these, as in the human being, early receives its medullary sheaths. Its fibres arise in the roof of the mid-brain, springing from layers which lie beneath the origin of the optic nerve. From this point they at first radiate inward, but, on reaching the central gray matter, they turn and run ventrad. The most lateral of these fibres, united with those which come from the opposite side, pass into the lemniscus ; the more median fibres, however, pass down around the aqueduct of Sylvius and decussate with the analogous fibres of the opposite side. In human beings the termination of these fibres has not yet been made clear. We call them by the name proposed by Forel, the "fountain-like" decussation of the tegmentum (Figs. 66, 70, 72). In fishes and birds these particular fibres of the deep marrow are so extensively developed that their course is much more readily recognizable. In them, as well as in amphibians and reptiles, we see that, except so far as they pass into the fillet, this system of fibres is contained wholly in the mid-brain and terminate in cells situated both on the same and on the opposite

sides. In human beings we find groups of cells at points corresponding to these terminal cells of birds, fishes, etc. (lateral and median ganglion, Fig. 66).

In the central gray matter, under the corpora quadrigemina, we first meet with ganglion-cells which give origin to a cranial nerve,—the oculo-motor. From their union, which forms the oculo-motor nucleus, the roots of that nerve pass ventrad through the tegmentum and the crusta to the anterior surface of the brain, and emerge in thick bundles. (See Fig. 72.) The

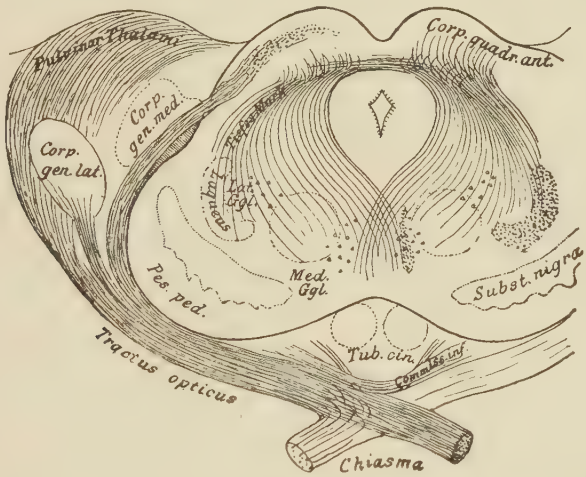

FIG. 66.

The fibres arising in the mid-brain roof. Dorsad the optic tract, ventrad the deep marrow. The diagram also shows the other optic roots.

oculo-motor nerve contains fibres to several internal and external muscles of the eye. From the fact that nuclear paralyses of single muscles from the group supplied by this nerve have been observed, it is probable that this nucleus consists of a complex of small nuclei somewhat separated from each other. In human beings, indeed, a distinct demarcation can be made out in several parts. Far forward, lying partly in the lateral wall of the third ventricle on each side, is a small nucleus,—the nucleus anterior. It sends a few fibres caudad to the main portion of the nerve. Behind it lies the nucleus posterior. It extends the whole

length of the aqueduct of Sylvius, and is composed of large multipolar ganglion-cells. In this nucleus we observe a certain tendency in the cells to become separated into groups. One collection of cells lying dorsad of the rest is plainly distinguishable. While all the other oculo-motor fibres emerge from the side on which they originate, the fibres from this group of cells, as was first shown by Gudden, pass in a median direction and decussate with those from the corresponding group on the opposite side. Besides this dorsal group a median group can be distinguished, just in the middle line, which gives off fibres on each side.

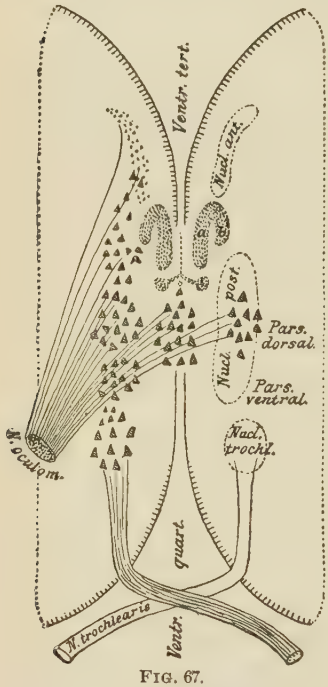

FIG. 67.
The floor of the aqueduct of Sylvius looking upward. The nuclei of the oculo-motor and trochlear nerves. (Partly diagrammatic.)

Fig. 67 represents, partly in diagram, the nuclei in the floor of the aqueduct and their relations to the nerve-roots. You will notice in the cut two small nuclei situated one on each side of the median line, and connected with each other anteriorly and below. They are marked *a* and *b*. These two nuclei, which were first observed by myself in fœtal brains, and later by Westphal, during a painstaking examination of the adult brain, lie in a thick net-work of nerve-fibres. It is not yet known whether they stand in any relation to the oculo-motor, and, if they do, what the relation is. We possess such an array of clinical facts and discoveries made by careful post-mortem dissections that we may venture to designate the particular spot in the nucleus which supplies each individual ocular muscle.

I will give you Starr's table, the latest result of these researches which were so happily begun by Kahler. According

to this table, the nuclei of the individual muscles are arranged in the order given below, from before backward, thus:—

Sphincter iridis.	Musculus ciliaris.	Middle line.
Levator palp.	Rectus int.	
Rectus sup.	Rectus inf.	
Obliquus inf.		

The nerves to the internal muscles of the eye apparently spring from the anterior nucleus. The crossed track and, perhaps, also the median division of the posterior nucleus are accredited to the rectus internus. Although clinical experience teaches that there is both a direct and a crossed communication between the oculo-motor nerve and the centres of the optic nerve, yet the anatomical basis of this fact has not been discovered. Net-works and bundles of fibres which *might* complete the communication are to be found in this region. As yet, however, no *experimentum crucis* has been performed, nor has there been made any clinical observation supported by post-mortem examination which would clear up this point.

The nucleus of the oculo-motor lies ventrad of the aqueduct of Sylvius; that is to say, in its floor. Later on, as we pass gradually backward in our study of the tegmentum, we shall find the nuclei of most of the other cranial nerves in the region of this floor.

The cranial nerves all arise directly from their nuclei. To each of these nuclei fibres pass from higher parts of the brain. They come from the opposite side and decussate in the middle line before entering the nucleus. Clinical experience goes to show that the upper part of the cranial-nerve tracts—that is, above the nucleus—extends to the cerebral cortex.

The course of the fibres in the vicinity of the thalamus and in the regio subthalamica is less certainly known than in most other parts of the brain. Among the workers in this difficult field, Meynert, Forel, Gudden, Flechsig, Wernicke, and the author are to be mentioned.

The origin of the optic nerve has been principally worked out by Meynert, J. Stilling, Tartuferi, Gudden, Bellonci, and Monakow.

You will, gentlemen, have a better comprehension of many pathological nervous phenomena if you will, for the time, adopt

the following diagram of an innervation tract. Every peripheral nerve—at least, every motor nerve—ends in the central organ in a nucleus. Nerve-roots and the nucleus form the first part of the tract. To the nucleus there pass fibres of the corona radiata from the cortex of the hemispheres, and thus is formed the second link in the chain: nerve, nucleus—corona radiata, cortex.

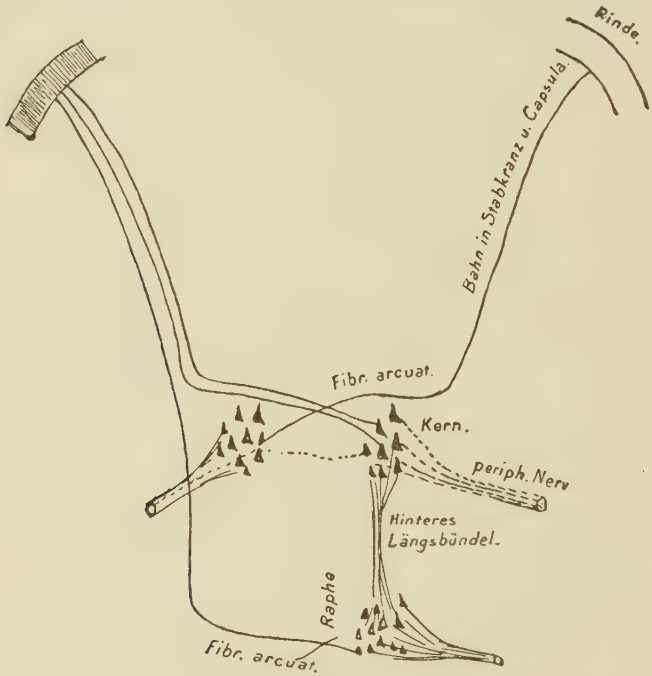

FIG. 68.

Diagram of an innervation tract from the cortex to a (motor) cranial nerve.

Bahn in Stabkranz u. Capsula, Tract in corona radiata and capsule. *Hinteres Längsbündel*, Post. longitud. fasciculus. *Kern*, Nucleus. *Periph. Nerv*, Peripheral nerve. *Rinde*, Cortex.

So long as the first part of the tract is intact, the muscles can be brought into action by electric, mechanical, or reflex irritation, and, in animals, to a certain extent by the influence of the will. If either nerve or nucleus is destroyed we have absolute paralysis. In order, however, to obtain the full effect of a conscious voluntary act, the second part of the tract must also be intact; this is particularly true of the highly-developed human

brain, for, if the second part is interrupted, there can no longer be a voluntary motion of any kind. In a case of apoplectic rupture of the internal capsule the muscles of the opposite side of the body are not really paralyzed; they simply cannot be made to contract by the will. This, however, can readily be accomplished by other forms of stimulation. It is otherwise in a case, for instance, of infantile paralysis, where a nerve-nucleus itself is destroyed. In this case we have a true paralysis, generally irremediable, which leads to atrophy, and the muscles

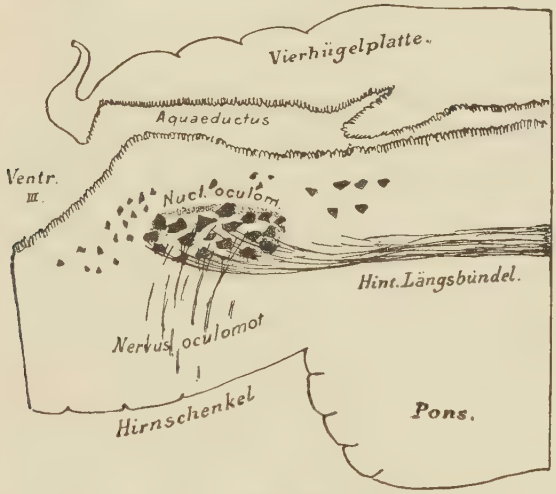

FIG. 69.

Longitudinal section through the quadrigeminal region of a human embryo of 28 weeks, near the median line. The outer wall of the aqueduct of Sylvius has been cut into. Termination of the fasciculus longitudinalis posterior in the nucleus of the oculomotor. All medullary fibres stained with hæmatoxylin.

Hint. Längsbündel, Posterior longitudinal fasciculus. *Hirnschenkel*, Pedunculus cerebri. *Vierhügelplatte*, Quadrigeminal lamina.

respond very little, if at all, to reflex or any other stimulation. It makes a great difference, so far as the prospect of a restoration of function is concerned, whether the cerebral or the deeper portion of the innervation tract is affected.

The diagram Fig. 68 is an attempt to represent the most important fibres passing to the nucleus of a cranial nerve. Besides the above-described central tract, the nucleus, and the peripheral tract, you will notice fibres connecting the nerve-nucleus with deeper-lying nuclei of other nerves, and, in addition to these, still other fibres arising from the nucleus, but emerging from the central organ in the nerve of the opposite side.

In the beginning of to-day's lecture you learned that certain fibres of the posterior commissure curved backward. These fibres, together with others which arise in the depths of the inter-brain, are met with as a fine fasciculus ventrad of the anterior oculo-motor nucleus. As we pass back, this fasciculus progressively increases in size. There are added to it numerous fibres from the nucleus of the oculo-motor. We shall, from now on, meet with the triangular cross-section of this bundle, which is composed of fibres from such various regions on every transverse section of the brain, from the level of the corpora quadrigemina down to the beginning of the spinal cord. This bundle is called the fasciculus longitudinalis posterior. Inasmuch as fibres are given off along the whole course of this bundle to the nerve-nuclei, as can be plainly seen in embryos of the sixth to seventh month, when few other fibres are medullated, and, as this bundle projects farther back than the nucleus of the abducens, it is probable that the fasciculus longitudinalis posterior not only contains the fibres of communication between the nuclei of the ocular muscles, but that it also contains fibres to other cranial nerves. Flechsig is also of this opinion. I have never succeeded in tracing this fasciculus farther than the nucleus of the oculo-motor previous to the ninth month. Series of longitudinal sections stained with hæmatoxylin (one of which is represented on preceding page) are decisive. Not all fibres of the fasciculus longitudinalis posterior receive their medullary substance at the same time.

In the neighborhood of the posterior quadrigeminal body there is an interchange of fibres between the two fasciculi longitudinales posteriores. By this means there is established a communication between the oculo-motor and the trochlear on one side and the opposite abducens.

The numerous systems of fibres which run their course in the region of the corpora quadrigemina can only be differentiated by studying the development of their medullary sheaths. I should therefore dislike extremely, gentlemen, to close these

lectures without demonstrating to you a specimen which has a bearing upon this subject.

In Fig. 70 we have a section through the anterior quadrigeminal body, close to the posterior commissure, from a child born during the ninth fœtal month. Every one of the fibres which are medullary at this period is stained black by hæmatoxylin.

You will easily make out the features which we have just described. Here your attention is, for the first time, called to a

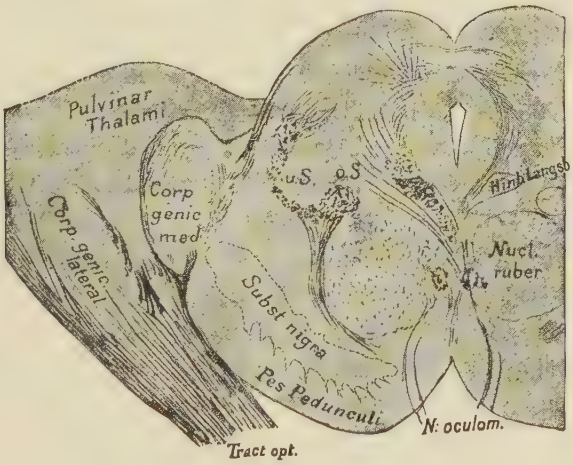

FIG. 70.

Frontal section through the anterior quadrigeminal body of a 9 months' fœtus.

Hint. Langsb., Posterior longitudinal fasciculus. *O. S.*, Upper fillet. *U. S.*, Lower fillet.

little circular bundle of transversely divided fibres lying between the red nuclei, and marked *b*. It arises in the ganglion habenulæ and passes backward to a small ganglion which lies between the crura cerebri, and is called the ganglion interpedunculare. In that situation the fibres decussate with those of the opposite bundle before entering the ganglion. This bundle is called the fasciculus retroflexus, or Meynert's bundle. Its course is shown in Fig. 71. Compare also Fig. 59.

You see in Fig. 70 a mass of fibres belonging to the lemniscus and passing around outside the red nucleus to the region over the substantia nigra. In the crusta there is at the ninth

month only one small fasciculus, which has become medullary. It lies externally, and is not shown in the cut. It emerges probably from the ansa lenticularis.

In Fig. 72 we have a picture which represents most of the structures which can be seen in a section just behind the anterior quadrigeminal body. This cut is prepared from specimens at various periods of development. We will make use of it for a review of to-day's lecture, and look up the following important points:—

1. Roof of mid-brain: Anterior quadrigeminal body; from

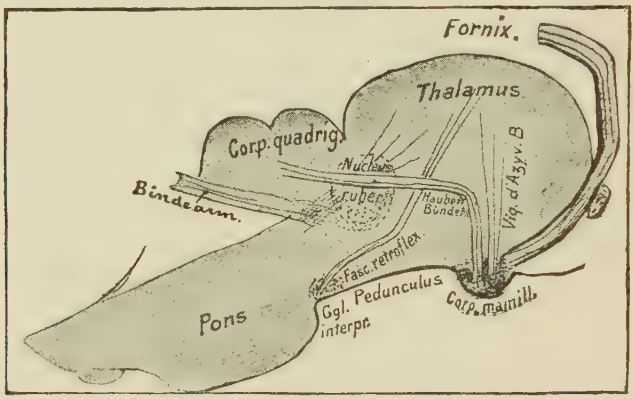

FIG. 71.

Diagram of a sagittal section through the thalamus and the corpora quadrigemina.

Bindearm, Sup. cerebellar pedunc. *Haubenbündel*, Tegmental fasciculus. *Viq. d'Azyr. B.*, Viq. d'Azyr's bundle.

this there arises dorsad the brachium to the optic nerve, ventrad the deep marrow, the decussation of the latter over the aqueduct, the central gray matter surrounding the aqueduct. On the outer border of the central gray matter a small nucleus, unmentioned before, whose vesicular cells will be found in the same relative position throughout the entire mid-brain. From it arises a slender bundle of fibres which, progressively increasing in size, passes downward to the pons and there associates itself with the emerging fibres of the trigeminus. It is the descending root of the fifth nerve.

2. Tegmentum: In the ventral portion of the central gray

matter the nucleus, posterior medialis, and lateralis of the oculomotor; to it are added fibres from the deep marrow and from the fasciculus longitudinalis posterior; external to and continuous with the latter the fibres of the posterior commissure. Ex-

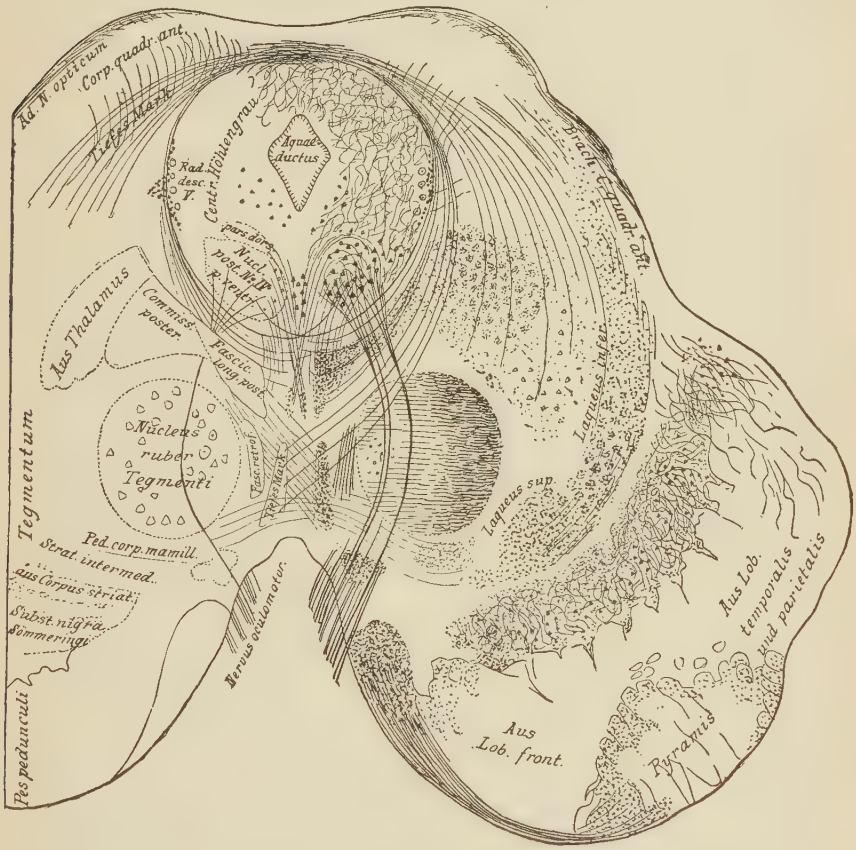

FIG. 72.

Section just back of the anterior quadrigeminal body, combined from specimens at different stages of medullary development. Hæmatoxylin staining.

Aus Corpus striat., From the corpus striatum.
Aus Lob. temporalis und parietalis, From the temporal and parietal lobes.
Aus Lob. front., From the frontal lobe.
Aus Thalamus, From the thalamus.
Centr. Höhlengrau, Central (ventricular) gray matter.
Tiefes Mark, Deep marrow.

ternal to this a medullary tract, which apparently extends hither from the thalamus, from which it took its departure in the form of the laminæ medullares. The fillet from the corpora quadrigemina, and that from the tegmental radiation; internal to

the fillet is the nucleus ruber tegmenti, from which the numerous fibres of the superior cerebellar peduncles arise. Near the median line is that decussation of the fibres of the deep marrow which has been named the "fountain-like" decussation of the tegmentum. Between the latter and the pedunculus superior cerebelli is seen a portion of the descending fasciculus retroflexus. Fig. 71 shows how it reached this region.

3. On the boundary between the crusta and the tegmentum we recognize the substantia nigra Sömmeringi, in which run many fibres,—stratum intermedium,—which arises in the lenticular nucleus.

4. Pes pedunculi: The pyramidal tract is shown still non-medullary, as it appeared in the specimen from a 4-week-old child. The fibres lying internal to it come from the frontal lobe; those on its outer side from the parietal lobe. At about this level one bundle leaves the pyramids, and, passing along the border of the pes, becomes associated farther back with the fillet, and forming the most median layer of that fasciculus. Spitzka has shown that most probably this bundle contains the cerebral tracts of the cranial nerves. Internal to it, in the cut, emerge the roots of the oculo-motor nerves. Shortly before their exit they pass through the pedunculus corporis mamillaris.

We have now only to mention those symptoms which may with reasonable certainty be taken as indicating disease in the region of the corpora quadrigemina.

Lesions in the regio subthalamica involve such a tangle of different sorts of fibres that their symptoms are of the most manifold description. A certain diagnosis can hardly be made. Foci in the vicinity of the pes pedunculi involve the motor fibres to the opposite side of the body and the neighboring cranial nerves. Sensory and vasomotor disturbances may also be present. Generally, not only the muscles of the extremities and one or more of the cranial nerves are paralyzed, but there are also present disturbances of the oculo-motor nerve of the side of the lesion. If there is a simultaneous paralysis of one oculo-motor

nerve and of the opposite half of the body we may suspect trouble under the corpora quadrigemina. Such patients have either wholly or in part lost control of the limbs on one side of the body, the upper lid droops, the pupil is dilated, and the whole eye turned outward by the rectus externus. The same symptoms might come from a tumor at the base of the brain, as is evident from Fig. 57. It is, therefore, important for diagnostic purposes to know whether the ocular paralysis appeared simultaneously with the paralysis of the extremities,—a condition of things which could only very rarely occur in the case of a tumor at the basis cerebri. If anæsthesia appear, it is only present in the side opposite the disease. The sensory fibres run to a great extent in the lemniscus.

If a disease-centre extend farther dorsad and involve the corpora quadrigemina themselves, there appear, as may be easily understood from a glance at our cross-section, paralyses of the oculo-motor, which may involve either one or both nerves. In disease of the anterior quadrigeminal body there is amaurosis; in some cases the ophthalmoscope reveals absolutely nothing. In tumors, of course, as in tumors in other regions of the brain, we may have choked disk, atrophy of the optic nerve, etc. Generally, the pupil does not react either way. We do not know what symptoms are caused by disease of the posterior quadrigeminal body. Disturbances of equilibrium and co-ordination have been observed in such cases.

We shall most strongly suspect disease of the corpora quadrigemina if, in cases of paralysis of the oculo-motor, we can exclude peripheral causes (on the base of the brain), or when only a part of the oculo-motor (for instance, the fibres to the internal muscles of the eye) is injured. In affections of a peripheral origin this would be impossible; such paralyses are nuclear.

LECTURE VIII.

THE PONS AND THE CEREBELLUM.

GENTLEMEN: We learned in the last lecture that the bundles of fibres from the fore- and inter- brains arranged themselves into two layers in the region of the mid-brain. These layers were called the crusta or pes pedunculi and the tegmentum. Back of the corpora quadrigemina the aqueduct becomes markedly broader. Both pes and tegmentum pass under it and farther back into the hind-brain. Only one division of the tegmentum, the anterior peduncles of the cerebellum, arising in the red nucleus, now passes dorsad from the floor of the mid-brain to the roof of the hind-brain. From this roof has been developed the cerebellum in adults. The space lying under it, the continuation of the aqueduct, is called the ventriculus quartus. The prolongations of the crusta and tegmentum are contained in the floor and lateral portions of the hind-brain.

Let us first see what becomes of the fibres of the pes. Not far back of the corpora quadrigemina a thick mass of white fibres is laid across the crusta. Arising from the cerebellum, they pass down, surround, and cover the region of the pes in a thick layer. Taken together, these fibres are called the pons.

Only a portion of these fibres cover in the surface of the crusta (stratum superficiale pontis); the majority of them dip in between the fibres of the latter, and divide them into isolated bands (stratum complexum et profundum pontis).

You will remember that of the fibres which pass downward from the brain in the crusta a part could only be traced as far as the pons. They were the fasciculi from the frontal, parietal, and temporal lobes. The pyramidal tract from the central convolutions passes through and below the pons. Almost the

whole inner and the whole outer third of the pes go no farther than the pons. Below this point only the fibres of the middle third, the pyramidal tract, appear. The accompanying figure shows this and gives a front view of the pons, together with the crura cerebri and the cerebellum. The pyramidal tract is shaded dark.

Fig. 74 shows in diagram the arrangement and course of fibres in a section through the pons. The fasciculi come from above on each side, out of the cerebellum, surround and pene-

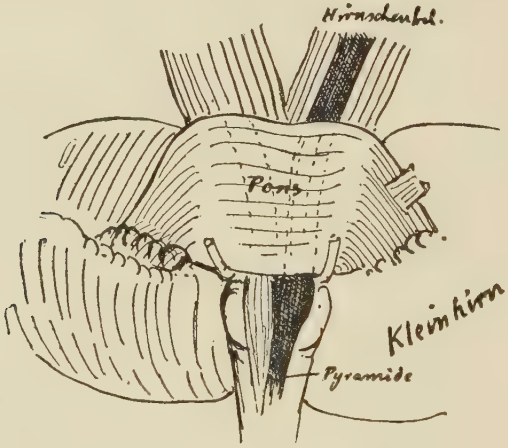

FIG. 73.

The pedunculus cerebri and the pons seen from in front. That tract of the crusta which does not terminate in the pons is shaded dark.

Hirnschenkel, Pedunculus cerebri. *Kleinhirn*, Cerebellum. *Pyramide*, Pyramid.

trate the fibres of the pes, and, crossing over to the opposite side, are associated with the longitudinal bundles of the latter. It is pretty well established that they are connected with a good share of the fibres of the pes and serve to establish a communication between them and the cerebellum. How this is effected is not known. Numerous ganglion-cells lie among the fibres of the pons. These are caught in a fine net-work of medullary fibres, and to this net-work only can the fibres of the pes be traced on the one hand, and the fibres of the pons on the other.

This much is certain, that bundles arise from the region of

the pons which pass at right angles to those of the crusta over to the opposite cerebellar hemisphere.

Aside from this it is not certain, and not even probable, that all the fibres of the pons are to be regarded merely as continuations of the cerebral fibres. The arms of the pons (brachia pontis) contain more fibres than are conveyed to it by the crusta. Moreover, many of them acquire medullary sheaths at a time

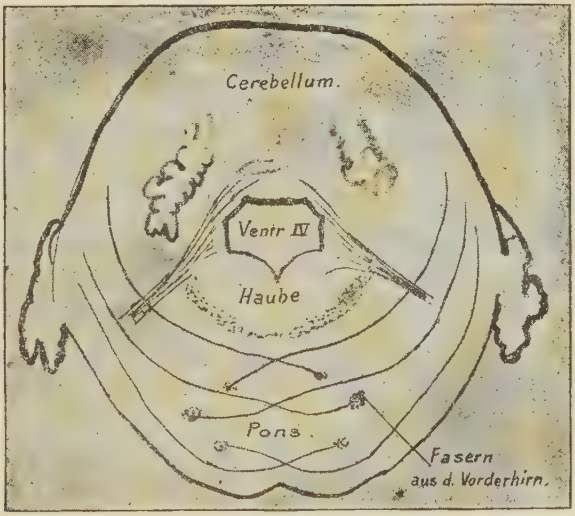

FIG. 74.

Diagram of a section through the pons and cerebellum.
Haube, Tegmentum. *Fasern aus d. Vorderhirn*, Fibres from the fore-brain.

when no single fibre of the crusta is so enveloped. This condition I have seen in cats.

Although the pes pedunculi is pierced through and through by the fibres of the pons, and in part diverted into the cerebellum, yet the tegmentum is continued through the region of the pons with very little change. In the last section through the quadrigeminal region we distinguish the following as the principal structures of the tegmentum (compare Fig. 62):—

1. The gray substance around the aqueduct, together with its nerve-nuclei.

2. Below it the fasciculus longitudinalis posterior, and external to this—

3. The fibres of the posterior commissure.

4. The fibres from the striæ medullares thalami.

5. The red nuclei in the midst of the tegmentum, and springing from them the superior or anterior cerebellar peduncles.

6. The lemniscus.

7. The pedunculus corporis mamillaris.

8. Fibres from the deep marrow near the median line.

9. Fibres from the stratum intermedium.

Before reaching the region of the pons, the red nucleus begins to diminish in size, the anterior cerebellar peduncles arising from them pass more and more toward the periphery, and here form two thick, white strands, which lie between the region of the red nucleus and the fillet. In Fig. 75 we see the first traces of them at *B*, and in sections made a little farther back, but which still pass through the corpora quadrigemina, they are already found somewhat farther toward the periphery (Fig. 76). In Fig. 77, which represents a section through the velum medullare posticum, they form the outside margin of the cut. Soon after this they pass into the cerebellum.

FIG. 75.

Commencement of the pons and the decussation of the cerebellar peduncles. *B*, anterior cerebellar peduncles; *L*, fillet of a newborn child. The medullary fibres of the tegmentum are stained with hæmatoxylin.

The region which is left unoccupied by the disappearance of the red nucleus is filled in by the increasing fibres of the substantia reticularis, which we shall study later on.

The aqueduct, as before stated, becomes expanded into the fossa rhomboidalis. The gray matter surrounding it also increases in area. A new nerve-nucleus, that of the nervus trochlearis, is met with in this region. Its fibres, however, do

not, like those of the oculo-motor, pass backward through the tegmentum. They run directly caudad from their point of origin, then turn upward and decussate with the corresponding fibres of the opposite side in the velum medullare anticum. Thus they emerge from the brain on its dorsal aspect, just behind the corpora quadrigemina. Portions of the course of the trochlear fibres are shown in Figs. 76 and 77. According to J. Stilling, the nerve also receives a rootlet from the cerebellum. The whole course of the nerve, as obtained from dissections, is shown in Fig. 67. Oculo-motor fibres are no longer given off

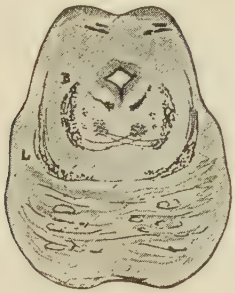

FIG. 76.

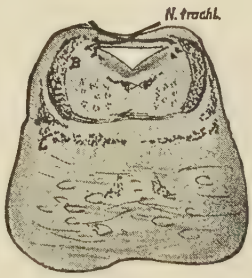

FIG. 77.

(From a newborn child. Hæmatoxylin stain.)

FIG. 76.—Section through the ending of the corpora quadrigemina. The decussation of the cerebellar peduncles almost completed, the red nucleus very small. Fibres of the trochlear nerve to be seen above.

FIG. 77.—Section through the velum medullare anticum, in which can be seen the trochlear nerve. The red nucleus has disappeared, the cerebellar peduncles lie almost at the periphery. The substantia reticularis occupies the situation formerly held by the red nucleus. In the pons is a little fasciculus of medullary fibres. All the rest of the fibres of the crusta are non-medullary, and are only shown in outline.

at this level. The posterior longitudinal fasciculus and the stratum lemnisci, however, are continued down to this level. They still occupy the same relative positions which they did in the quadrigeminal region, as may be seen by comparing Figs. 72, 75, 76, and 77. In sections through the commencement of the pons the substantia nigra has disappeared from view. Thus it comes that the layer of the fillet is no longer separated from the pes, but lies directly upon it.

If we have once formed a clear idea of the different structures to be seen in a good section through the quadrigeminal region, we shall have no difficulty in recognizing and locating

them in a section through the upper part of the pons. The main points of difference are the changed position of the cerebellar peduncles and the altered shape of the gray matter under the broadening aqueduct, where new nerve-nuclei now appear.

In sections lower down, however, the whole appearance of things is changed. This comes from the fact that the roof of the ventricle, caudad of the velum medullare anticum, is developed into the cerebellum, and that fibres from both the tegmentum and the crusta enter into intimate association with the latter.

The anterior peduncles and the fibres of the pons disappear into the cerebellum. From the medulla oblongata and the spinal cord below come fibres which are first interwoven with the tegmentum and then pass to the cerebellum.

It is, therefore, better for us to abandon temporarily the study of the tegmental fibres at this point, just behind the corpora quadrigemina, and to turn our attention to other parts of the central nervous system, whose processes and prolongations all meet just here. You will, unquestionably, be better prepared to understand a section through the tegmentum after you have learned the arrangement of fibres in the cerebellum, and have obtained an insight into the structure of the medulla oblongata and the spinal cord.

The cerebellum consists of a median portion, or "worm" (vermis), and the two hemispheres. It is connected with the inter-brain by its anterior peduncles from the red nuclei, with the fore-brain through the brachia pontis,—median peduncles. Through the former it receives fibres from the thalamus and the region of the tegmental radiation, through the latter fibres from the cortex of the frontal, parietal, and temporal lobes. A third connection is effected through the posterior peduncles (corpora restiformia, which we shall consider later), with the medulla oblongata and the spinal cord. In the accompanying figure, which shows the cerebellum as seen from above, we observe—

1. The situation with respect to the corpora quadrigemina, from beneath which the anterior peduncles pass to the cerebellum.

2. The general form of the organ, the vermis in the middle and the hemispheres on each side. Both vermis and hemispheres are divided into several good-sized lobes. Those of the vermis are arranged around the central white substance like the fans of a steam-ship's screw. (This is shown in Fig. 81, which represents a sagittal section through the middle of the vermis.)

The vermis is connected on each side with the white substance of the hemispheres, which is divided into lobes by deep

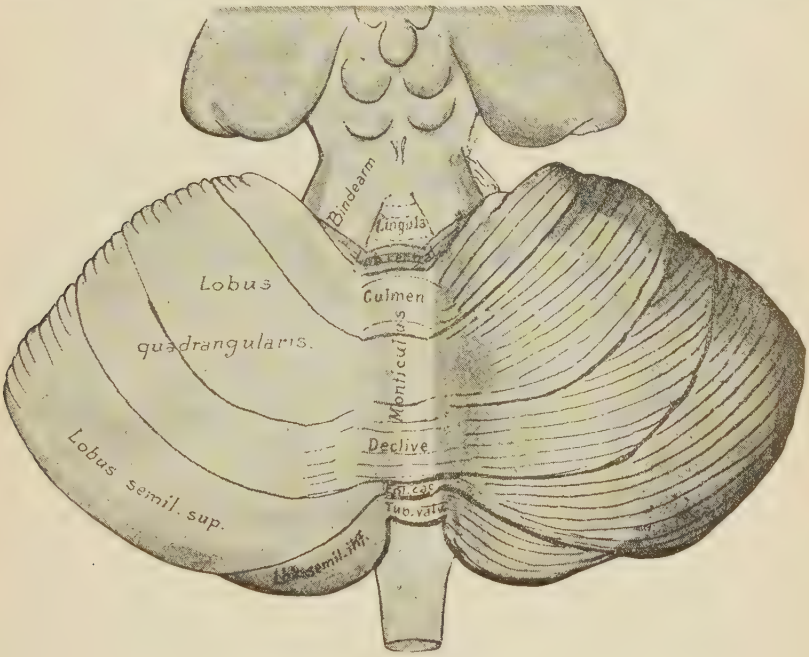

FIG. 78.
The cerebellum. Dorsal surface.
Bindearm, Anterior cerebellar peduncles.

fissures, and into ridges by shallow ones. The dorsal surface of the vermis is called the superior vermiform process. It is divided into—

1. The lingula, far forward between the anterior peduncles.

2. The lobulus centralis (central lobe). This passes over into the alæ lobuli centralis on each side.

3. The monticulus, of which we call the anterior portion the culmen and the posterior portion the declivity.

4. The folium cacuminis, at the posterior extremity of the vermis.

On the dorsal surface of the hemispheres we can distinguish:

1. The anterior upper lobe, also called the lobus quadrangularis, on each side of the monticulus. In front of it are the alæ lobuli centralis.

2. The posterior upper lobe (lobus semilunaris superior). Both posterior upper lobes are connected by the folium cacuminis. The following cut shows the lobes of the under surface of the cerebellum. It presents a somewhat complicated appearance.

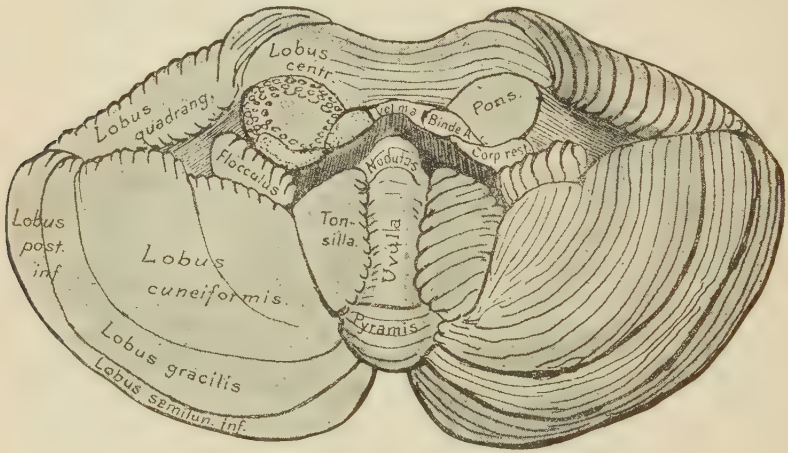

FIG. 79.

The cerebellum. Ventral surface.

Binde A., Anterior cerebellar peduncles.

In order to obtain a good view we must first sever the connections of the cerebellum with the mid-brain, the pons, and the medulla oblongata. Thus, on each side are the three cut surfaces of the three cerebellar peduncles. Between the anterior peduncles lies a thin membrane, the velum medullare anticum, which is a part of the roof of the hind-brain. It is shown cut through in the figure.

The lobes on the under surface of the vermis are called—

1. The nodulus.
2. The uvula.

3. The pyramis (pyramid).

4. Tuber valvulæ, far back, and extending partly over on the dorsal surface.

In the hemispheres lie—

1. The flocculus, on each side of the nodulus.

2. The tonsilla, on each side of the uvula.

3. External to the last mentioned, the lobus cuneiformis.

4. Behind this, the posterior lower lobe, lobus posterior inferior. Its anterior part is called the lobus gracilis and its posterior part the lobus semilunaris inferior.

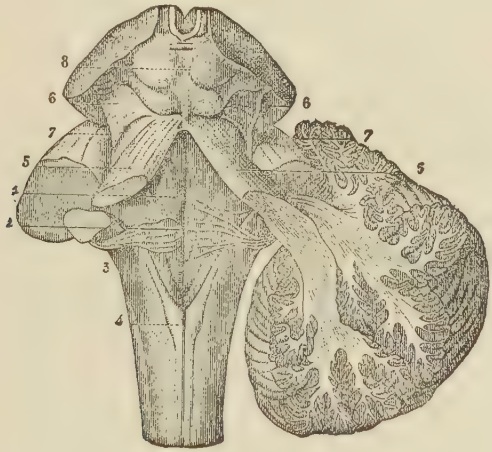

FIG. 80.

The three peduncles arising in the mid-brain, the pons, and the spinal cord, and passing into the cerebellum. After Hirschfeld and Leveillé (Sappey). Emerging from beneath the corpora quadrigemina (8) can be seen the superior cerebellar peduncles (5); from the ventral surface come the middle peduncles or arms of the pons (7), and from the spinal cord ascend the restiform bodies or inferior peduncles (3). On entering they decussate with the superior peduncles. Notice, too, the form of the rhomboidal fossa (1), the striæ acusticæ (2), the clavæ of the funiculi gracilis (4). At 6 is the fillet.

In the above cut you see the three bundles of medullary fibres just mentioned passing to the cerebellum on each side. These extend to the central white substance of the hemispheres, and this in turn is continued into the medulla of the lobules and ridges. These ridges are covered with a gray cortex, which follows closely all the elevations and depressions of the surface, so that its extent is relatively much greater than would be supposed from the size and shape of the cerebellum.

In the hemispheres the white substance is rather plentiful; but in the vermis it is scanty. The accompanying sagittal section (Fig. 81) through the cerebellum passes directly through the vermis. It shows the white substance of the latter prolonged anteriorly into a thin membrane, the velum medullary anticum, which extends toward the corpora quadrigemina. This thin membrane, spread out between the anterior peduncles of the cerebellum, marks the point where the roof of the mid-brain is continuous with the roof of the hind-brain. Upon it lies the most anterior lobule of the cerebellum,—the lingula.

The peculiar appearance presented by a sagittal section of

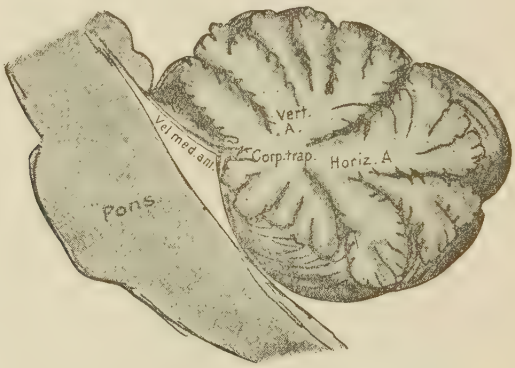

FIG. 81.
Sagittal section through the middle of the vermis.
Vert. A., Vertical branch. *Horiz. A.*, Horizontal branch.

the vermis gave rise to its ancient name, the arbor vitæ. The central mass of white matter is called the corpus trapezoides. The lingula, lobus centralis, uvula, and nodulus all communicate separately with it. A number of the lobes of the monticulus have a common connection with the corpus trapezoides, and form the vertical branch of the arbor vitæ. The posterior portion of the monticulus, the folium cacuminis, and the tuber valvulæ —that is to say, the lobes situated at the posterior edge of the cerebellum—form the horizontal branch of the arbor vitæ.

Posteriorly, the velum medullare posticum passes out from the cerebellum, forms the roof of the fossa rhomboidalis, and is

continued on to the termination of the posterior columns of the spinal cord.

The lateral portions of this roof are composed of a thickish (principally glia) tissue; in the middle line it is nothing but a thin layer of cuboidal epithelium. Numerous blood-vessels from

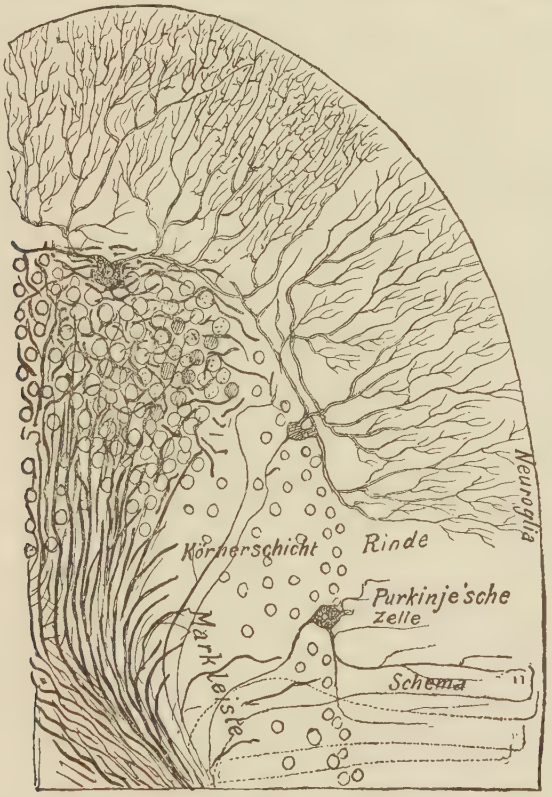

FIG. 82.

Section through the cortical layer of the cerebellum. Hæmatoxylin staining. Diagrammatic below and to the right.

Körnerschicht, Granular layer. *Markleiste*, Medullary layer. *Purkinje'sche Zelle*, Cells of Purkinje. *Rinde*, Cortex. *Schema*, Diagrammatic.

the pia are distributed through it, and crowd it partly down into the ventricle (plexus choroideus ventriculi quarti medialis). Opposite the medulla oblongata, its lateral portion forms a sort of sac, which is filled with vascular loops and is called the plexus choroideus lateralis (see Fig. 120). In the middle choroid

plexus, as well as near the point of origin of the lateral ones there are some minute perforations (Key and Retzius). The middle one of these foramina in the medullary tube is called the foramen of Magendie. It is of great importance in obviating sudden changes of pressure in the cerebro-spinal fluid.

Into the above-described mass of the cerebellum pass the three pedunculi on each side. They pass into the large central mass of white substance, and from there become united with gray nuclei and send fasciculi to the cerebellar cortex.

Little is known as to the connections and course of these cerebellar fibres. We know that they pass from the central white substance through a granular layer containing nerve and glia cells, that they extend beyond this and enter some peculiar, large, branched cells,—the ganglion-cells of Purkinje; that the processes of these latter bodies repeatedly divide and pass to regions just under the surface of the cerebellum. Apparently these processes enter into some sort of relation with a net-work of horizontal and oblique fibres situated in this part of the cortex. These bend around and pass back through the granular layer to the white substance after anastomosing and interweaving freely with each other. A general idea of their course may be obtained from the dark lines in the accompanying figure. Many more fibres return from the cortex than pass to its large cells,—a fact which can be explained by the ramifications of its cell-processes. All parts of the cortex are connected with each other by peculiar garlanded bundles of fibres, which closely follow the cortical elevations and depressions.

The cerebellum also presents collections of gray matter aside from that in the cortex. On each side, in the midst of the white substance of the hemispheres, there lies a large convoluted nucleus,—the corpus ciliare or corpus dentatum. Internal to it other collections of gray matter are met with; first, the embolus, then the nucleus globosus, a longish nucleus with a tuberosity at its posterior extremity; and lastly, lying farthest inward, is the nucleus tegmenti (nucleus fastigii).

These nuclei are best shown in an almost horizontal section through the cerebellum, such as is represented in Fig. 83, taken from B. Stilling's atlas. In such a section you will observe in

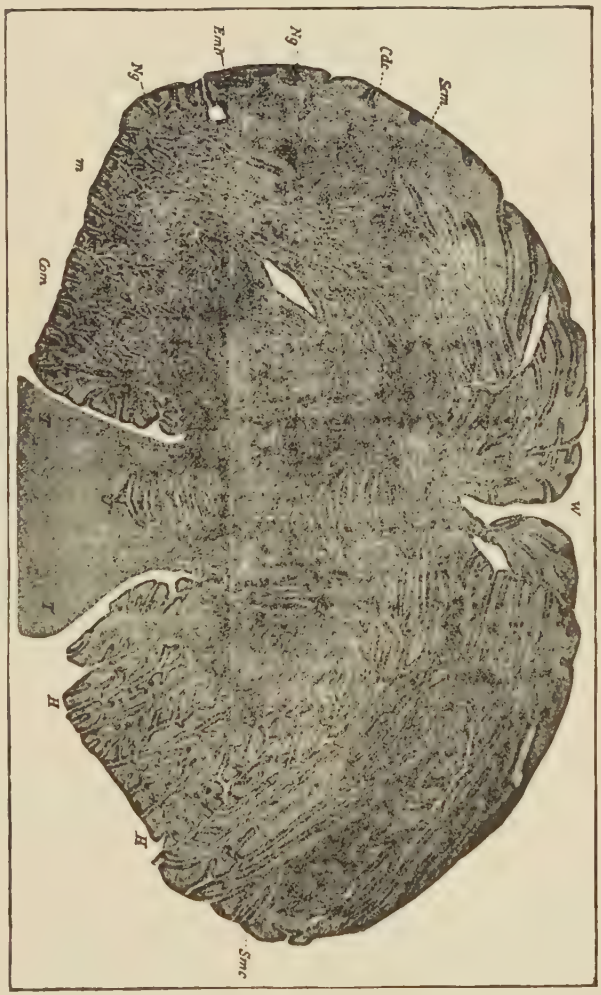

FIG. 83.

Horizontal section through the cerebellum. The section cuts across anteriorly the region under the corpora quadrigemina, *T*, then the superior cerebellar peduncles, *R*, and between them the lingula, *A*. In front of this there is in the vermis the nucleus tegmenti, *m*, the nucleus globosus, *Ng*, the emboliform, *Emb*, and in the hemispheres on each side the corpus dentatum cerebelli, *Cdc*. The line *Com* indicates the anterior decussation commissure. At *Sem* the fibræ semicirculares. (After B. Stilling.)

the centre the white substance of the vermis and the nucleus tegmenti, and in front of these some fasciculi of decussating fibres, the anterior decussating commissure. To the right and left lie the white substance of the hemispheres, inclosing the

nucleus globosus, the embolus, and external to these the plicated medullary lamina of the nucleus dentatus. The deep indentations in the surface mark the position of the fissures between the lobes. Between the anterior peduncles (*R R*) lies, as I before stated, the lingula on the velum medullare anticum: it is also cut through in a horizontal direction (*A*).

All the nuclei which you see in the white substance are connected with each other by bands of gray matter. Their relations to the fibres of the white substance are almost totally

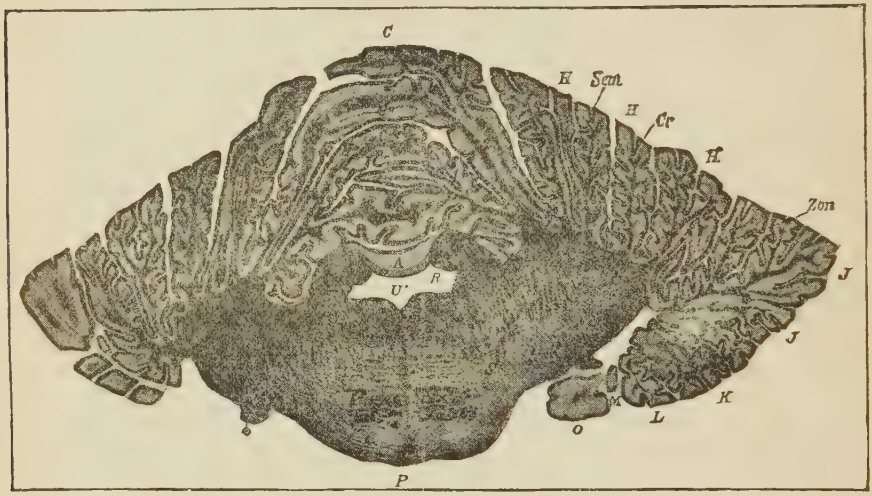

FIG. 84.

Section just in front of the culmen, passing in a frontal direction through the cerebellum. *U**, fourth ventricle. *R*, superior cerebellar peduncle. *P*, pons. *Zon*, decussational zone; internal to it lie the fibres of the fleece. *Cr*, bundles from the restiform body pass over into the fibræ semicirculares, *Sem*. *S*, region of exit of root of trigeminus. (After B. Stilling.)

unknown. If a frontal section is made just in front of the point where the peduncles enter the cerebellum, then dorsad of its plane will be the cerebellum, and ventrad of it will be the pons and the fibres which pass from it on both sides into the hemispheres. Between the cerebellum and the tegmentum lies the fourth ventricle, bounded on each side by the divided peduncles. This is the continuation of the aqueduct of Sylvius. The white substance of the vermis does not fall into the plane

of this section. The tegmentum and the crusta, the latter perforated by the fibres of the pons, are arranged just as we saw them in sections through the quadrigeminal region.

A good many of the bands of fibres shown in the accompanying cut have not yet been described, because we have had no opportunity to consider the system of fibres peculiar to the

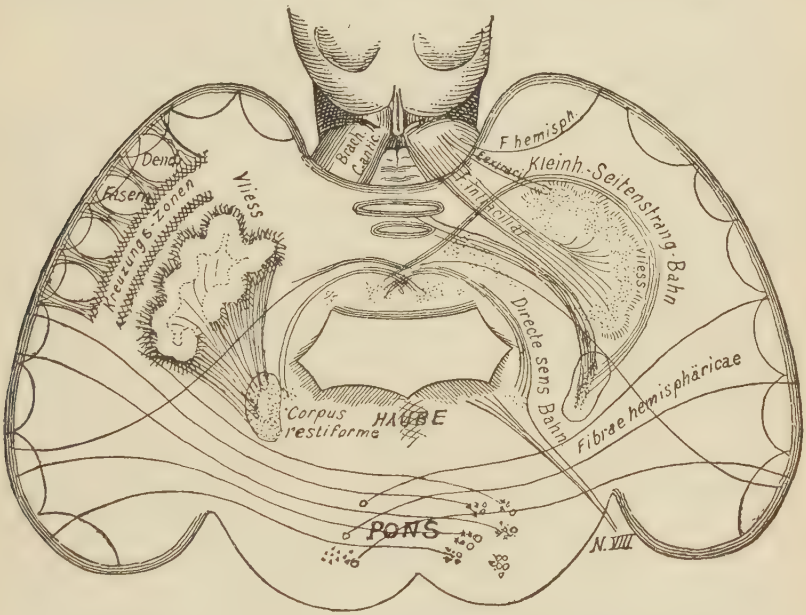

FIG. 85.

Diagram of the course of fibres in the cerebellum to explain the origin of the cerebellar peduncles. Notice that they are composed of intra-ciliary, extra-ciliary, and hemisphere fibres. This shown with peculiar distinctness in the right superior peduncle.

Dend. Fasern, Dendritic tracts.
Directe Sens. Bahn, Direct sensory tract.
Haube, Tegmentum.
Kleinh-Seitenstrang-Bahn, Lateral cerebellar tract.
Kreuzungs-zonen, Zone of decussation.
Vliess, The fleece.

cerebellum. We have seen that fibres pass through the three peduncles into the cerebellum; our knowledge of their course is still very unsatisfactory, notwithstanding the fact that that most skillful investigator, Benedikt Stilling, was for years occupied in the study of this region. The diagram (Fig. 85) will, in the simplest manner possible, give Stilling's views as to the most important tracts of fibres.* It represents a frontal section

* The fibres of the restiform bodies are given according to my own investigations, somewhat modified.

somewhat farther forward than the one given in Fig. 84. In order to simplify matters the anterior peduncles are represented as occupying a wrong position, as may be seen by comparison with Fig. 84. They ought to be shown lying close over the ventricle.

The first thing to attract our notice is that the different parts of the cortex are connected by curved fibres, fibræ arciformes. From all points of the cortex fibres arise, which, diverging from each other like the limbs of a tree, pass into the white substance. They are called the Dendritic tracts. Before they reach the corpus dentatum they are lost in a thick tangle of fibres. Several zones of these tangled fibres can be distinguished, and, from the fact that a true decussation can be made out in them, they have received the name of decussating zones. External to the ciliary body is a mass of fibres converging toward it, which in part enter the gray matter and in part pass through it. This mass of fibres, on account of its resemblance to wool, is called the fleece.

The anterior peduncles enter the ciliary body and break up into a net-work of fibres. This net-work (intra-ciliary fibres) is connected, either directly or by means of ganglion-cells, with the before-mentioned tangle of fibres, the fleece (extra-ciliary fibres). Fibres pass from this intra-ciliary net-work to the anterior peduncles, and to it from the cortex of the hemispheres. The anterior peduncles, therefore, are composed of (1) intra-ciliary fibres (the majority of fibres composing them); (2) extra-ciliary fibres; (3) fibres from the hemispheres. The last two of these are only present in small quantity.

The restiform bodies have their origin, to a great extent, in the fleece, and, therefore, consist chiefly of extra-ciliary fibres. Those fibres, however, which pass through the central portion of the restiform bodies, and which originate mainly in the spinal cord, pass, in part, directly to the dorsal cortex of the vermis, and in part pass around the corpus dentatum from without inward, and extend over to the ventral portion of the vermis,

where they are lost between the two nuclei globosi. These fibres receive their medullary covering as early as the seventh fœtal month. Another band of fibres, which becomes medullary at a later period than the last mentioned, but still far in advance of the bulk of the restiform fibres, arises in the vicinity of the nucleus globosus and passes to the outer wall of the fourth ventricle median to the posterior peduncles. Its most anterior fibres make their exit from the brain along with the trigeminal nerve, others pass off with the acoustic, and still others run caudad. The latter become still fewer in the oblongata, apparently because some of them enter the roots of the glossopharyngeal and vagus. Still, this fasciculus can be traced in cross-section to the termination of the posterior columns of the cord. The whole tract is called the direct sensory tract of the cerebellum. I shall have occasion later to show it to you in several illustrations. To-day I will call your attention to a section through the brain of a seven months' fœtus, in which you will recognize that portion of the tract which passes into the trigeminus (Fig. 86).

Lastly, it should be stated that fibres pass directly from the hemispheres to the restiform bodies.

The arms of the pons can be traced far into the corresponding hemispheres (hemisphere fibres). Near the cortex they are lost in the dense tangle of fibres. They receive, however, fibres from the fleece (extra-ciliary fibres).

In recapitulation we shall find that the anterior peduncles are composed mainly of intra-ciliary fibres, the middle peduncles largely of hemisphere fibres, and the posterior peduncles chiefly of extra-ciliary fibres and fibres from the roof of the vermis. But each peduncle receives auxiliary bands from the point of origin of each of the other peduncles.

The anterior peduncle and the restiform body also receive an addition from the white substance of the vermis.

There is a point in the anterior part of the white substance of the vermis where many fibres decussate,—the anterior decus-

sating commissure. These fibres come from the anterior lobules, decussate in front of the nucleus tegmenti, and pass to the opposite side of the cerebellum. From here they can be traced into the anterior peduncles and the restiform bodies.

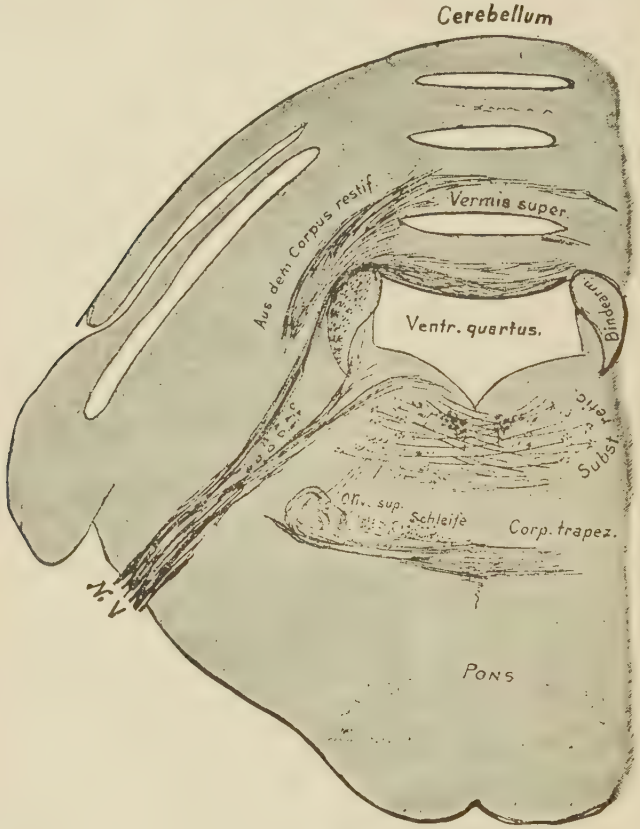

FIG. 86.

Frontal section through the cerebellum and pons of an embryo of 26 weeks. All the medullary fibres are stained with hæmatoxylin.

Aus dem Corpus restif., From the restiform body. *Bindearm*, Anterior cerebellar peduncle. *Schleife*, Fillet.

The fibres of the posterior lobules follow an exactly analogous course, and form the posterior decussating commissure in the back part of the white substance of the vermis.

In the midst of the white substance between the two commissures lies the nucleus fastigii (nucleus tegmenti), surrounded

and covered in by fibres which, originating in the horizontal branch of the arbor vitæ, connect the two decussating commissures, and in part pass off to the cerebellar hemispheres with the fibres of the anterior of these commissures. The nuclei tegmenti are connected with all these fibres.

The external surface of the cerebellum was described by Malacarne, Reil, and Burdach, just as it is described to-day. Investigations of its internal structure were undertaken by F. Arnold, Reil, Kölliker, Meynert, and particularly by B. Stilling. Later researches as to the structure of the peduncles have been made by Bechterew, Marchi, and the author. A whole literature has been written on the cortex of the cerebellum, among the contributors to which are Purkinje, Gerlach, Hess, Kölliker, Fee, Schultze, Obersteiner, Beevor, and Golgi.

Diseases of the cerebellar peduncles alone are very seldom observed. For this reason we are not familiar with the symptoms which would be caused by them. Gradual destruction of one brachium pontis may, apparently, give rise to no symptoms. Diseases which cause irritation (hæmorrhage, for example) may bring about forced movements, generally of a rolling nature, now toward the affected side, and now toward the sound one. A forced position of the trunk or of the head only, with or without nystagmus, has been observed in irritating diseases of one of the peduncles.

Diseases of the cerebellum may, on account of the intimate association with and proximity of the complex tracts of fibres lying in the crura cerebri, the pons, and the medulla oblongata, give rise to symptoms which cannot be attributed to the cerebellum. In cases where only actual cerebellar substance is diseased, we find vertigo, headache, vomiting, uncertainty of gait (ataxy), and vague feelings of weakness in the extremities, both of the same and the opposite side. Real paralysis and sensory disturbances are wanting. Occasionally, vision is seriously affected; still, it is difficult to say how far this may depend on a participation of the visual centres near by. Mental disturbances often appear in disease of the cerebellum. Inasmuch as many diseases of the cerebellum present no symptoms, and none of the symptoms above enumerated are caused exclusively by

cerebellar lesions, a diagnosis is very difficult, and, as a rule, uncertain. It is usually of great importance to take into consideration the symptoms arising from neighboring organs (paralysis of the oculo-motor, for instance).

It seems to be a fact that the diseases which attack the vermis are the ones which give rise to ataxy and vertigo.

Most of those symptoms which are regarded as characteristic of cerebellar disease only appear when the anterior or median peduncles, or the floor of the fossa rhomboidalis, or the quadrigeminal region are involved, either directly or indirectly.

LECTURE IX.

THE ROOTS OF THE PERIPHERAL NERVES, THE SPINAL GANGLIA, AND THE SPINAL CORD

GENTLEMEN: The peripheral nerves are made up, as you know, of both motor and sensory fibres. In the vicinity of the spinal cord these fibres are separated. The branch containing the motor fibres passes directly into the spinal cord as an anterior root. The sensory fibres pass into the spinal ganglion.

Situated in the spinal ganglia are a number of large monopolar cells (occasionally bipolar). In the case of a monopolar cell the process generally divides shortly after leaving it, so that here also we have two processes.

Your attention was called to these two processes of the cells of the spinal ganglia in the second lecture. You will recollect that, according to the observations of His, the sensory nerves are evolved from cells in the form of a process extending toward the periphery, and that these cells also send out another fibre toward the spinal cord which forms the posterior root.

Since the careful examination made on adults shows that about as many fibres pass through the posterior root to the spinal cord as have entered the ganglion from the nerves, it would seem as though a single cell were intercalated in the course of each fibre.

It is, however, a matter of great importance to determine whether all sensory nerves originate in the cells of the spinal ganglia. This question has been fully settled by the experiments of Waller and others, and by the most recent experiments of Joseph.

Every nerve-fibre which is divided from its mother-cell degenerates. If a sensory nerve is divided just in front of the

spinal ganglion all its fibres degenerate. The ganglion itself and the root originating in it remain normal. This shows that the cut has severed all the fibres from their cells. If we cut the posterior root just back of the ganglion, only a few fibres of the sensory nerve become degenerated and the majority remain intact. The nerve must, therefore, consist of fibres which originate in the spinal ganglion-cells, for the connection between these is unbroken. The fibres which were destroyed must have come from the spinal cord itself, for they are only severed from the latter and not at all

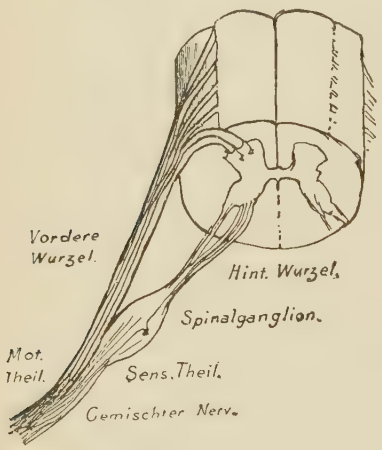

FIG. 87.
Diagram of the relations of the nerve-roots to the spinal cord.
Gemischter Nerv., Mixed nerve. *Hint. Wurzel*, Post. root.
Mot. Theil, Motor part. *Sens. Theil*, Sensory part.
Vordere Wurzel, Ant. root.

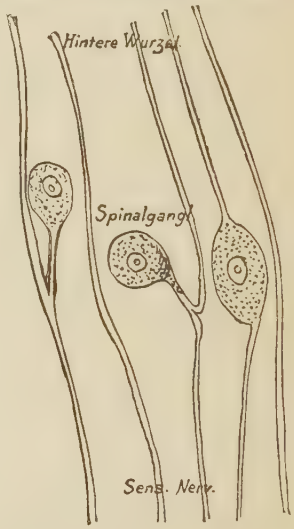

FIG. 88.
Diagram of the fibres of a spinal ganglion.
Hint. Wurzel, Post. root.

from the ganglion. An examination of the root after this latter experiment will account for this. The root is divided from the ganglion, and we find that only a few fibres have remained sound: the majority have been destroyed. The fibres which remain uninjured must have their source in the spinal cord, for they are connected to it alone; the fibres which perish must come from the spinal ganglion, for their connection with it alone was severed.

Experiments show that cell-processes pass out of the gan-

glion in two directions, and that fibres which originate in the spinal cord only pass through it. We may, therefore, consider the relations of the sensory roots to the spinal ganglia to be as represented in the diagram, Fig. 88.

Between the spinal ganglion and the cord the sensory and motor roots divide into a number of root-fibres, which for some considerable distance enter the spinal cord, the sensory fibres on the dorsal aspect, and the motor fibres on the ventral surface, in a groove situated somewhat laterally. The number of these root-fibres is not alike for all roots, and differs in different individuals.

Recent investigations show that each root does not correspond to one definite peripheral nerve. It has been proved that in each peripheral nerve there is contained a large number of nerve-fibres from different roots, and it is very

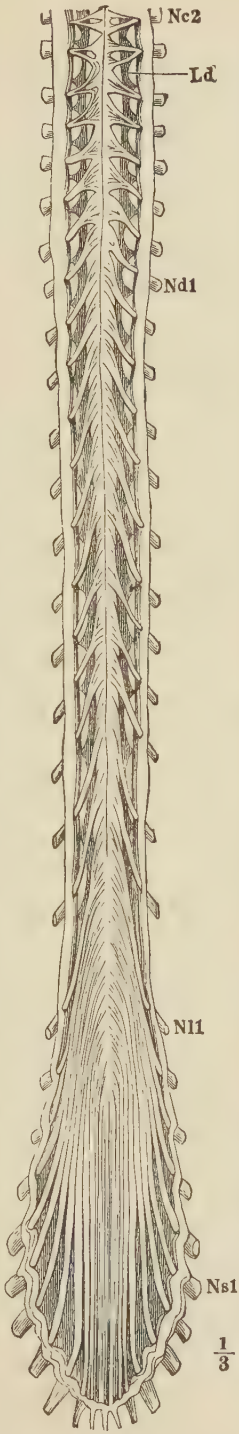

FIG. 89 A.—Anterior view of spinal cord with entering nerve-roots. The trunks pass through the dura and then spread themselves out, fan-like, along the cord. Between the dura and the spinal cord is a dentated suspensory ligament, the ligamentum denticulatum, *Ld*. *Nc2*, second cervical nerve; *Nd1*, first dorsal nerve; *Nl1*, first lumbar nerve; *Ns1*, first sacral nerve.

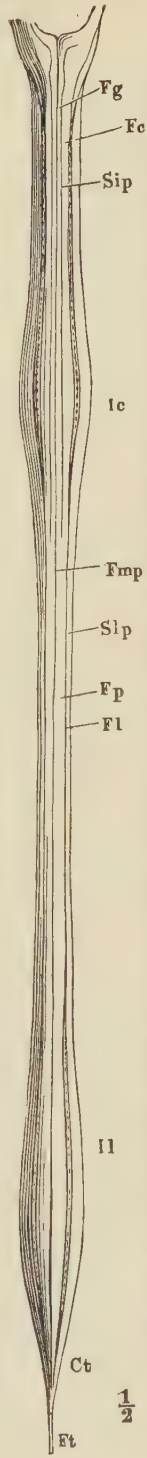

FIG. 89 B.—Posterior view of spinal cord after division of the nerve-roots. Notice the two enlargements: *Ic*, cervical enlargement; *Il*, lumbar enlargement. By means of the posterior median fissure, *Fmp*, the posterior columns, *Fp*, are separated from each other. In the cervical region the sulcus intermedius posticus, *Sip*, divides these columns into the funiculus gracilis, *Fg*, and the funiculus cuneatus, *Fc*. *Ct*, conus terminalis; *Ft*, filum terminale.

probable that two muscles which are commonly associated in co-ordinate movements are innervated by the same root, even though they may be supplied by different nerves.

The interchange of fibres which makes this possible takes place partly in the plexus (cervical, lumbar, etc.) and partly in the larger nerve-trunks, which are themselves to be regarded as a sort of plexus.

Only few cases of disease of the spinal ganglia are known. Besides acute pain, an intercostal herpes zoster extending along the course of the affected nerves has been taken as a symptom of this trouble. It is questionable, however, whether this should be referred to the ganglionic apparatus, for we have herpes zoster without disease of the ganglia, and, furthermore, herpes zoster has been found to follow inflammation of the peripheral nerves.

The roots, therefore, enter the spinal cord along its whole length. The latter becomes somewhat thickened at those points where the largest roots enter it from the extremities. The cervical enlargement receives the nerves of the arms, and the lumbar enlargement those of the leg. The intercostal nerves arise from the narrowest part of the spinal cord. The lowest, club-shaped, portion is called the conus terminalis: from it there arise not only the nerves but a long, thin prolongation,—the filum terminale.

The upper boundary of the cord is formed by the commencement of the decussation of the pyramidal tract (of which, later).

It is often an important diagnostic point at the bedside to determine the level at which those nerves arise which supply certain paralyzed muscles or anæsthetic regions of the skin.

The effort has been made to settle this question by experiments on animals, for the simple anatomical method would never suffice. The attempt has repeatedly been made to summarize those local injuries to the cord in human beings (compressions, hæmorrhages, etc.) which give rise to definite disturbances and utilize the results to settle this question.

I give you herewith the results attained by Starr in this manner, who made a comparative study of all the cases he could obtain, in 1888. In all probability, further researches will lead to minor corrections.

LOCALIZATION OF FUNCTION IN THE DIFFERENT SEGMENTS OF THE SPINAL CORD.

SEGMENT.	MUSCLES.	REFLEXES.	SENSATION.
2d and 3d Cervical.	Sterno-mastoid. Trapezius. Scaleni and neck. Diaphragm.	Hypochondrium(?). Sudden inspiration produced by sudden pressure beneath lower border of ribs.	Back of head to vertex. Neck.
4th Cervical.	Diaphragm. Deltoid. Biceps. Coraco-brachialis. Supinator longus. Rhomboid. Supra- and infra-spinatus.	Pupil. 4th to 7th cerv. Dilatation of the pupil produced by irritation of neck.	Neck. Upper shoulder. Outer arm.
5th Cervical.	Deltoid. Biceps. Coraco-brachialis. Brachialis anticus. Supinator longus. Supinator brevis. Deep muscles of shoulder-blade Rhomboid. Teres minor. Pectoralis (clav. part). Serratus magnus.	Scapular. 5th cervical to 1st dorsal Irritation of skin over the scapula produces contraction of the scapular muscles. Supinator longus. Tapping its tendon in wrist produces flexion of forearm.	Back of shoulder and arm. Outer side of arm and forearm. Anterior upper two-thirds of arm.
6th Cervical.	Biceps. Brachialis anticus. Pectoralis (clav. part). Serratus magnus. Triceps. Extensors of wrist and fingers. Pronators.	Triceps. 5th to 6th cervical. Tapping elbow-tendon produces extension of forearm. Posterior wrist. 6th to 8th cervical. Tapping tendons causes extension of hand.	Outer side of arm and forearm. Inside and front of forearm.
7th Cervical.	Triceps (long head). Extensors of wrist and fingers. Pronators of wrist. Flexors of wrist. Subscapular. Pectoralis (costal part). Latissimus dorsi. Teres major.	Anterior wrist. 7th to 8th cervical. Tapping anterior tendon causes flexion of wrist. Palmar. 7th cervical to 1st dorsal. Stroking palm causes closure of fingers.	Inner and back of arm and forearm. Radial distribution in the hand.
8th Cervical.	Flexors of wrist and fingers. Intrinsic muscles of hand.		Forearm and hand; median and ulnar areas.
1st Dorsal.	Extensors of thumb. Intrinsic hand-muscles. Thenar and hypothenar eminences.		Ulnar distribution to hand.
2d and 12th Dorsal.	Muscles of back and abdomen. Erectores spinæ.	Epigastric. 4th to 7th dorsal. Tickling mammary region causes retraction of the epigastrium. Abdominal. 7th to 11th dorsal. Stroking side of abdomen causes retraction of belly.	Skin of chest and abdomen, in bands running around and downward corresponding to spinal nerves. Upper gluteal region.

LOCALIZATION OF FUNCTION (*continued*).

Segment.	Muscles.	Reflexes.	Sensation.
1st Lumbar.	Ilio-psoas. Sartorius.	Cremasteric. 1st to 3d lumbar. Stroking inner thigh causes retraction of scrotum.	Skin over groin and front of scrotum.
2d Lumbar.	Ilio-psoas. Sartorius. Flexors of knee (Remak). Quadriceps femoris.	Patella tendon. Striking tendon causes extension of leg.	Outer side of thigh.
3d Lumbar.	Quadriceps femoris. Inner rotators of thigh. Abductors of thigh.	Bladder centre. 2d to 4th lumbar.	Front of thigh.
4th Lumbar.	Abductors of thigh. Adductors of thigh. Flexors of knee (Ferrier). Tibialis anticus. Peroneus longus.	Rectal centre. 4th lumbar to 2d sacral. Gluteal. 4th to 5th lumbar. Stroking the buttock causes dimpling in fold of buttock.	Inner side of thigh and leg to ankle. Inner side of foot
5th Lumbar.	Outward rotators of thigh. Flexors of knee (Ferrier). Flexors of ankle. Peronei. Extensors of toes.	Achillis tendon. Overextension causes rapid flexion of ankle, called ankle-clonus.	Lower gluteal region back of thigh. Leg and foot, outer part.
1st and 2d Sacral.	Flexors of ankle. Long flexor of toes. Intrinsic muscles of foot.	Plantar. Tickling sole of foot causes flexion of toes and retraction of leg.	Leg and foot except inner side. Perineum and back of scrotum. Anus.

The course of the fibres in the spinal cord, gentlemen, is only imperfectly known. In order to obtain a clear understanding of it, you must make yourselves perfectly familiar with the appearances presented by a transverse section of the organ.

In such a cross-section you will recognize the white substance externally and the gray matter in the form of a letter H in the middle. The two lateral halves of the spinal cord are divided by the anterior and posterior longitudinal (median) fissures, and connected with each other by the anterior or white commissure and the posterior or gray one. We call the anterior extension of gray matter the anterior horns (cornua) and the posterior extension the posterior horns or cornua.

The proportions of gray and white substance are not the same at all levels. The gray substance predominates markedly

from the upper lumbar region down. Fig. 91 shows cross-sections made at different levels in the spinal cord.

Aside from the proportionate differences in the gray and white substances, you will notice that the most lateral portion of the anterior horns in the lower cervical and upper dorsal regions become more and more developed (D_1 and D_3) until they form an independent process, which is called the lateral horn or intermedio-lateral tract. In the lower dorsal region the lateral horns again disappear. They are shown at *o* in Fig. 90.

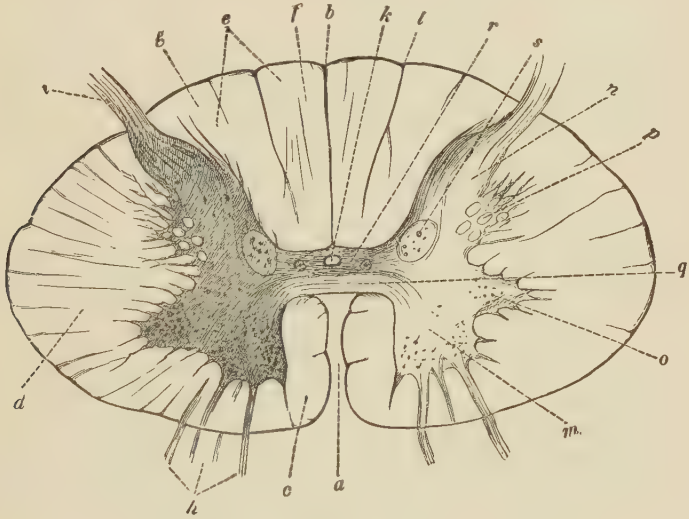

FIG. 90.

Semi-diagrammatic cross-section of spinal cord. *a*, anterior, *b*, posterior longitudinal fissures; *c*, anterior column; *d*, lateral column; *e*, posterior column; *f*, funiculus gracilis; *g*, funiculus cuneatus; *h*, anterior, *i*, posterior roots; *k*, central canal; *l*, sulcus intermedius posticus; *m*, anterior horn; *n*, posterior horn; *o*, intermedio-lateral tract; *p*, processus reticularis; *q*, anterior white commissure; *r*, posterior or gray commissure; *s*, column of Clarke, or vesicular column. (After Erb.)

Throughout the whole cervical and the upper part of the dorsal regions, in the angle between the intermedio-lateral tract and the posterior horn, the gray matter is not sharply defined, but projects out into the white substance in the form of a net-work of gray bands and fasciculi. This net-work is called the processus reticularis.

At the terminal cone the gray matter is covered only by a thin layer of white substance (*Co*, Fig. 91).

The root-fibres of the motor nerves pass by the spinal ganglia directly into the spinal cord, traverse the white substance, and enter the anterior horn. It is very probable that the axis-cylinders of all these fibres are connected with the large ganglion-

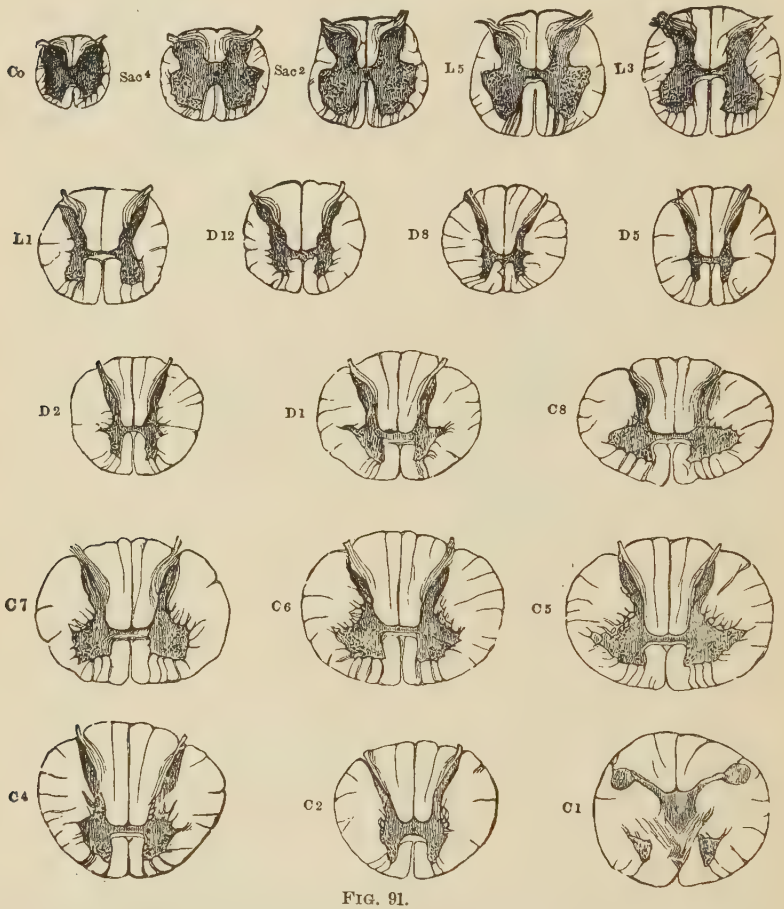

FIG. 91.

Sections through the spinal cord at different heights. The letters and figures show the spinal nerves at the level of whose exit the section is made. (After Quain.)

cells as shown in Fig. 92. These cells, which constitute the first station of the motor innervation-tract, are so distributed over the section of the spinal cord that we can make out (to the left at *m* in Fig. 90) more or less distinctly a median and a

lateral group in front, and, behind the latter, a central group. In the cervical cord there is also a group in the lateral horn.

On making a longitudinal section we see that these cells are somewhat more plentiful opposite the entrance of each root; that is to say, they are arranged in segments. We call such an aggregation of cells, together with the root arising from it, a

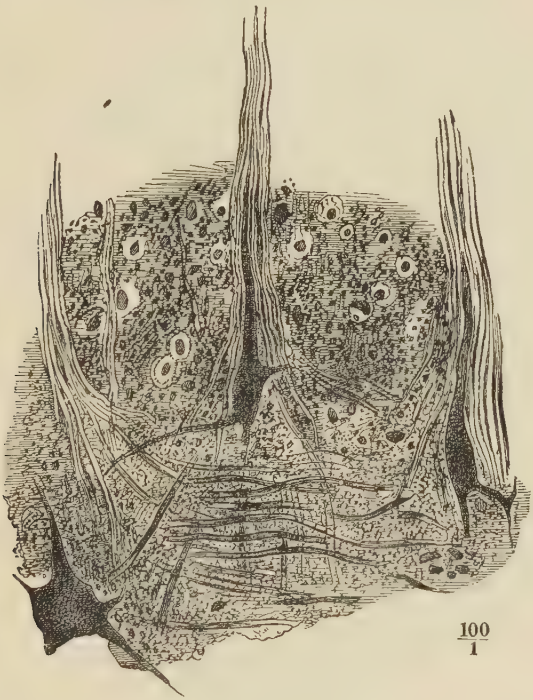

FIG. 92.

From the anterior border of a section through the anterior horn of the gray matter. Passage of the cell processes into nerve-roots. Carmine stain $\frac{100}{1}$. (After Henle.)

segment of the spinal cord. In human beings the segmentation of the cord is almost obliterated, but it is more pronounced in the lower animals.

Nothing is certainly known as to the course of those processes of the ganglion-cells which do not terminate in axis-cylinders: a few appear to extend directly to other ganglion-cells; the majority, however, are lost in a fine net-work of most

delicate fibrils, which permeates all the gray matter, and of which it is still doubtful whether or not it is nervous tissue.

The sensory roots, after passing through the spinal ganglia,

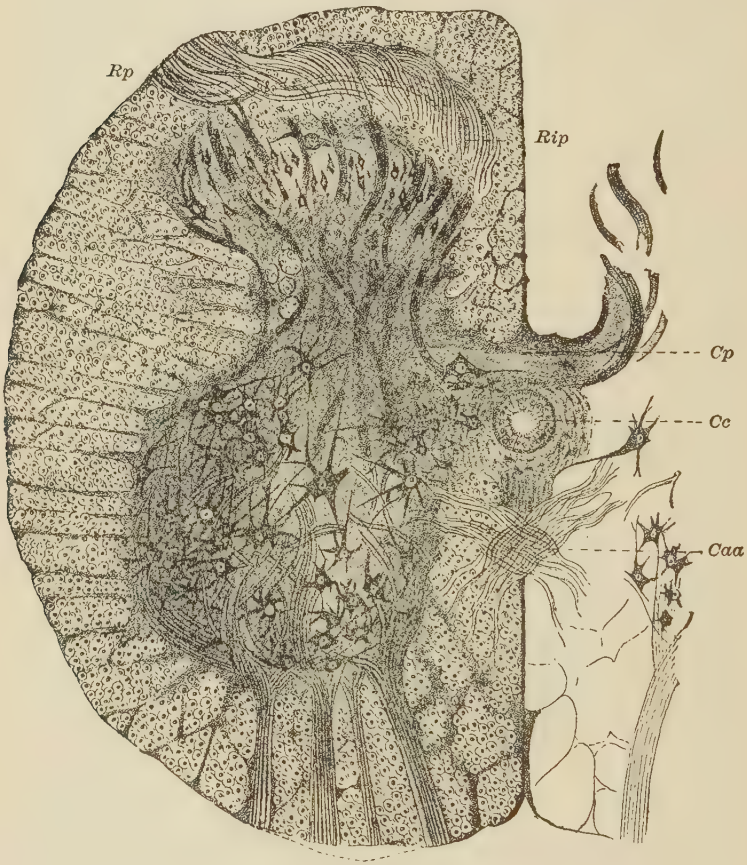

FIG. 93.

Half of a section through the lumbar cord. *Ra*, anterior root; *Rp*, posterior root; *Rip*, inner portion of the posterior root; *Cp*, posterior commissure; *Caa*, anterior commissure: *Cc*, central canal. The fine net-work of medullary fibres in the gray matter and the net-work of medullary fasciculi in the otherwise gray posterior commissure are not shown. (After Deiters.)

run in part direct to the posterior horn and in part to the posterior white columns. The cell-complex of the spinal ganglion is the real source from which these fibres arise. You recollect that embryology shows that the cells of this ganglion

grow peripherally toward the nerves and centrally in the direction of the spinal cord.

The centripetal processes form what we call the posterior root. It is, however, joined by fibres which do not originate in the cells of the spinal ganglia. These are apparently the fibres which we see passing to a peculiar group of cells which resemble

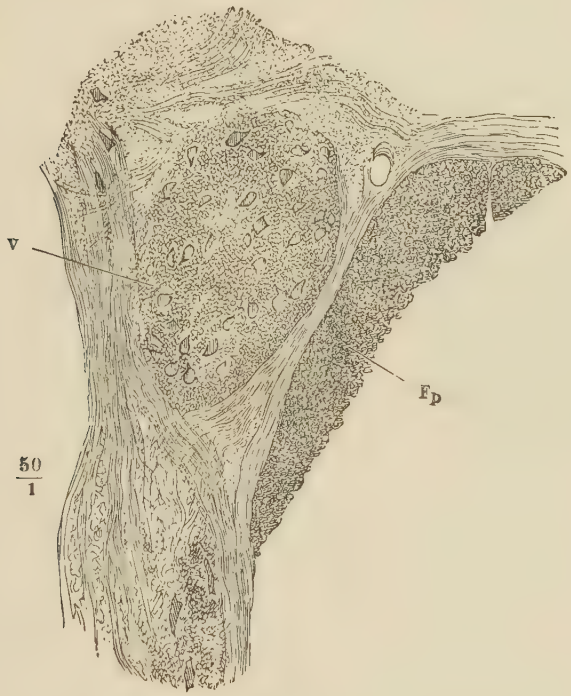

FIG. 94.
Cross-section of the vesicular column (*v*). *Fp*, funiculus post. (After Henle.)

those of the spinal ganglia. This group, columna vesicularis, or column of Clarke (Fig. 90), lies about at the junction of the anterior and posterior horns. Besides these cells it contains a small bundle of extremely fine nerve-fibres, which run in the long axis of the spinal cord.

The vesicular column can only be distinctly traced from about the end of the cervical to the beginning of the lumbar

enlargement; it probably, however, extends high up into the medulla oblongata.

At the tip of the posterior horn there is found a glassy, semi-transparent body,—the substantia gelatinosa Rolandi. As has been shown by Corning, this is the remains of a tissue which was present throughout the spinal cord during the embryonal period. Its cells strongly resemble ganglion-cells, but their nature is still unknown. Many fibres of the posterior root pass through it (Fig. 93).

At several points in the gray matter there can be seen but few nerve-fibres, and scarcely any ganglion-cells. At these points the neuroglia is the only constituent, and they therefore present a pale-grayish, translucent appearance to the naked eye. A very plentiful deposit of neuroglia is situated around the central canal, and is called the substantia gelatinosa centralis. The whole periphery of the spinal cord is also covered with a thin mantle of almost pure neuroglia,—the gelatinous cortical layer.

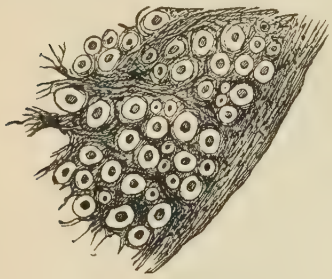

FIG. 95.

Part of cross-section of the white substance of one of the lateral columns. The transversely-divided nerve-fibres, in the centre of each of which is an axis-cylinder, are surrounded by neuroglia containing Deiters' cells. (After Erb.)

The white substance surrounding the gray matter consists principally of fibres running lengthwise of the spinal cord, of the obliquely-ascending roots of the nerves, and of fibres which run more or less perpendicular to the long axis of the cord, from the gray matter into the white substance. The nerve-fibres have an axis-cylinder and a medullary sheath. The width of the latter varies greatly. The sheath of Schwann is wanting. Between the fibres lies the neuroglia, which at many points is continuous with a fibrous connective tissue. In this connective tissue, which is continuous externally with the neuroglia and with the pia mater, are situated blood-vessels which have a somewhat radial arrangement. The neuroglia consists here, as in the

gray matter, of numerous cells with long, slender processes. The body of the cell is usually so small that the processes have the appearance of springing from the nucleus. Occasionally, however, it is larger. These cells are called the spider-cells, or cells of Deiters. (See Fig. 95, at left).

The spinal cord is, as a glance at a transverse section will show, divided into several columns by the entering nerve-roots and the longitudinal fissures. Internal to the spinal nerve-roots are situated the anterior or posterior columns, as the case may be, and external to them the lateral columns.



FIG. 96.

Diagram of descending degeneration in the pyramid, with a lesion in the left internal capsule.

The study of embryology and the investigation of certain diseases of the spinal cord show that the anterior, lateral, and posterior columns are not uniform masses of fibres of equal importance, as might appear from a section through the adult organ, but that they are composed of several different divisions.

You remember the pyramidal tract, whose course we traced from the cortex of the motor zone through the capsule and the crusta to the ventral part of the pons.

Let us ascertain in what part of the spinal cord this tract is situated. It is not difficult to discover this. If a destructive disease involves any part of this extensive tract the nerve-fibres disappear, and are replaced by connective tissue. This process, which is called secondary degeneration, continues downward

into the spinal cord. Here it occupies two regions,—first, the innermost portion of the anterior column on the side of the brain-lesion, and, secondly, a large area in the lateral column of the opposite side. High up, at the commencement of the oblongata, we see that the crossed degeneration passes back to the side of the uncrossed degeneration; that is, the degenerated tract decussates with the normal pyramidal tract. The tract which, in this instance, is involved in the descending degeneration is called, as in the brain, the pyramidal tract. In the spinal cord it is divided into the anterior (columnar) pyramidal tract (most median part of anterior column) and the lateral (columnar) pyramidal tract (in the posterior portion of the lateral column). There are grounds for believing that these pyramidal tracts contain most of those fibres from the brain to the spinal cord which convey the impulses for conscious movement. They degenerate only downward; their nerve-fibres always disappear if the cross-section of the tract is destroyed at any point of its course in the brain or spinal cord. In human beings all the tracts in the spinal cord have their medullary sheaths at the time of birth. The pyramidal tract is the only exception to this rule. On a section taken from the spinal cord of a newborn child, therefore, the pyramidal tracts appear gray in the midst of the white lateral columns.

FIG. 97.
Secondary descending degeneration following a lesion in the left cerebral hemisphere. (After Erb.)

The cross-section of the pyramidal tract diminishes gradually toward the lumbar region. In the lower dorsal region the pyramidal tract of the

anterior column can no longer be seen, because its fibres are lost in the regions from which the motor nerves issue. In Fig. 100 the points 7 and 7′ give a general idea of the pyramidal tract at different levels of the spinal cord.

The examination of spinal cords affected by secondary degeneration throws still more light upon their structure. If we make sections of spinal cord whose continuity has been interrupted in the dorsal portion by pressure or any other violence, we shall find, as might be expected from what has already been

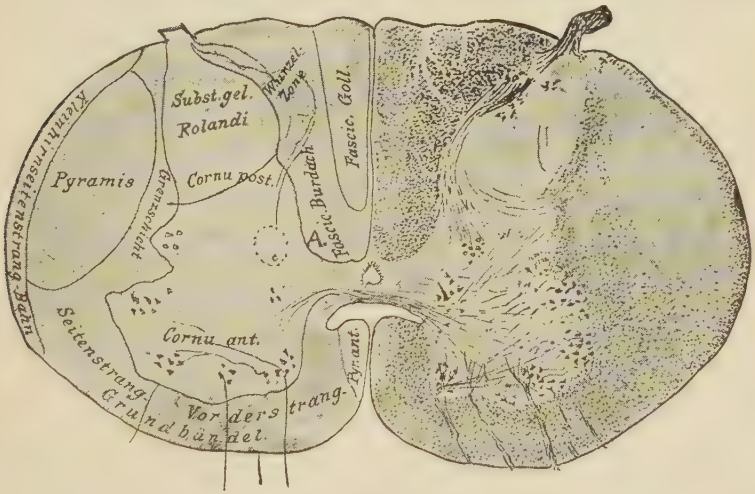

FIG. 98.

Cross-section through the cervical cord of a newborn child. The pyramidal tracts without medullary fibres appear glistening and clear. The direct pyramidal tract in the anterior column encroaches markedly upon the antero-lateral column.

Grenzschicht, Limiting layer.
Grundbündel, Ground-bundle.
Kleinhirnseitenstrang-Bahn, Lateral cerebellar tract.
Seitenstrang, Lateral column.
Vorderstrang, Anterior column.
Wurzel Zone, Zone of the roots.

said, that the pyramidal tracts on each side have become degenerated downward. But there is also a degeneration upward from the level of the injury. At first this degeneration occupies the whole area of the posterior column, but at a point a few segments higher up it is limited to that part of the column which lies along the posterior median fissure. In such specimens we can easily divide the posterior column into an inner and an outer one. The parts affected by this ascending degeneration (which extends into the oblongata) are fibres of the posterior

roots, which have been divided from their ganglion-cells in the spinal ganglia. If we divide these posterior roots experimentally just outside the spinal column (Singer) we shall produce an exactly similar degeneration. Just above the divided point both the outer and the inner posterior columns are degenerated; farther up new and healthy root-fibres enter and arrange themselves to the outside of the injured ones, so that the area of degeneration is gradually pushed farther and farther toward the median line as we pass higher up in the cord.

Fig. 99.
Secondary ascending and descending degeneration following a transverse division of the cord in the upper dorsal region. (After Strümpell.)

The study of the development of the medullary sheaths confirms the conclusion reached by the investigation of secondary degeneration. It teaches that there are here, at least, two sets of fibres,—an outer one, ordinarily called the fundamental bundle of the posterior column, also called wedge-shaped column, or column of Burdach, and an inner one, which is called the slender column (funiculus gracilis), or Goll's tract. In the normal adult cord the two divisions of the posterior column* are separated from each other by a septum of connective-tissue only in the cervical region. In sections made lower down we can only distinguish them when one or the other is degenerated, and therefore is differently stained. Goll's tract increases in size from below upward as far as the upper dorsal region, probably because portions of the posterior nerve-roots are continually entering it on their way to the medulla oblongata. It is not improbable that still further subdivisions of the posterior columns will be made in the future. The manner of extension of certain diseases, and occasional rare forms of secondary degeneration, lead us to anticipate this.

* Funiculus cuneatus and funiculus gracilis in Fig. 89 B, also called postero-external and postero-internal columns.

The region near the gray commissure, which is marked *A* in Fig. 98, on the left, must contain a distinct system of fibres, because, for example, it never becomes involved in cases of tabes, even though the other parts of the posterior columns degenerate. We may call this the ventral field of the posterior column.

The posterior columns consist of the entering fibres of the

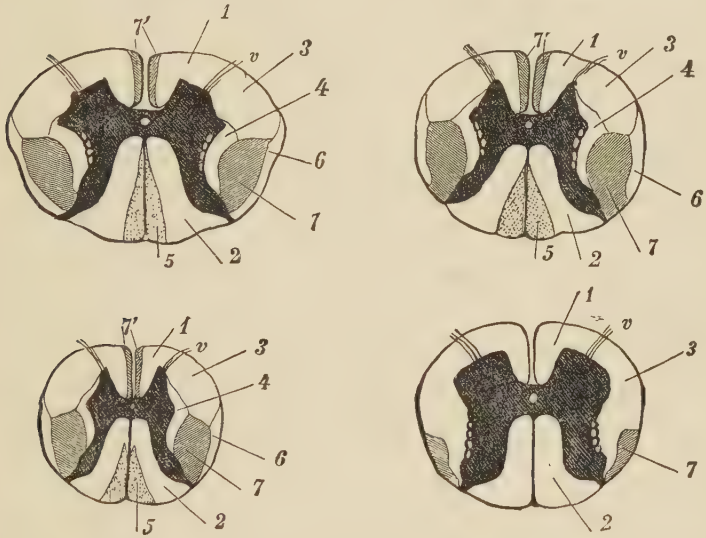

FIG. 100.

Sections through the spinal cord in the upper cervical region, the dorsal region, and the middle of the lumbar region. Boundaries of the different columns of the white substance. 1. Basal bundle of the anterior column. 2. Basal bundle of posterior column, the wedge-shaped column or column of Burdach. 3. Anterior mixed zone of lateral column. 4. Lateral boundary-layer of gray substance. 5. The delicate column, or column of Goll. 6. Lateral cerebellar tract. 7. Crossed pyramidal tract in lateral column. 7'. Direct pyramidal tract in anterior column. *v*, anterior roots. The gray substance is shown black. (After Flechsig.)

posterior roots. These roots are arranged in such a way that when they first enter the cord they lie on the outer side near the posterior horn, and those entering afterward (*i.e.*, above them) crowd their predecessors inward. Thus it happens that in the cervical region the fibres from the lower extremities are found principally in the column of Goll, while the column of Burdach contains very many fibres from the upper extremities. You must not imagine, gentlemen, that these divisions of the posterior

columns convey upward all the fibres of any posterior root. Many of the fibres pass into the gray matter directly after the root has entered the spinal cord, and others pass first into the posterior horn and then into the gray matter. Therefore, relatively few of those fibres which entered the posterior columns below are to be found in the upper part of the cord. Experimentally we have ascertained that the area of degeneration due to section of a posterior root becomes continually smaller as it is traced upward. At the same time it moves inward.

At the upper part of the spinal cord the funiculus cuneatus receives fibres which do not come directly from the posterior roots. Their origin is uncertain.

But, as you have been told before, all the sensory fibres do not terminate in the cells of the spinal ganglia; a part pass through the ganglia apparently to end in the cells of the column of Clarke, their first terminal station. These fibres remain normal when the root is cut across, for the reason that they are not divided from their own cells in that experiment. They do degenerate, however, if the continuity of the spinal cord itself is broken. In fact, in the latter case (Fig. 99), we see still another tract of fibres degenerate. It is that shown in the peripheral portion of the lateral columns at 6, in Fig. 100. This tract can be traced as far as the worm of the cerebellum. It is owing to embryological researches (Flechsig) that we are able to recognize and distinguish this direct lateral cerebellar tract from other tracts in the lateral column. In the first weeks of life, before the pyramidal tract has become medullated, the cerebellar tract lies like a delicate white border along one-half of the periphery of the lateral column.

Just in front of the cerebellar tract lies a tract which projects like a wedge from the periphery of the lateral column toward the centre. It is not indicated in the diagrams, but is apparently independent, for it may degenerate (upward) by itself. It is called the fasciculus antero-lateralis.

By the study of secondary degeneration and embryology, therefore, we have discovered the following systems of white

fibres. To these subdivisions we have given the general name of columnar systems. In the anterior columns the anterior direct pyramidal tract; in the lateral columns the lateral crossed pyramidal tract, and the direct cerebellar tract; in the posterior columns the ground-bundles and the funiculi graciles.

If you will look at Fig. 100 you will observe, aside from the above-named, two areas in the section which have been left white. They are marked 1 and 3, and are situated in the anterior and lateral columns. They are probably a region which is only traversed by the anterior roots, and have received the name of remnant of the antero-lateral column. The part lying in the anterior column is also called the anterior ground-bundle (1, in figure). The part lying in the lateral column has received the name of anterior mixed zone of the lateral column (3, in the figure). The fibres of the remnant of the antero-lateral column arise in part in the anterior roots and in part in the gray matter. They come principally from the centripetal processes of the sensory tract. The field marked 4 in Fig. 100 (lateral limiting layer of the gray matter) contains the direct continuations of the nerve-roots which, after passing transversely through the posterior horn (see Fig. 98), ascend in this layer.

Let us, now that we have learned the general arrangement of the structures of the spinal cord, see what becomes of the entering root-fibres, the examination of which we abandoned for a time. Let us see how far their course within the central organ has been investigated. We are no longer considering the form and arrangement of the different parts of the central nervous system; that which now demands our attention is the intimate connection between its constituent elements, the relation of fibre to fibre and of fibre to cell.

The fasciculi of the anterior roots pass in a gentle ascent through the midst of the antero-lateral columns. Each fasciculus is spread out over a large extent of the white substance. For this reason any injury to the column must involve a certain number of the anterior root-fibres, and it is therefore impossible

to arrive at any conclusion concerning the function of the antero-lateral column proper by section experiments on animals. The anterior roots, which contain motor fibres, and also exert a trophic influence on both muscle and nerve, are an important constituent of the columns now under consideration.

The accompanying drawing and Fig. 102 will give you an idea of the central course of the anterior roots.

On reaching the gray substance the component fibres of each bundle separate. There are many and conflicting statements as to the ultimate destiny of these fibres. The following explanation, which is based largely on my own investigations, is an attempt to harmonize the most important of these statements.



FIG. 101.
Passage of the anterior roots through the substance of the spinal cord. (Diagrammatic.)

First, we may consider it as settled that the fibres of the anterior roots pass to the ganglion-cells of the anterior horn, or, rather, become continuous with their axis-cylinder process (see Fig. 92). A few of these fibres pass to the cells of the opposite anterior horn by way of the anterior commissure.

The nuclei of the anterior roots are connected by nerve-fibres with the pyramidal tracts. We see large numbers of these fibres at the bottom of the anterior median fissure passing across the middle line of the anterior direct pyramidal tract. The fibres, from the anterior horn to the lateral crossed pyramidal tract, are less easily demonstrated on account of the obliquity of their course and the extreme difficulty of making a section exactly in their plane. In Fig. 102 these central portions of the motor tract are indicated by fine lines, the peripheral (ganglion-cells of the roots) with coarse ones. The nature of union between the ganglion-cells and the pyramidal fibres is unknown.

Fibres pass from the anterior horn to the lateral and median portions of the ground-bundle of the antero-lateral column.

The anterior commissure is composed of the central fibres from the root-nuclei to the opposite anterior pyramidal tract, the fibres from the roots to the corresponding cells of the opposite side, and of fibres from the posterior horn.

All these fibres are surrounded and enclosed by an extraordinarily close tangle of fibres, the unraveling of which has never been accomplished. This mass of fibres, without doubt, contains other nerve-tracts of which we know nothing. That portion of this net-work, which is medullary at birth, is correctly depicted in Fig. 98.

The investigation of the relations of the posterior roots presents peculiar difficulties. We never see a fibre connect unmistakably with a cell-process: there is always a net-work between the two. We must bear in mind, too, that the greater part of these roots is made up of central fibres; that is, of fibres which have already passed their first terminal station (the spinal ganglion). We have made out the course of some of these central fibres by the study of secondary degeneration. We have seen that they pass directly into the column of Burdach along with the root-fibres, and that they show a tendency to pass more and more to the median line, so that in levels above their point of entrance they lie nearer the middle line in the column of Goll. But we have also seen that, while they were working toward the median line, they were continually giving off fibres to the gray matter.

If I am to succeed in giving you a clear explanation of the complicated relations existing at the entrance of the posterior roots, I must particularly request you to study the following text with continuous reference to Fig. 102.

On a transverse section of the spinal cord we see that the posterior root divides into at least four parts. The most median bundle (1, in Fig. 102), which consists of coarse fibres, passes almost entirely and directly into the white posterior columns at the same level with their point of entrance. These are the before-mentioned central tracts; along with these, fibres of equal

size (2, Fig. 102) pass into the spinal cord, which do not run directly toward the median line, but pass in a curve through the white substance laterally toward the columns of Clarke, where they are lost sight of. A few fibres run directly through the posterior horn ventrad of the substantia gelatinosa, and then

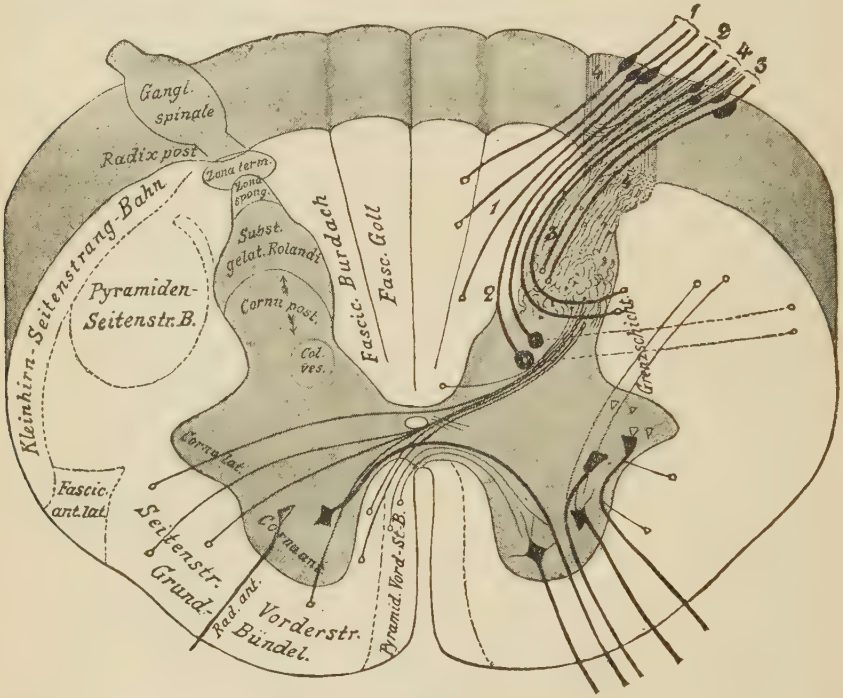

FIG. 102.

Diagram of a transverse section of the spinal cord, showing the central course of some of the most important tracts. Compare Fig. 98, which is not diagrammatic.

Grenzschicht, Limiting layer.
Kleinhirn-Seitenstrang-Bahn, Lateral cerebellar tract.
Pyramiden-Seitenstr. B., Lateral pyramidal tract.
Grund Bündel, Ground bundle.
Pyramid. Vord-St. B., Anterior pyramidal tract.
Seitenstr., Lateral column.
Vorderstr., Anterior column.

continue their course into the limiting layer of the lateral column. They are shown with peculiar distinctness in Fig. 98.

The two last-described portions of the posterior roots lie on the median side of the apex of the posterior horn. Laterally from these lie the bundles which are distributed to the latter; we can distinguish both coarse and fine fibres. Neither of them terminate at the level of their entrance into the cord. The larger

fibres (3, in Fig. 102) pass directly through the substantia gelatinosa Rolandi, which lies at the tip of the posterior horn, and at once turn upward and downward, and only pass farther into the gray substance at other levels. The fine fibres (4, in Fig. 102) become separated from the coarse immediately after the entrance of the root, and pass as a separate bundle upward and downward between the tip of the substantia gelatinosa and the periphery. The cross-section of this fasciculus was called zona terminalis by Lissauer, to whom we are mainly indebted for our knowledge on this point. Fibrils are continually given off from the zona terminalis to a net-work lying between it and the substantia gelatinosa. This net-work is called the zona spongiosa, and from it fine fasciculi arise, which pass into the substantia gelatinosa and are lost in the maze of fibres which make up the main mass of the posterior horn. From this intricate maze of fibres are developed new fasciculi, which pass across to the opposite side through the anterior and posterior commissures, and, emerging from the gray matter, are continued upward to the brain in the ground-bundles of the anterior and lateral columns.

We have, therefore, distinguished two paths in which the fibres of the posterior roots are continued upward,—a direct one, in the posterior columns, and an indirect path by which, after passing through the posterior horn, in some unknown manner, the fibres cross to the opposite side. We shall see later that the direct fibres, after passing through a nucleus in the medulla oblongata, also decussate.

It would not have been possible for me to recognize this arrangement of the fibres of the posterior root were it not for the fact that, in the lower vertebrates, the order of the fibres in the spinal cord is a very simple one: I might almost call it diagrammatic. Once it was shown, in the case of these animals, that the majority of the posterior roots pass through a net-work and afterward decussate before continuing on their course to the brain, it was easy to recognize the same conditions in human beings and other mammals.

Knowledge obtained by experiment and at the bedside confirms these late discoveries. If one-half of a spinal cord is divided the sensation of the skin is lost below the point of division, and that not on the same but on the opposite side. We had previously been at a loss to harmonize this fact with our knowledge that posterior root-fibres were continued directly (without decussation) in the posterior columns. The phenomenon, however, was at once explained when we discovered that a considerable portion of each root passed, in some way not clearly understood, to the opposite side shortly after entering the cord.

You will at once be struck by the remarkable analogy existing between the central fibres of the anterior and posterior roots. In the former we have (in relation to the root) a direct tract (the lateral pyramidal tract) and a crossed tract (the anterior pyramidal tract).

The principal distinction between the motor and sensory tracts consists in the different mechanisms which are interposed between the cells from which they originate and the point of their decussation.

While there is good cause to believe that this mechanism is very simple in the anterior horn, apparently residing in the cell itself, we see, in the case of the posterior roots, a whole net-work, itself filled with small cells, thrust in between the cells of the spinal ganglia and the decussation.

We shall have occasion again to refer to this important matter when we study the oblongata.

We must now consider that portion of the posterior root which does not arise from the cells of the spinal ganglion but is connected with the columns of Clarke. Pathological observations go to show that this portion has probably nothing to do with conveying sensory impressions from the skin. The central connecting fibres from the columns of Clarke do not pass upward in the general sensory tract. They send off fibres which pass out laterally from the gray matter, and reach the direct lateral cerebellar tracts in the periphery of the white substance, and in these tracts they pass to the cerebellum. These fibres are apparently of importance in the co-ordination of movements. We not only see disturbances in co-ordination of gait and

posture in cerebellar disease, but in tabes dorsalis, where the highest degrees of ataxy are sometimes present, the fibres of the posterior and of the vesicular columns are degenerated: the continuity of the tracts to the cerebellum is broken.

The anatomy of the spinal cord, so far as it could be ascertained microscopically, was described by Burdach, Sömmering, and F. Arnold. Bellingeri first discovered the connection existing between the anterior roots and the gray matter of the anterior horns, while Grainger rendered the same service with respect to the posterior roots and the posterior horns. The finer structure of the spinal cord, however, was first discovered by B. Stilling, and after him additional light was thrown on the matter by Kölliker, Goll, Deiters, Gerlach, Clarke, and others. We owe our knowledge of the course of fibres in the white substance principally to the works of Türk, Flechsig, Charcot, and Gowers.

The picture which I have given you to-day of the most important tracts of fibres in the spinal cord might be made much more complete, might be improved by many highly interesting details. We have touched, however, upon many points where our knowledge is uncertain, so that a faithful adherence to the object of these lectures will compel us to stop at this place, where the lack of known details and the conflicting opinions of authors prevent us from laying before the student clear and definite views.

In the preface to his great work on the structure of the spinal cord, Stilling says, "We must not, to borrow the language of the distinguished Burdach, forget that in investigating the spinal cord we are traveling through a wonderland of which we have no accurate knowledge. We can only turn our attention to the rivers and mountains in order to get a general idea of the whole, and must leave it to those who follow to trace up and map out the minor features of the landscape." Thirty years have passed away since this preface was sent forth into the world with a book richer in material than any ever before presented to anatomical science. We are still far from the goal, and it will be long before that perfect map can be drawn of which both Stilling and Burdach dreamed.

LECTURE X.

THE SPINAL CORD AND THE COMMENCEMENT OF THE MEDULLA OBLONGATA.

GENTLEMEN: In the spinal cord, fibres of widely different physiological significance lie crowded closely together. Those cells which we regard as central organs lie side by side with peripheral structures. You will, therefore, easily understand how extremely difficult it is to detect the consequences and symptoms which follow a disease or injury of any one of these components of the spinal cord.

Nevertheless, careful observation, both at the bedside and at the post-mortem table, has taught us much in this connection. A certain number of diseases affect only certain regions of the spinal cord, always confining themselves to particular columns or groups of cells, and leave all other parts of the cord intact, or at least invade them very slowly. The investigation of such diseases is naturally of great importance, as affecting the subject which we have now in hand. Then, too, injuries, sections, and compressions of the cord, such as may arise from spinal caries or tumors, often enable us to draw valuable conclusions.

Much less important results have been obtained by physiological experiments on animals than by pathology. The necessary operations are comparable to pathological processes of a rather gross character, and in animals we know very little of the nature and source of the severed fibres, for the reason that their cord has not been so thoroughly investigated as in the case of human beings.

It is, of course, beyond the pale of these lectures to give even a short summary of the valuable discoveries which we owe to pathological research. A number of excellent works will afford you an easy introduction into this part of our subject.

I will mention only a few points which are either particularly important or have been established beyond a doubt:—

Diseases of the pyramidal tract in the lateral, and apparently in the anterior columns as well, cause paresis or paralysis. In addition to this, the weakened or paralyzed muscles are in a condition of increased tension, have a tendency to contracture, and are abnormally responsive to mechanical irritants. Wherever you see these symptoms, either alone or mixed with others, you may with all safety assume that the pyramidal tract is involved in the disease.

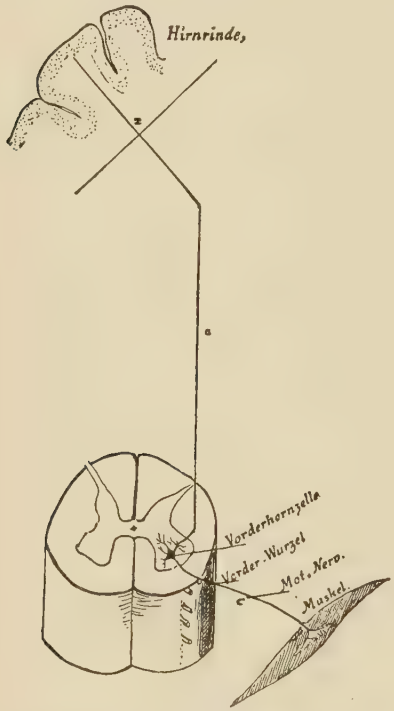

FIG. 103.

Diagram of innervation of a muscle.

Mot. Nerv., Motor nerve. *Muskel*, Muscle.
Vorderhornzelle, Ant.-root cell. *Vorder-Wurzel*, Ant. root.
Hirnrinde, Cortex of the brain.

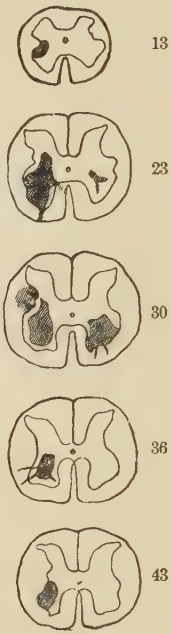

FIG. 104.

Localization of a lesion in the anterior horn of the gray matter in the lumbar enlargement, taken from a two-year-old child eleven months after the commencement of the disease. A large lesion in the right and a smaller one in the left anterior horn. Sections made 13, 23, 30, 36, and 43 mm. above the filium terminale. (From Erb, after Roth.

Diseases of the posterior columns give rise to symptoms varying according to the area of the columns involved. Injuries to the posterior roots at their entrance break up the continuity of the sensory tract which runs in the latter, and cause a loss, not only of every kind of sensation, but also of the reflexes which are set in motion by the sensory tract. The reflexes which have no direct connection with conscious sensation, as the tendon reflexes, also disappear. Degenerations of the posterior columns, which do not injure the entering posterior roots, or only slightly affect them, may not give rise to any serious disturbance of cutaneous sensation, but the muscle-sense invariably appears to suffer. The main

part of the fibres of the posterior roots which run in these columns stand in some sort of relation to this sense. The motor power is not diminished by disease of the posterior columns.

If the gray matter of the anterior horns is injured by a pathological process, there appears paralysis of the related muscles, just as in case of injury to the peripheral nerves. These paralyses are followed with unusual rapidity by atrophy of the affected muscles. This affection resembles the peripheral paralyses, also, in the fact that the paralyzed muscles react to the electric current as though their nerve-supply had been cut off. We think, from these facts, that we are justified in assuming that trophic centres for the muscles and nerves are situated in the anterior horn. The section experiment proves this. No matter where the anterior root is severed, be it far from or near to the spinal cord, its nerve always degenerates toward the periphery; while the posterior root, divided in like manner from the cord, remains in a great measure normal as long as its union with the spinal ganglion remains undisturbed.

If the fibres of the anterior roots are divided in the lateral columns between their cells in the anterior horn and the brain, there generally results only paralysis and no atrophy. From the accompanying diagram (Fig. 103), which shows the connection between the central and peripheral portions of a motor tract, you will easily understand the reason of this phenomenon.

A disease situated in the line *x a c*, or, rather, in the fibres represented by the line, leads to paralysis. If it interrupts the conductivity of the fibres above the ganglion-cells (at *a* or *x*), it has the character of a central paralysis without atrophy, and often results in an improvement, or even a cure, probably because other tracts act vicariously for it. If, however, the tract *x a c* is interrupted in the ganglion-cell, or at any part of *c*, then not only paralysis occurs, but the paralyzed fibres disappear, and the muscles supplied by them become atrophied. In this case there is little prospect of a cure. Occasionally, after long-protracted disease of the part *x a*, the part *c* is finally involved. This, however, is rare. A break in the tract at *a* leads to a descending degeneration from the point of injury to the corresponding anterior horn. The trophic centres for this part of the motor tract must, therefore, be sought for centrally from the point of interruption, probably in the cortex. As an example of paralysis and atrophy following disease of the anterior horn, I will cite infantile spinal paralysis. In this disease there occurs a sudden complete paralysis of distinct groups of muscles, soon followed by atrophy of the muscles themselves. An examination of the spinal cord reveals disease-foci affecting the gray matter of the anterior horns. The nerves, too, and even the anterior roots, gradually become atrophic. The spinal cord and the roots present somewhat the appearance shown in Fig. 105 *A* and *B*.

We are not yet in possession of a sufficient number of accurate and painstaking observations to enable us to say what symptoms will result from a disease of the gray matter of the posterior horns A comparison, however, of the cases of tabes dorsalis in which it was affected, and of those in which it was not, make it probable that a disease affecting this region would give rise to sensory, and especially to trophic, disturbances of the skin. In the vicinity of the basal portion of both anterior and posterior horns there must be situated tracts or centres, which stand in some relation to the trophic innervation of the skin and its blood-vessels. We must also look in this region for the mechanism which underlies the temperature-sense.

The above-mentioned functions are the very ones that suffer most in a dilation of the central canal—syringomyelia—or in tumors which are frequently situated in the midst of the gray matter.

After this short excursion into the domain of pathology let us return to the consideration of the structure of the spinal cord. At its upper end the white fibres which compose it are arranged in a most intricate manner. The extent and form of the gray matter is markedly changed, new collections of glia- and ganglion-cells appear, and the familiar appearance of a section through the spinal cord is greatly changed. The resemblance is particularly hard to trace just above the upper terminus of the spinal cord, where the inferior olivary body, a gray, plicated lamina, rich in ganglion-cells, usurps the place of the lateral columns on each side, and the central canal, trending continually backward, expands into the fossa rhomboidalis.

A

B

FIG. 105 *A* AND *B*.

Spinal cord, with acute anterior poliomyelitis, 43 years after the commencement of the disease. *A*. Section through the lumbar enlargement, both anterior horns and both antero-lateral columns strongly atrophied, more so on the left than on the right. No ganglion-cells. *B*. Section through the cervical enlargement. Left anterior horn and antero-lateral column markedly atrophied, and without ganglion-cells. Posterior horns and columns normal in both sections. (After Charcot and Joffroy.)

The series of sections which I will now demonstrate to you is intended to elucidate the transition of the spinal cord into the medulla oblongata.

Fig. 106 represents a section through the cervical medulla about opposite the point of emergence of the first spinal nerve. Its general appearance reminds us, on the whole, of the sections which we have before examined. We must notice three points in particular, because they differ from what we have hitherto seen. One is the peculiar shape of the posterior horn. It consists only of a thin "neck" united to its most dorsal portion, which at this level is markedly thickened by admixture with the substantia gelatinosa. This thickened portion is called the "head of the posterior horn." The substantia gelatinosa is

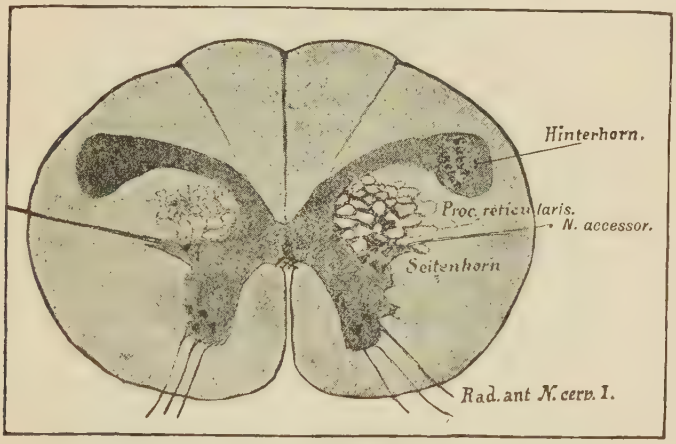

FIG. 106.
Section through the uppermost portion of the cervical cord.
Hinterhorn, Post. horn. *Seitenhorn*, Lateral horn.

permeated by innumerable fine fibrils, which may possibly have their origin in it. All these pass to the region lying external to the substantia gelatinosa and form a fasciculus, which extends to the periphery of the spinal cord and presents a somewhat crescentic appearance on cross-section. This fasciculus ascends far up into the pons, to the point where the trigeminus is given off, and emerges along with the fibres of the latter. It is called the ascending root of the fifth nerve. In all the sections which I show you from now on we shall see this crescent of nerve-fibres and the substantia gelatinosa lying median to it.

Next, you will notice that the lateral horns are strongly developed. The accessory nerve of Willis arises from cells which here lie at their base, but which, at higher levels, are situated at the lateral boundary of the anterior horns. The root-fibres of this nerve, which are given off continuously from the level of the sixth cervical nerve up to the commencement of the oblongata, do not pass straight out, as might be supposed,

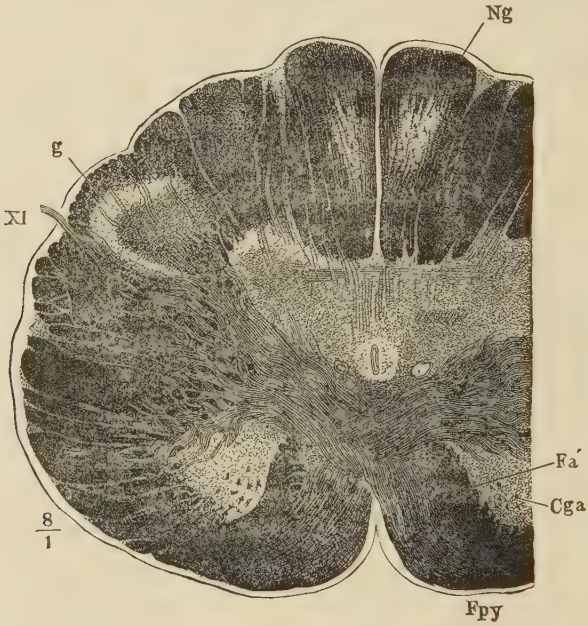

FIG. 107.

Cross-section of medulla oblongata through the pyramidal decussation. *Fpy*, pyramidal column; *Cga*, anterior horn; *Fa′*, remains of anterior column; *Ng*, nucleus of the funiculus gracilis; *g*, substantia gelatinosa; *XI*, accessory nerve. (After Henle.)

from the cut, but, on the contrary, extend upward toward the brain and then bend outward at an angle (Darkschewitsch). Only the horizontal limb of this angle is shown in the section (106). Please notice, too, that in the space between the posterior and anterior horns the gray matter extends out into the lateral column in the form of a thick net-work of fasciculi. This net-work is insinuated among the bundles of the lateral column, and is called the processus reticularis.

Just above the level of this section (Fig. 106) begins the peculiar arrangement of fibres, etc., which go to make up the medulla oblongata.

We found two pyramidal tracts in the spinal cord,—one situated in the anterior column, which conducted fibres toward the brain which were added to it from each nerve-root on the

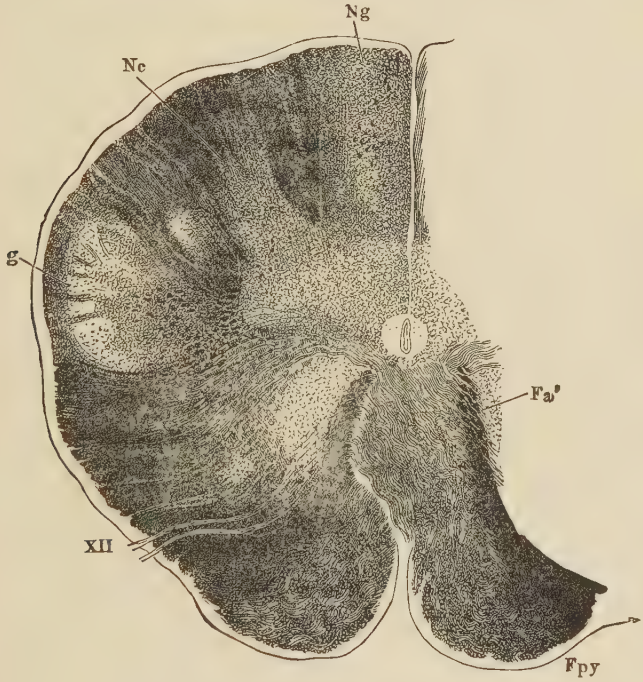

FIG. 108.

Section through medulla oblongata in the region of the most caudad of the roots of the hypoglossal nerve. Pyramidal decussation almost completed. *Nc*, nucleus of the funiculus cuneatus; *XII*, hypoglossal nerve. All other marks same as in Fig. 107. (After Henle.)

opposite side of the cord, and a second, situated in the lateral column, which received fibres from the anterior horn on the same side. At the upper end of the spinal cord (Fig. 107, *Fpy*) the last-named tract forces its way in thick bundles through the anterior horn of its own side and reaches the opposite anterior column. Here it meets with the anterior pyramidal tract, and from this point the crossed and the uncrossed pyramids are

united and pass upward as the pyramidal column. The posterior horns move more to the front, so as to occupy the space in the lateral columns which was formerly filled by the pyramidal tracts.

The pyramidal decussation is fully completed a few millimetres above this point. Both the anterior direct and lateral indirect pyramidal fibres are united into a thick bundle on the ventral side of the cord, which now bears the name of medulla oblongata. This is clearly shown in Fig. 108. You see that the ground-bundle (*Fa'*) of the anterior column has assumed a position dorsad of the pyramids. External to the anterior horn, which has been cut off from the rest of the gray matter by the decussation of the pyramids, lies a small gray mass. It is the commencement of the inferior olivary body. Higher up, the olivary body increases greatly in size and occupies a large share of the space once occupied by the lateral columns. These latter have become somewhat less abundantly supplied with fibres since the reticular process appeared on the scene. They still, however, send many fasciculi high up beyond the olivary body into the reticular processes. On account of the continual distribution of fibres to small gray nuclei situated in the latter, the supply of these fibres soon becomes exhausted and the lateral columns can be traced no farther.

The two accompanying figures, taken from Henle, show beautifully the general change in the arrangement of fibres and the passage of the lateral columnar pyramidal tract to the opposite anterior columns. The severed anterior horns can be traced still farther upward, but are lost at about the level of the pons.

You will see the pyramidal columns in the anterior part of all following sections lying between the olivary bodies. (See the figures of the next lecture.) At last they are covered in and split up by the transverse fibres of the pons. We have learned in previous lectures how they re-appear from under the pons, and pass upward in the pedunculi to the internal capsule. We have also seen that a break in the conductivity of the pyramid-

tracts situated in the brain was followed by a descending degeneration, which could be traced through the medulla oblongata into the opposite postero-lateral column and the anterior column of the same side.

You will not so very infrequently have opportunities to trace out the course of the pyramidal columns if, in autopsies on old cases of hemiplegia, you will make sections through the pedunculi, the pons, the medulla oblongata, and the spinal cord. The grayish pyramid of the affected side can generally be clearly distinguished from the normal white one of the sound side. In the spinal cord there will be also a gray, discolored spot in the opposite lateral column.

In that region of the spinal cord which is occupied by the pyramidal decussation there also appear marked changes in the posterior columns. Gray, ganglionic masses appear first in the inner and then in the outer division of the posterior columns. These are the nuclei funiculi gracilis et funiculi cuneati. These nuclei become blended with the gray matter and materially change its configuration. (In Fig. 107 the first-mentioned of these nuclei can be seen, and both are shown in Fig. 108.) Apparently, the fibres of the posterior columns gradually terminate in these nuclei. From the latter, however, masses of fibres are given off, which pass forward through the gray matter and decussate with those of the opposite side (above the pyramidal decussation). The fibres pass later to the fillet, and the upper pyramidal decussation has also been called the decussation of the fillet.

It is not easy to demonstrate beyond a doubt the existence of the decussation of the lemniscus in the adult organ. All doubt ceases, however, if we examine sections through the medulla oblongata of embryos in the seventh month. In this case the decussating medullary pyramidal fibres are not present to blur the clearness of the image, and the fibres of the posterior columns, which alone are medullary, stand out prominently and cannot be mistaken. At first, only the fibres from the nuclei of

Burdach's column can be made out, but later, in the ninth fœtal month, the decussation of the fibres from the nuclei of Goll's tract can also be seen.

Let us compare the accompanying cut with Figs. 107 and 108. Behind the central canal lies the gray matter, which, at this level, has become very much expanded laterally. In the

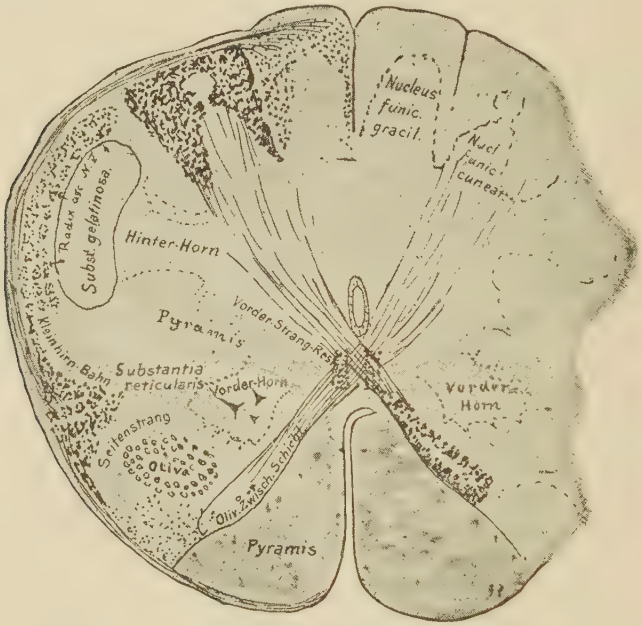

FIG. 109.

Section through the commencement of the medulla oblongata taken from a human embryo of the 20th week. Notice the tracts from the columns of Burdach to the decussation of the fillet, and the fibræ arciformes externæ posteriores from the column of Goll, which will be described later on. Observe the situation of the direct lateral cerebellar tract.

Kleinhirn Bahn, Cerebellar tract.
Vorderhorn, Anterior horn.
Oliv.-Zwisch.-Schicht, Inter-olivary layer.
Vorder-Strang-Rest, Remains of anterior column.

funiculi gracilis et cuneati their respective nuclei have appeared, and both are continuous with the gray matter. External to these lies the substantia gelatinosa of the posterior horns, surrounded by a thin stratum of medullary fibres (ascending root of fifth nerve). The space in front of them, which, in Fig. 108, is occupied by the dark pyramidal fibres, appears clear because these fibres have not yet become medullary. The remnant of the

antero-lateral column and the direct lateral cerebellar tract at the periphery of the lateral column have become medullated.

FIG. 110.

Section through the medulla oblongata of an embryo of the 20th week. The medullary fibres are stained with hæmatoxylin. The left inter-olivary layer and the ascending root of the trigeminus are not shown. In the restiform body only that portion which is derived from the spinal cord is medullary. Fibræ arciformes = fibræ arciformes externæ anteriores. The posterior external arciform fibres can be seen, outside and above, between the restiform body and the posterior column.

Hinterstrang, Posterior column.
Inn. Neben Olive, Internal accessory olivary process.
Hint. Neben Olive, Posterior accessory olivary process.
Oliven Zwischenschicht, Inter-olivary layer.
Seitenstr. Bahn, Lateral (cerebellar) tract.

We now see fibres arising from the nuclei of the posterior columns, which pass in a curve through the gray matter (fibræ arciformes internæ), decussate in front of the central canal, and

lie in a thick stratum dorsad of the pyramids, which have, at this level, completed their decussation. The region in which they lie is the one which was occupied by the antero-lateral columns in the spinal cord. The main mass of crossed sensory tracts which ascended in the latter is crowded backward and outward by these new-comers. Thus, the now united crossed sensory tract fills up all the space between the olivary bodies (olivæ inferiores). The latter are gray masses, which first appear in the medulla oblongata at this level. The higher we pass in the medulla oblongata, the fewer fibres are there found in the posterior columns. Gradually, all of them pass, by way of the arciform fibres, to the decussation of the lemniscus, and extend to the opposite side near the middle line, where they form the inter-olivary layer, or, as we will call it from now on, the layer of the fillet. The fibres of this layer pass to the fillet of the mid-brain.

It has been frequently claimed that the fibres of the posterior columns do not follow this course, but rather pass into the olivary bodies, and from there through the posterior peduncles of the cerebellum into that body. My investigations have shown, however, that they all, or nearly all, follow the course I have described. At the embryological period of which I was speaking, both the olivary bodies and their whole vicinity are destitute of medullary fibres. We can therefore prove, in the most convincing manner, that the fibres of the posterior columns have no connection whatever with them, but only pass through them. Fig. 110 represents a section through the same fœtal oblongata shown in Fig. 109. This section is made somewhat higher up than the latter, and shows clearly the point of which I speak. You see that the fibres pass through the olivary bodies (which at this level have the appearance of plicated medullary laminæ) to the decussation in the middle line (*raphé*, continuation of the decussation of the fillet).

Fig. 111 is a diagram of the course of the sensory fibres. Let us, with the aid of this diagram, trace out the course of the separate tracts, and ascertain what location in the medulla is

assigned to each. Please notice in this, as in the last figure, how the tracts which decussated in the spinal cord and those which ascended directly are united to form a single body. We have now met with two important decussations,—that of the pyramids and that of the lemniscus. The former is composed of motor fibres, while the latter contains the sensory tracts.

There are formed, therefore, two new large tracts of fibres, which lie in the ventral portion of the oblongata, viz., the pyramidal columns, and, dorsad of these, the layer of the fillet, or inter-olivary layer. We shall find them both occupying the same relative position as far up as the corpora quadrigemina.

The transverse area of the layer of the fillet is, in adults, much richer in fibres than is shown in the illustrations, which have been prepared from sections taken from the fœtus. In the latter none of the sensory fibres from the antero-lateral columns are medullary, and only those bundles which come from the nuclei of the posterior columns can be seen.

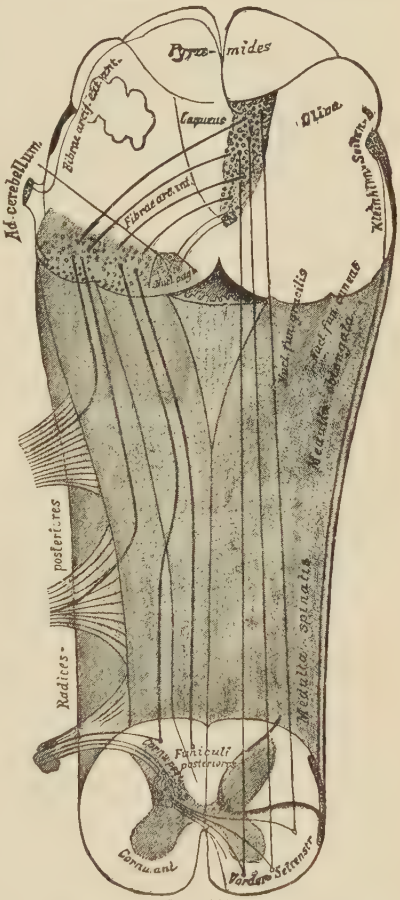

FIG. 111.

Diagram of the course of the sensory tract from the posterior roots to the medulla oblongata.

Kleinhirn-Seiten B., Lateral cerebellar tract.
Vorder-Seitenstr., Antero-lateral column.

The whole configuration of the section is changed by these two decussations. In addition to this the gray matter, as I will presently show you, varies its outline. New masses of gray matter appear in the oblongata. We have already met three

of these on each side,—the two nuclei of the posterior columns and the olivary body. The greatest difference is in the outer conformation of the section. The fibres of the posterior columns

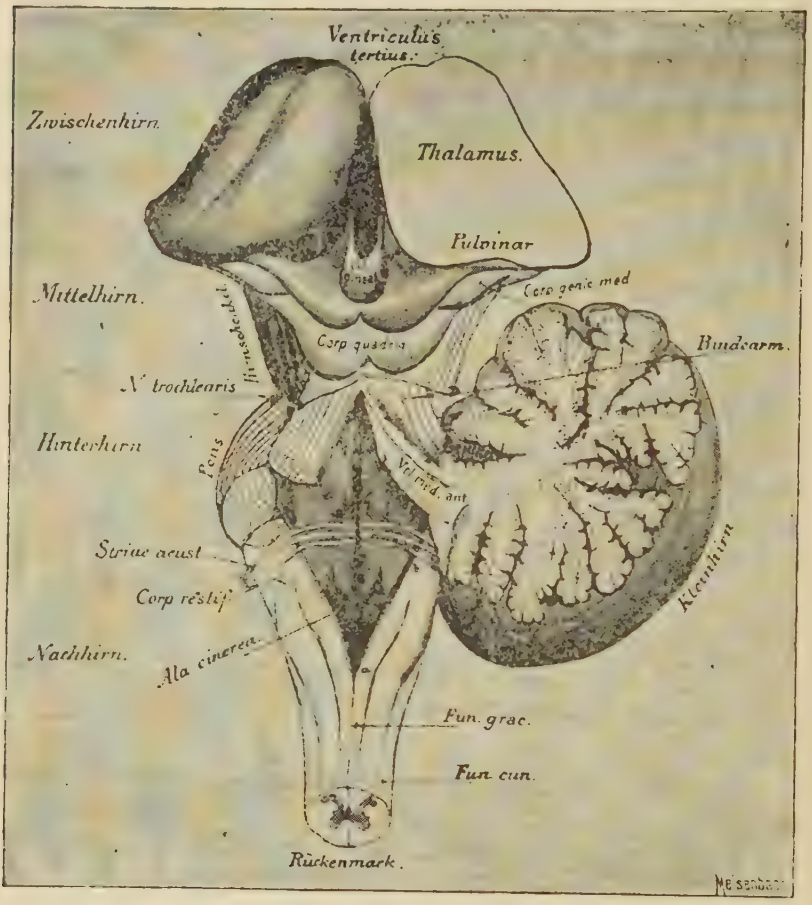

FIG. 112.

The hind- and after-brains opened by removing their roof. The velum medullare anticum and the cerebellum can still be seen. The velum medullare posticum has been removed along the dotted line *a b*.

Bindearm, Peduncle.
Hinterhirn, Hind-brain.
Hirnschenkel, Pedunc. cerebri.
Kleinhirn, Cerebellum.
Mittelhirn, Mid-brain.
Nachhirn, After-brain.
Ruckenmark, Sp. cord.
Zwischenhirn, Inter-brain.

are pushed gradually forward by the interposed nuclei, so that at last the latter are wholly uncovered and lie almost free on the dorsal surface of the medulla. The posterior columns

diverge somewhat in the region of the oblongata, so that the central gray matter lies exposed on the posterior surface of the spinal cord. Only a thin membrane of gray matter divides the central canal from the free surface. This canal expands along with the diverging posterior columns, and from now on is called the fourth ventricle. The thin membrane which covers it is called the velum medullare posticum, and is continuous anteriorly with the cerebellum. In the sagittal section, Fig. 56, you can see how the hind-brain roof is formed by the velum medullare posticum, the cerebellum, and the velum medullare anticum. Just at the commencement of the fourth ventricle is an opening through the velum medullare posticum, which leads from the outside into the ventricular cavity. It is the previously-described foramen of Magendi. Through this the fluid in the ventricles communicates with that which lies outside between the pia and the medulla, and, in the cavity of the arachnoid, bathes the whole central nervous system.

In Fig. 112 this whole roof is removed, so that we are looking directly into the fourth ventricle. Its floor is bounded behind by the diverging posterior columns and in front by the anterior cerebellar peduncles, which converge toward the corpora quadrigemina. This condition of things has given it the peculiar shape from which it has received its name,—fossa rhomboïdalis.

The posterior view of the oblongata (Fig. 112) shows that the posterior columns disappear above, and that the posterior cerebellar peduncles, the corpora restiformia (see below) take their place. The enlargement in the upper portion of the inner posterior column is called the clava, and is caused by the nucleus funiculi graciliis.

A front (ventral) view of the medulla oblongata (Fig. 113) shows first the thick pyramidal columns ascending from the spinal cord. External to them, imbedded in the prolongations of the lateral columns, are two good-sized enlargements,—the olivary bodies. Not far above them the thick masses of fibres which constitute the pons pass across in front of the pyramids.

In the prolongation of the line of exit of the anterior roots, between the olivary bodies and the pyramids, the hypoglossal nerve (*XII*) emerges from the medulla oblongata. The spinal accessory nerve of Willis (*XI*) arises by numerous radicles, which are given off along the side of the cervical cord, and high up in the oblongata, external to the olivary bodies. Above and in line with it emerge the vagus (*X*) and the glosso-pharyngeal (*IX*). Laterally, close behind the fibres of the

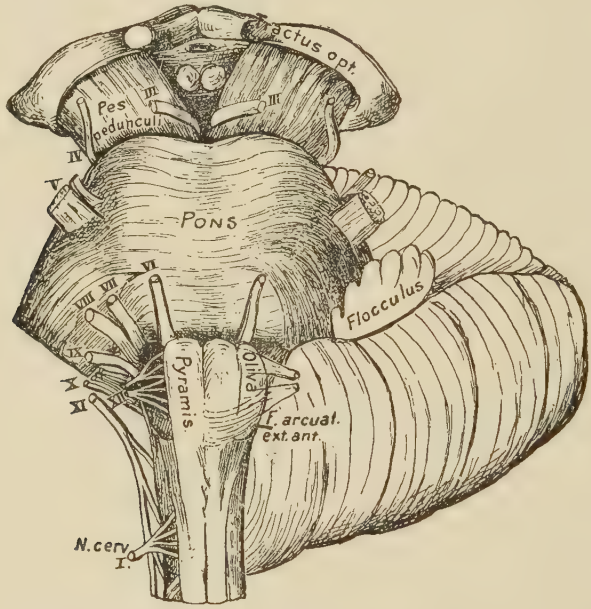

FIG. 113.
Medulla oblongata, pons, cerebellum, and pedunculus cerebri seen from in front. To show the origin of the cranial nerves.

pons, are given off the acoustic (*VIII*) and the facial nerves (*VII*). The sixth cranial nerve, the abducens, lies internal to the point of origin of the two last mentioned. The trigeminus (*V*) arises from the depths of the pons. The origins of the trochlear (*IV*) and the oculo-motor (*III*) have already been given. The first emerges from the velum medullare posticum behind the corpora quadrigemina, and the second from the ventral surface of the pedunculi cerebri.

We left off studying the section of the oblongata at the point where the central canal expands into the rhomboidal fossa. The first nuclei of the cranial nerves had begun to appear below this point. The fibres of the acoustic arise from cells in the lateral portion of the anterior horn. From a point somewhat ventrad of the latter, perhaps representing the position of the former anterior horn, arise the fasciculi of the hypoglossal nerve.

This is diagrammatically shown in the accompanying figure.

FIG. 114.
Section through the medulla oblongata at the level of the most posterior roots of the hypoglossal nerve. (Diagrammatic.)

Aus H. Str. Kernen, From the nuclei of the posterior columns. *Aus Rückenmark*, From the spinal cord. *Cereb. Bahn*, Lateral cerebellar tract. *Hinterhorn*, Posterior horn. *Hinterstränge*, Posterior columns. *Schleife*, Fillet. *Vorder-Seitenhorn*, Antero-lateral horn.

If, looking at this diagram, you will remember that the central canal broadens out along with the divergence of the posterior columns and becomes the fourth ventricle, you will easily understand that all nerve-nuclei developed in the floor of the ventricle above this point must lie on the floor of the rhomboidal fossa. The following cut (Fig. 115) shows this clearly. External to the nerve-nuclei lie the posterior columns (now nearly devoid of fibres), with their respective nuclei. The posterior horn, recognizable by the substantia gelatinosa of its head, is entirely

severed from the compact portion of the gray matter. The basal portion of the lateral horns, from which arise the fibres of the motor accessory, are also separated from it a short distance above the level of this section. The latter continues ventrad of the former, as an independent column of gray matter, rich in ganglion-cells, high upward into the pons; and when the fibres to the accessory are no longer given off it sends fibres to the

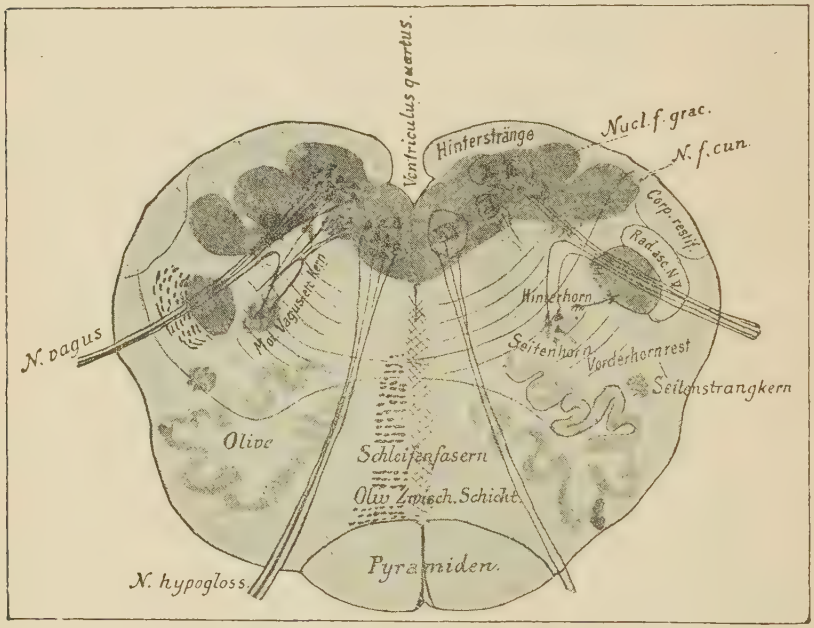

FIG. 115.
Section through the medulla oblongata at the level of exit of the vagus nerve. (Diagrammatic.)

Hinterhorn, Posterior horn.
Mot. Vagus etc. Kern, Motor vagus, etc., nucleus.
Schleifenfasern, Fibres of fillet.
Hinterstränge, Posterior columns.
Oliv. Zwisch. Schicht., Inter-olivary layer.
Seitenstrangkern, Nucleus of lateral column.
Vorderhornrest, Remnant of anterior horn.

vagus (and hypoglossal?), which at first pass dorsad and then bend back to the respective nerves (motor vagus, etc., nucleus). Still higher, we meet it as the nucleus of the facial nerve. You will notice that, with the exception of the hypoglossal and the nerves to the ocular muscles, all the motor fibres of the cranial nerves originate in this upward prolongation of the basis of the lateral horns of the spinal cord.

Please notice in Fig. 115 the position of the remnant of the anterior horn and the great increase in volume of the olivary bodies. When the lateral horn is divided from the rest of the gray matter there appears, at the point where, lower down, the posterior horn was attached (a region, therefore, which, in the spinal cord, was occupied by the nuclei of sensory nerves), a large new nucleus with spindle-shaped cells much like those of the posterior horns. This is the sensory nucleus of the vagus. It lies on the floor of the rhomboidal fossa, internal to the ala cinerea (Fig. 112), and extends forward to about the middle one of the transverse white lines which you see crossing the fossa. From this anterior end arises the glosso-pharyngeal nerve. The nucleus of the glosso-pharyngeal is not sharply divided from that of the vagus. We now see that there are two nuclei for the vagus,—a ventral one, which, from its situation (prolongation of a portion of the anterior horn) and from its cells (multipolar with axis-cylinders), we judge to be motor, and a dorsal one, which, from its situation in the prolongation of the gray matter at the base of the posterior horn and from its structure, we take to be sensory. The first mentioned of these is also called the nucleus ambiguus. The fibres arising from it all pass dorsad, and unite and turn at angle to join the straight sensory root, which is much larger. (See Fig. 115.) Besides these two nuclei the vagus receives fibres from at least two other regions. There is a small fasciculus which can be traced from the cervical medulla up to the point in the oblongata, where the last roots of the glosso-pharyngeal arise. On its median side is a column of gelatinous substance containing a few cells. The fibres from these all pass to the fasciculus just mentioned. At the level of the vagus-roots it begins to send off fibres to them, and this it does to all the roots of the vagus and the glosso-pharyngeal. This fasciculus is called the common ascending vago-pharyngeal root.*

It can be seen in Figs. 110 and 118, dorsad of the vagus-

* Gierke's respiratory bundle.

roots. In addition to this the vagus and glosso-pharyngeal apparently receive a descending root. It arises in the cerebellum, where we met it under the name of direct sensory cerebellar tract. These particular fibres, passing from it to the vagus, are hard to demonstrate in the human being. Apparently

FIG. 116.
Frontal section through the nucleus of the hypoglossal nerve. (After Koch.)

the sensory fibres arise from the ganglion juglare and extend from it toward the cerebrum (His) just like the sensory spinal nerves. The before-mentioned sensory nucleus, therefore, is their second terminal point. Many curving fibres enter its ventral side. By embryological methods we have succeeded in

showing that these fibres come from the opposite layer of the fillet. Thus the diagram of a sensory spinal nerve will also represent the course of the sensory vagus (and the glosso-pharyngeal as well)—nerve, first nucleus in spinal ganglion; root, second nucleus (sensory vagus-nucleus), crossed ascending central tract.

The nucleus of the hypoglossal consists of several collections of ganglion-cells, which are united by a fine net-work. From the large multipolar cells are given off fine processes, which converge to form a number of nerve-rootlets.

From the nucleus, just as from the anterior horn, are developed afferent fibres, which pass over across the median line. They do not continue their course far on the opposite side, but, after decussating, run toward the brain in the *raphé* and become united with other fibres (from the facial nucleus) in the pons. The whole fasciculus then passes into the pyramid of the crusta. Although this course differs somewhat from that of the central motor tracts in the spinal cord, still it is essentially the same—root, nucleus, crossed tract to the pyramids.

The net-work connecting the different divisions of the hypoglossal nucleus is of peculiar interest; we meet with nothing like it in any of the other nerve-nuclei. We should also notice that there is no other nerve whose fibres must act so harmoniously and so nearly at the same instant, as the fibres of the hypoglossal in the act of swallowing. Inasmuch as I have been compelled to place before you to-day figures which are largely diagrammatic, it will be well for you, at the close of this lecture, to study carefully the accompanying representation of the hypoglossal nucleus. It was drawn by Koch, in all its wealth of cells and fibres. He it was who first described the net-work. Ventrad of this nucleus lies another collection of cells (Roller's hypoglossal nucleus), from which, however, I do not think that hypoglossal fibres arise; at least, not in man.

The pyramidal decussation was discovered as early as 1710, by Francois Petit. The olivary bodies were first described by Vieussens. The macroscopic

changes in configuration from the spinal cord to the medulla oblongata, particularly those relating to the surface, were first described by Santorini, Reil, Burdach, and Rolando. The nuclei arciformes and the anterior arciform fibres which cover them were first accurately described by Arnold, who named them "the anterior pons." The striæ acusticæ were discovered by Picolhomini. Even in the pre-microscopic period there was an active dispute as to their relation to the acoustic nerve. Real light was first thrown on the structure of the medulla oblongata by Stilling, Kölliker, Meynert, Schroeder von der Kolk, and Deiters. In later years investigations directed more particularly to the nerve-nuclei have been instituted by Gudden, Roller, Freud, Laura, Duval, Koch, Darkschewitsch, and others.

LECTURE XI.

THE MEDULLA OBLONGATA AND THE TEGMENTUM OF THE PONS.

GENTLEMEN: In the last lecture we learned how the conformation of the oblongata was brought about by the peculiar alteration in the relative position of vast tracts of fibres, by the appearances of new nuclei, and by the disappearance of the posterior columns. We have, however, failed to trace a number of tracts upward from the spinal cord, and to these we will now turn our attention. The posterior columns have found their indirect prolongation in the layer of the fillet, and to this layer also have passed those motor fibres which ascended in the antero-lateral columns. The pyramidal tracts of the anterior and lateral columns, now united, lie on the ventral surface as the thick pyramids of the oblongata. The direct lateral cerebellar tract maintains its position on the outer periphery far up into the level of the olivary bodies. At that point its fibres, still gently ascending, begin to pass dorsad to the cerebellum. Here they form the nucleus of a large bundle which appears at this level,—the posterior cerebellar peduncle, or corpus restiforme.

The restiform body arises externally to the upper extremity of the posterior columns, and at this point is made up principally of the direct lateral cerebellar tract. To this are added the posterior external arciform fibres, which, as you see from Figs. 117 and 110 (above and to the left), pass to them from the posterior columns along the outer and posterior periphery of the medulla oblongata. Fibres are also added to them from in front. These are the anterior external arciform fibres, which originate apparently in the layer of the fillet between the olivary bodies, and are really, therefore, continuations of the crossed posterior columns. These fibres approach the surface near the middle line in front, extend around past the pyramids, and run outward and backward to the restiform bodies. They

have also been called the pyramidal arciform fibres (Fig. 113, front view). They inclose a small nucleus,—the nucleus arciformis (Fig. 118). Thus there pass to the restiform body from the spinal cord, 1, the direct cerebellar tract; 2, fibres of the posterior column on the same side; 3, fibres probably from the opposite posterior column.*

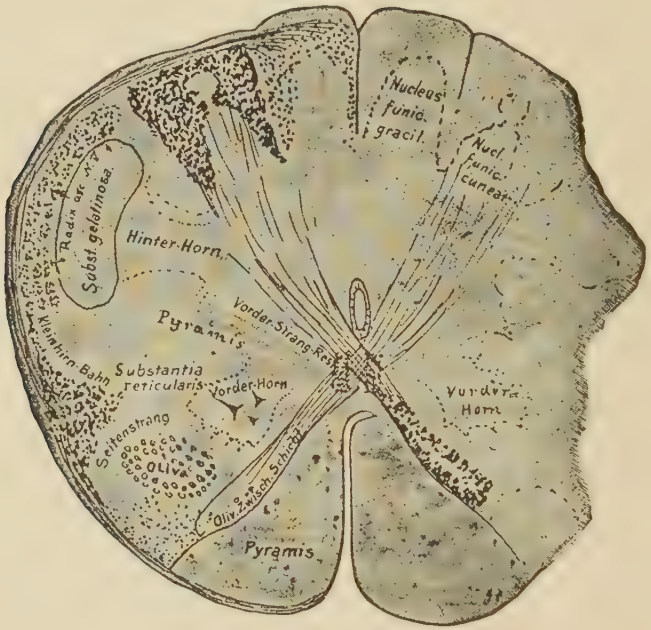

FIG. 117.

Section through the medulla oblongata of an embryo of the twenty-sixth week.

Hinter-Horn, Post. horn.
Kleinhirn Bahn, Cerebellar tract.
Oliv. Zwisch. Schicht, Inter-olivary layer.
Seitenstrang, Lateral column.
Vorder-Horn, Anterior horn.
Vorder-Strang-Rest, Remnant of anterior column.

In the embryonal period depicted in Fig. 110, only the fibres from the spinal cord are medullary. Thus we can clearly distinguish the extent and location of this portion of the posterior cerebellar peduncle. The different arciform fibres are also shown in Fig. 118.

The restiform bodies, however, contain, besides the fibres from the spinal cord, a second and much larger system, which

* The fibres mentioned under the heading 3 become medullary months before the pyramids and olivary bodies, probably at the same time as the posterior columns.

must be distinct from the former, because it becomes medullary at a much later period. These are the fibres from the opposite olivary bodies. Inasmuch as they come from the cerebellum and can be traced no farther downward than the olivary bodies, let us give them the name of cerebello-olivary fibres of the restiform body. It is only after the addition of these fibres that the posterior cerebellar peduncle becomes a larger structure than that shown in Fig. 110, when it consisted only of the fibres from the spinal cord.

The olivary body, a medullary structure whose wavy outline you have seen on many of the previous figures, consists of a mass of neuroglia, in which are imbedded innumerable small ganglion-cells. What the relation is between these cells and the nerve-fibres which run to the olivary bodies is, it is impossible to state.

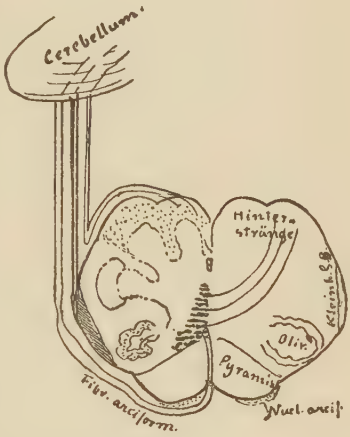

FIG. 118.

Origin of the spinal-cord portion of the restiform body. Most or all of the fibres end in the vermis.

Hinter-Strange, Post. columns.
Kleinh. S. B., Lateral cerebellar tract.

Large masses of fibres emerge from the restiform body, and surround the olivary process externally in front and behind. They pass through its medullary lamina, and in the interior are gathered into a thick bundle of nerve-fibres, which emerges from the hilus of the olivary body, crosses the *raphé*, and can be traced into the olivary body of the opposite side. If one-half of the cerebellum is destroyed, the opposite olivary body degenerates. Dorsad of the olivary body, in the vicinity of the substantia reticularis, a number of fasciculi pass upward in the tegmentum, in company with fibres which are given off from the net-work surrounding the ganglion (Bechterew's central tegmental tract, Stilling's remnant of the lateral column).

The cerebello-olivary tract of the restiform body has its

principal source in the outer side of the fleece. This, again, is connected with the anterior cerebellar peduncle by the nucleus dentatus cerebelli, which it surrounds. Thus, we can easily imagine that the olivary body, the opposite restiform body, the fleece, the anterior cerebellar peduncle and the red nucleus, again of the opposite side, form a separate system of fibres. Many observations, particularly those gained by experiments on animals, go to show that this system is of great importance in maintaining equilibrium.

Many investigators, adopting Meynert's views, are of the opinion that the cerebello-olivary tract is the continuation of the fibres of the posterior columns, which pass, so they claim, into the olivary body, and then emerge from it to reach the cerebellum by way of the restiform body. We have, however, previously seen that the posterior columns, while they do indeed reach the vicinity of the olivary bodies, through the arcuate fibres, and even in many instances pass directly through them, yet have nothing in common with the olivary fibres proper, but terminate in the layer of the fillet.

At those levels of the oblongata where the nucleus of the vagus is situated, most of the fibres from the spinal cord have already entered the restiform body. At this level, too, the latter has also received a part of the olivary tract. It lies in the form of a thick bundle outside the last remnants of the posterior columns.

We have now reached the level at which we get a typical section of the medulla oblongata. Let us, now that we have met with the majority of the structures there present, take a general view of the section as a whole. (See Fig. 120.) Many points that are new can easily be added.

In the ventral portion lie the pyramids. The large, triangular field of dense, transversely-divided fibres just back of them is the inter-olivary layer,—the crossed prolongation of the posterior-root fibres. The nuclei of the posterior columns lie externally near the dorsal surface, still covered by a few nerve-

fibres. Numerous internal arciform fibres take their origin here, and, passing through the motor area of the tegmentum (as the space between the posterior horn and the inter-olivary layer is called), enter the *raphé* and cross to the opposite side.

The fibres of the cerebello-olivary tract follow an exactly similar course for a certain distance. In the figure they are represented by dotted lines, but in reality the two kinds of internal arciform fibres cannot be distinguished in the adult.

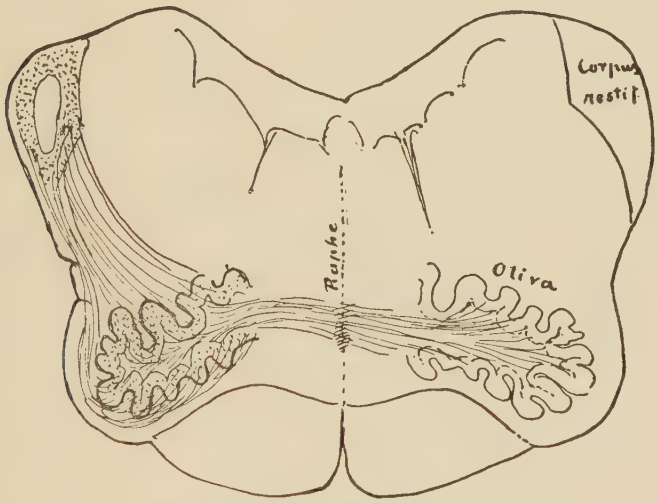

FIG. 119.

The cerebello-olivary portion of the restiform body. The fibres terminate mostly in the fleece of the corpus dentatum. That part of the restiform body which is left white indicates the situation of the spinal-cord portion.

In the median line, of course, all these fibres decussate with those coming from the opposite side. This line, with its numerous decussations, is called the *raphé*.

The inter-olivary layer, or layer of the fillet, contains at this level, besides the tracts which ascended in the antero-lateral column, the greater part of those originating in the nuclei of the posterior columns.

Notice, also, the fibres passing from the layer of the fillet to the nucleus of the vagus of the opposite side. They are the

analogue of the decussating fibres from the antero-lateral columns to the posterior horn,—the central vagus-tract.

Dorsad of the lemniscus we again meet with the posterior longitudinal fasciculus, which was described in the seventh lecture. Its fibres are met with deep in the anterior column, as low down as the first cervical nerve.

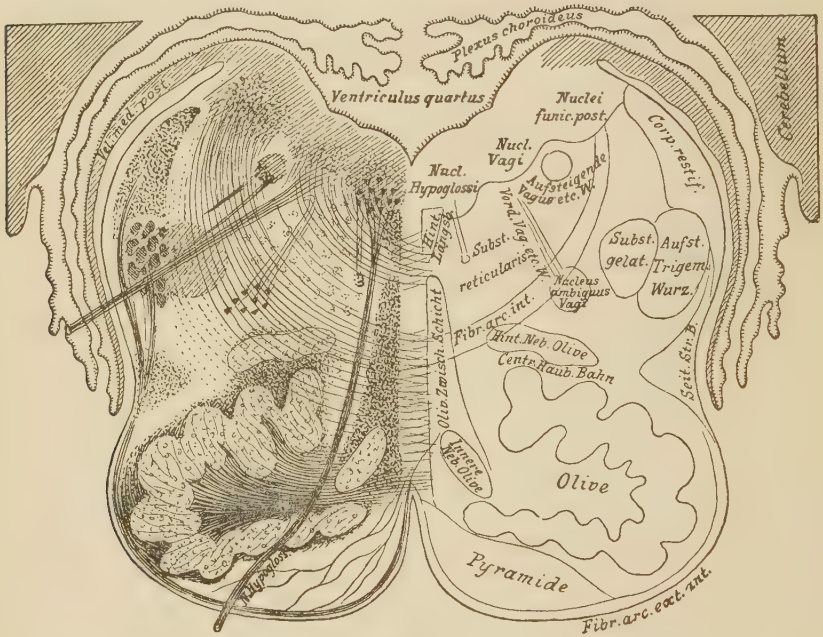

FIG. 120.
Section through the medulla oblongata.

Aufsteigende Vagus etc. W., Ascending vagus, etc., root.
Aufst. Trigem. Wurz., Ascending root of trigeminus.
Centr. Haub. Bahn, Central tegmental tract.
Hint. Längsb., Post. longitud. fasciculus.
Hint. Neb. Olive, Posterior accessory olivary process.
Innere Neb. Olive, Internal accessory olivary process.
Oliv. Zwisch. Schicht, Inter-olivary layer.
Seit. Str. B., Lateral cerebellar tract.
Vord. Vag. etc. W., Anterior vagus, etc., root.

The lower olivary bodies lie on both sides, external to the pyramids. They are traversed by the arciform fibres. Those arciform fibres which come from the cerebellum terminate here, while those originating in the nuclei of the posterior columns are merely in transit.

Internal to and dorsad of the olivary bodies lie the internal and posterior accessory olivary bodies. These are nuclei whose

structure resembles that of the olivary bodies, and which, like them, are traversed by the arciform fibres. As is shown in the figure, the internal accessory olivary body is traversed principally by the fibres passing from one olivary body to another, while the posterior body of that name gives passage mainly to the fibres of the posterior columns. The internal accessory olivary nucleus is also called the nucleus pyramidalis.

Dorsad of the olivary body, in the vicinity of the posterior accessory olivary nucleus, is a medullary tract, which we shall see from now on occupying a position in the midst of the tegmentum, and which can be traced to a certainty above the origin of the trigeminus. Taken together, these fibres—the central tegmental tract—probably connect the olivary body with the mid-brain.

The nerve-nuclei are situated along the dorsal periphery of the section.

Next to the median line is the nucleus of the hypoglossal nerve, whose fibres, after passing through the vicinity of the olivary body, run ventrad. (See Fig. 116.) It receives numerous fibres from the *raphé*. External to this comes the common sensory nucleus of the accessory, the vagus, and the glosso-pharyngeal nerve. As a rule, the fibres of the accessory do not issue from the nucleus at this level. The majority of them arise lower down from the accessory nucleus proper, which is situated in the upward prolongation of the lateral horns. A remnant of this nucleus, the anterior or motor nucleus of the vagus and glosso-pharyngeal, lies just in front of the posterior horn. Its fibres, before emerging, bend at an angle to join those from the sensory nucleus.

The thin bundle of transversely-divided fibres lying external to the last-named nucleus is the common ascending root of the vagus and glosso-pharyngeal. External to the common nucleus of these nerves lie the nuclei of the posterior columns, covered over by a few fibres. Ventrad of them you can see the substantia gelatinosa of the head of the posterior horn of the

spinal cord. Externally this is covered by a bundle of fibres, which is separated into numerous fasciculi, and which has accompanied it from the upper cervical cord. This bundle has become somewhat larger near its upper extremity, and can be traced high up into the pons. There it associates itself with the emerging fibres of the trigeminus, and perhaps, too, enters into some relation with their nucleus. This bundle, the ascending root of the trigeminus, has been described before (Fig. 109).

The region between the olivary bodies and the nuclei of the posterior columns, bounded externally by the direct lateral cerebellar tract and the ascending root of the fifth nerve and internally by the lemniscus, contains, besides the numerous internal arciform fibres, a great number of short fibres whose course can be traced but a short distance. Scattered throughout them are numerous multipolar ganglion-cells. We call this functionally unknown formation the formatio reticularis, and the space occupied by it the motor area of the tegmentum. Masses of cells are found in this situation in all vertebrates. They can be traced as scattered groups of cells up to the line of the *raphé*. As long as we possess no information concerning them, we shall do well to adopt the name given them by Bechterew,—nucleus reticularis tegmenti.

The fibres of the antero-lateral columns, which do not enter the layer of the fillet, can be traced into the formatio reticularis. It is possible, however, that they pass higher up.

On making further sections through the oblongata the picture changes but little for about two millimetres. We see the sensory nucleus of the vagus and glosso-pharyngeal projecting far upward, and continually sending off root-fibres toward the periphery from its own ventral surface. The ascending root also gives off an occasional rootlet to join the latter. The greatest change is in the restiform body, which increases greatly in size, for at this level it has begun to receive the fibres passing from the cerebellum to the olivary body.

The sections made just before reaching the pons show (Fig.

121) that the nuclei of the posterior columns have almost disappeared, the hypoglossal nucleus lying extended over a wide area, and the huge fibrous mass of the restiform body occupying a great amount of space.

Internal to the latter appears the section of a new bundle of fibres,—the direct sensory cerebellar tract. It is difficult to say just where it commenced; possibly as low down as the

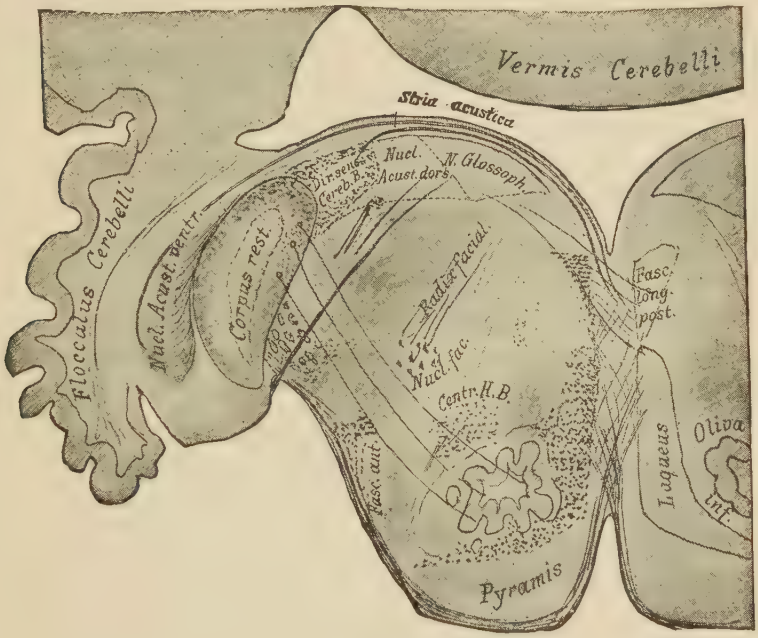

FIG. 121.
The structure of the medulla oblongata at the caudal border of the pons.
Centr. H. B., Central tegmental tract. *Dir. Sens. Cereb. B.*, Direct sensory cerebellar tract.

posterior columns. It may be that this area of transversely divided fibres also contains an ascending root to the acoustic nerve. Fibres run from the restiform body to the inferior olivary body, which latter at this level is very much diminished in size. Both the fillet and the central tegmental tract appear just as they did in the last section examined. Two new nuclei have appeared,—one, situated in the locality from which, in sections farther down, the fibres of the motor vagus arose (Fig.

132), sends all its fibrils dorsad and toward the middle line, near which they are gathered into a small bundle. This is the nucleus of the facial nerve. The second of the new nuclei lies external to the restiform body. In this section we only see fibres passing to it from the dorsal nucleus of the acoustic, which, at this level, is just beginning to appear. But in making

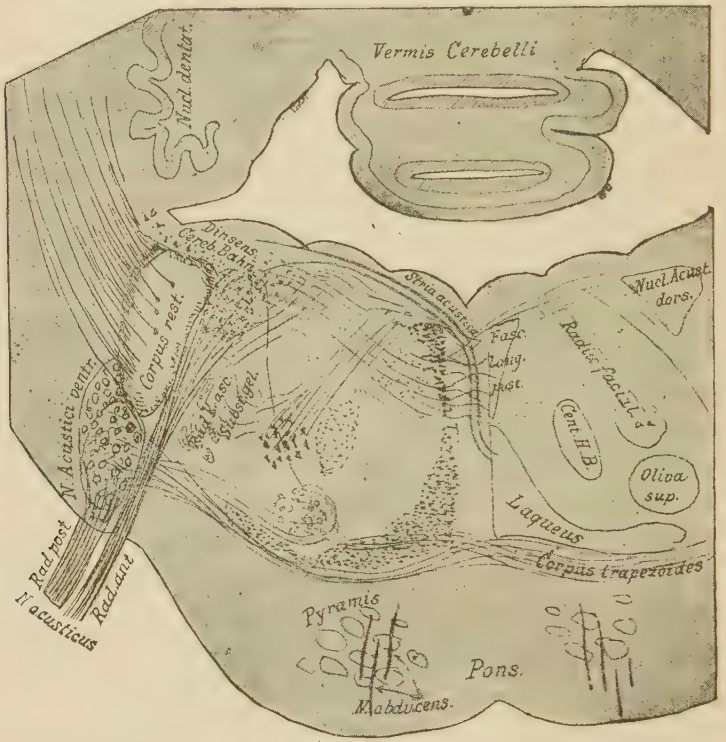

FIG. 122.
The most important structures shown by a section through the vicinity of the origin of the acoustic nerve.

Cent. H. B., Central tegmental tract.

the next sections you will see that we are dealing with a large structure, the ventral—formerly the anterior—nucleus of the acoustic nerve. You will observe even here how it is wedged in between the cerebellum and the restiform body. The enlargement ventrad of this nucleus on the outer surface of the oblongata is called the tuberculum acusticum.

In our upward progress we have now reached the point where the lowest fibres of the pons, running across the pyramids from the cerebellum, appear at the ventral periphery of the section.

Here we strike a region where several important structures are compressed into a relatively small space, the region of the origin of the acoustic, the facial, and the abducens nerves.

In the section represented in Fig. 122 you see that from the ventral nucleus of the acoustic there arises a root composed of fine fibres. This is the radix posterior acustici. You will also notice that another tract runs upward from this same nucleus and in part enters a rounded nucleus, the superior olivary body,

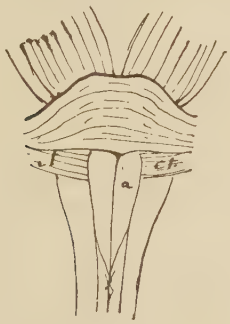

FIG. 123.
Medulla oblongata and pons of an ape. To show the corpus trapezoides.

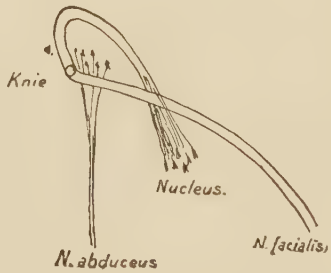

FIG. 124.
Diagram of the central course of the facial and abducens nerves.

Knie, Knee.

and in part extends over the median line. These latter fibres pass transversely through the layer of the fillet, which is placed in the dorsal portion of the pons. In the lower animals, where the pons is much shorter than in human beings, this tract can be seen as a quadrangular medullary area passing across the pyramids in the ventral portion of the oblongata. This area and the fibres it contains have received the name of corpus trapezoides.

The fibres in the corpus trapezoides connect the ventral acoustic nucleus with the superior olivary body of the same and of the opposite side. This is made clear in the following cut (Fig. 125).

Internal to the restiform body, which at this level begins to incline toward the cerebellum, lies the dorsal acoustic nucleus, which, just here, has reached its greatest expansion. The fibres of the direct sensory cerebellar tract pass through it, and a few of them pass into the acoustic nerve. From its ventral border emerges the anterior acoustic root, which is composed of coarse

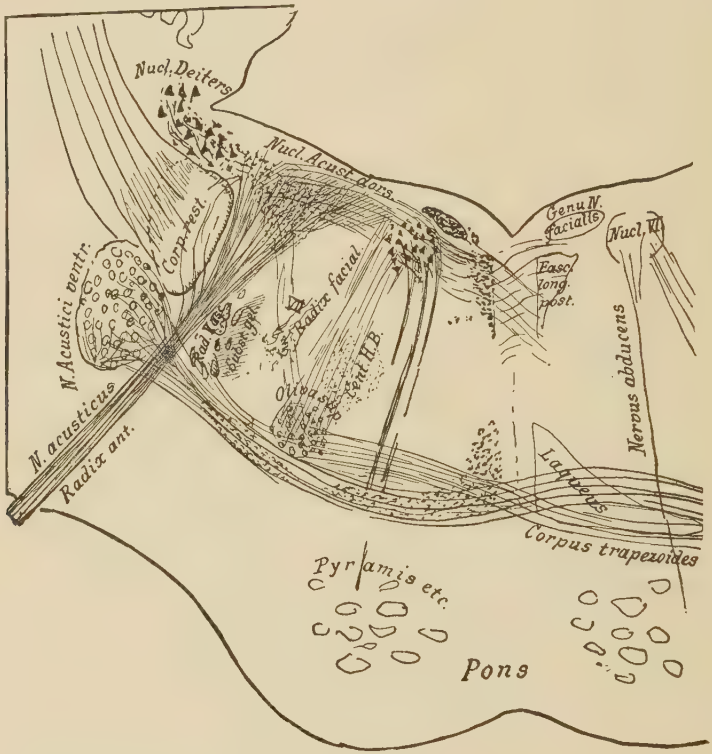

FIG. 125.
Section in the vicinity of the origin of the abducens nerve.
Cent. H. B., Central tegmental tract.

fibres. This nucleus is also connected with the upper olivary body. It is possible, however, that these latter fibres do not originate in the nucleus itself, but merely pass through it on their way from the cerebellum. In cats a connection between the superior olivary body and the cerebellum is easily shown.

In adult human beings we see numerous thick fibres arising

from the *raphé ;* these pass upward and decussate very near the floor of the rhomboidal fossa. They are here gathered into bundles, which run across this floor. These, the striæ acusticæ, which pursue a course analogous to that of the central sensory tract, pass from above downward into the dorsal nucleus; then, skirting along the border of the restiform body, are continued on to the ventral nucleus of the acoustic nerve (Figs. 121 and 122).

Monakow states that these striæ atrophied after he had divided the opposite lemniscus high up near the corpora quadrigemina. This, and their situation in the lower animals, lead to the conclusion that they are the central sensory tract of the acoustic.

At this level no new nucleus has appeared, only that of the facial nerve has increased in size. Fibres from the ascending root of the trigeminus are given off to the root of the last-named nerve. This is important, for we know that from just this portion of the trigeminus come the sensory fibres of the face.

Somewhat farther forward (Fig. 125) the fibres of the facial have been gathered together into a nerve-trunk. This, however, does not pass at once to the surface, but runs cephalad for a short distance, and then turns in the direction of the basis. In this way it makes two turns,—one in the horizontal and one in the descending part of its course. Just in the bend between these two turns is situated the nucleus of the abducens (Fig. 124).

The root-fibres of the abducens, gathered into several bundles, run a straight course through the tegmentum and pons, and emerge laterally on the ventral surface of the latter. The nucleus is connected internally with the posterior longitudinal fasciculus. It has been stated, but I think without sufficient foundation, that these fibres enter the opposite oculo-motor nucleus higher up. On the other hand, there is certainly a remarkable connection between the nucleus of the abducens and the superior olivary body. This tract, which you see running parallel to the root of the facial nerve in Fig. 125, must connect

the acoustic nerve with the nerves governing the movements of the eye. It may be of importance in connection with our judgment of space measurements.

External to the dorsal acoustic nucleus, imbedded in the direct sensory cerebellar tract, lies a nucleus whose significance is wholly unknown. It was formerly called the external acoustic nucleus. It atrophies if the cervical cord is divided on the same side (Monakow). No connection between it and the nerves of hearing has been clearly shown. It is, therefore, better for the present to call it Deiters' nucleus, in honor of that great investigator of the medulla oblongata.

The method of origin of the acoustic nerve, which was long in doubt, has been the subject of study by a number of investigators. The results obtained by some do not agree with the statements which have been made here, and which are based on personal research.

The author and Freund, whose investigations were conducted upon human embryos, have arrived at practically the same conclusions. Bechterew and Flechsig contend that the anterior root does not arise from the dorsal nucleus, but rather from some cells situated in the vicinity of Deiters' nucleus. The origin of the posterior roots from the ventral nucleus is conceded by all. Tearing out the acoustic nerve results in atrophy of this nucleus (Forel, Onufrowics, Baginski).

Let us, before we go farther, again look up the structures of the tegmentum which have not been specially mentioned in the text, and ascertain their situation and form at these levels. One, the nucleus reticularis tegmenti, which, together with the fibres of the substantia reticularis, is spread out over the area between the *raphé* and the root of the facial nerve, has, for the sake of clearness, been omitted from the illustrations. We could have seen it in all the sections through the levels which we have been studying.

The following figure (Fig. 126) represents the section lying just ahead of the preceding one, and is only given to show how

the facial nerve curves backward, and the entrance of the direct sensory cerebellar tract into the cerebellum. In sections made at this level the anterior cerebellar peduncles begin to appear.

After the facial, the acoustic, and the abducens have left the tegmentum, its conformation naturally becomes much simpler.

We are approaching the source of the trigeminus. First, in the prolongation of the nucleus of the facial, but somewhat more dorsad, appears the motor nucleus of the trigeminus. From it arises the motor root, the portio minor, which also takes a

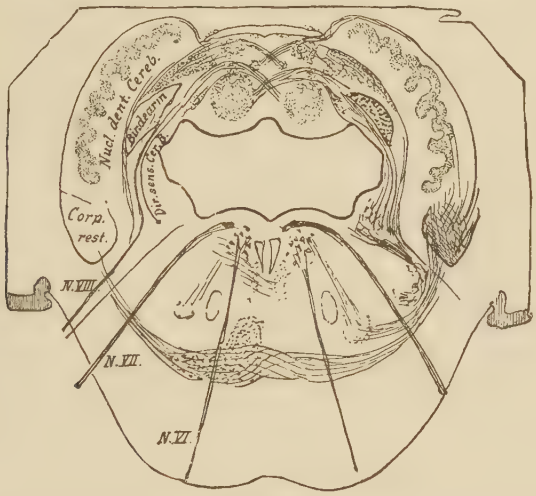

FIG. 126.
Section at the point where the internal division of the restiform body enters the cerebellum.
Bindearm, Sup. cerebellar peduncle. *Dir. Sens. Cer. B.*, Direct sensory cerebellar tract.

slightly-curved course. This root supplies the muscles of mastication. Probably this root also contains fibres from the opposite motor nucleus which have crossed in the *raphé*.

Other fibres leave the pons, together with the trigeminus, which do not arise in the motor nucleus, but high up in the quadrigeminal region, where a few cells at the side of the aqueduct give off this descending root of the fifth nerve. (See Fig. 72, above and to the left.)

These cells are continued caudad in the lateral walls, and we can see a large collection of them shining through the thin

ependyma of the ventricle, forming a dark group of cells on either side, and at the anterior extremity of the fourth ventricle. This area is called the locus cœruleus.

The main part of the trigeminus, the sensory portion, gets but very few fibres from the pons. They come rather from all levels above the cervical spinal cord up to its point of emergence from the brain. It has often been mentioned before, and is the thick, crescentic bundle of medullary fibres which surrounds the head of the posterior horn in almost all the illustrations shown in the last two lectures. Near the motor nucleus this main trunk dips forward into the pons, and emerges from it as the portio major. (See Fig. 113.)

Fibres also come from the dorsal region to enter the portio major. They are fasciculi from the direct sensory cerebellar tract. There are not many of them. In lower animals, however, particularly in fishes, they constitute the greater part of the nerve-root, and their point of origin in the cerebellum is so largely developed as really to form one of the lobes of that body.

Lastly, there is an enlargement of the substantia gelatinosa at its cerebral termination, which is regarded as a sensory nucleus of the trigeminus. It receives masses of fibres which run to it from the *raphé* across the floor of the rhomboidal fossa. Similar fibres also pass to the locus cœruleus. They represent the central tract which we have discovered as belonging to all the cranial nerves. Comparative embryology teaches us that this considerable bundle of fibres comes from the opposite fillet, and that after leaving it they run a short distance horizontally through the substantia reticularis.

The trigeminus roots cannot be shown in a single section. They come from dorsal and ventral areas to their junction on the floor of the rhomboidal fossa, where they turn and pass downward to their exit.

From the level of exit of the fifth nerve up to the level where the trochlear nerve emerges, the tegmentum has a much simpler structure than we have previously made out.

In the section which I last showed you the anterior peduncles had begun to separate themselves from the mass of the cerebellum. They now leave it altogether and are found externally on each side of the tegmentum. The layer of the fillet is a broad structure which here in the pons separates the

FIG. 127.
Section at the point where the ascending root of the trigeminus bends outward. Roots of trigeminus.

Centr. H. B., Central tegmental tract. *Centr. V. Bahn*, Central tract of fifth nerve.
Dir. Sens. Cerebellarbahn, Direct sensory cerebellar tract.

fibres of the tegmentum from those of the crusta, just as it did in sections made farther forward through the crura cerebri.

We can distinguish in the fillet an outer lateral portion and a more median one. The former is already beginning to trend upward to the quadrigeminal region, and the latter will follow its example a little farther forward. Just at the point

where the fillet begins to turn upward there are found some ganglion-cells imbedded in it (lateral nucleus of the lemniscus, Obersteiner). This group can be traced upward to the upper nucleus of the fillet, which is situated on the outer border of the substantia nigra. Those fibres of the fillet which lie nearest the *raphé* form a separate bundle. This arises from the pyramidal portion of the crusta. It was shown in the seventh lecture how this bundle became separated from the pes, passing around its

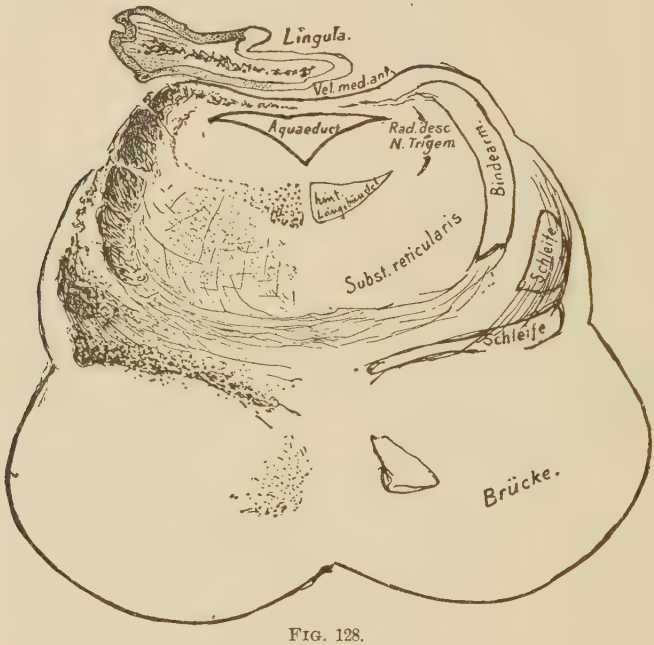

FIG. 128.
Section through the upper pontine region of a fœtus in the ninth month.
Bindearm, Anterior cerebellar peduncle. *Brücke*, Pons. *Schleife*, Fillet.

whole internal border and extending to the median side of the fillet. Spitzka's studies in comparative anatomy have made it very probable that this little bundle contains the central tracts of the motor cranial nerves. We may easily ascertain that fibres are continually given off from it which ascend in the *raphé*, and can see that, at the upper end of the *raphé*, fibres pass over beyond the middle line to the nerve-nuclei. This is shown most clearly with reference to the hypoglossal nerve.

We are now gradually approaching that region of the pons where the roof of the hind-brain is no longer formed by the cerebellum, but by the velum medullare anticum. The fourth ventricle here begins to narrow down to form the aqueduct of Sylvius.

The different structures which constitute the tegmentum at this level are very clearly shown in the accompanying non-diagrammatic section through the upper part of the pons of a 9 months' fœtus. At this period only one small fasciculus of the pes is medullary. In the tegmentum, however, the layer of the fillet, the anterior cerebellar peduncles, the posterior longitudinal fasciculus, and many of the fibres of the substantia reticularis are fully developed. The anterior peduncles are continuous above with the velum medullare anticum, upon which rests the anterior extremity of the lingula. Lower down, just above the fillet, can be seen the most posterior of the decussating fibres of the anterior cerebellar peduncles. The descending root of the trigeminus lies, a thin bundle of fibres, on each side of the aqueduct. You must imagine the cells of the locus cœruleus placed just under the floor of the aqueduct or the rhomboidal fossa. They did not show well in this specimen. The reticular substance here consists mostly of longitudinal fibres, which cannot be traced higher than the level of the anterior quadrigeminal bodies. Near the middle line on each side is the posterior longitudinal fasciculus.

From this level up to the quadrigeminal region the appearance of the tegmentum does not materially change. The fillet begins to work its way externally and dorsad of the tegmentum to reach the region under the corpora quadrigemina. You remember that these ascending fibres of the fillet could be seen even in sections through the mid-brain. The anterior peduncles approach each other and at last decussate higher up.

You have already observed the fibres of the crusta and the fasciculi of the pons penetrating them. It should be added that in the anterior levels of the pons there is a system of fibres

which become medullary shortly before birth, and which passes out of the pons, ascends in the *raphé*, and sends its fibres right and left into the reticular substance of the tegmentum. According to Bechterew they terminate in the most anterior part of the reticular nucleus.

Ganglion-cells possessing a structure similar to those of the pons can be found scattered along on both sides of the *raphé*, and can be traced also in that structure into the tegmentum.

LECTURE XII.

THE PONS—FINAL REVIEW.

GENTLEMEN: We reached, in our last lecture, that level of the tegmentum which we discussed in the eighth lecture. A few millimetres cephalad of the last section, the fibres of the pes emerge from under the pons to pass independently to the brain. In the medulla oblongata the pyramids are the only structures which pass into the pes; but from the ganglia of the pons huge bundles of fibres emerge, which run in the median and lateral portions of the crusta, and can be traced as far as the cortex of the frontal, parietal, and temporal lobes.

Now, again, we see the substantia nigra dividing the pes from the tegmentum.

The anterior cerebellar peduncles are lost in the red nuclei, and in place of the velum medullary anticum the roof is formed by the corpora quadrigemina.

The reproduction of a few sections which have been given before may recall to mind what was then said, and make clear the transition from the pons into the quadrigeminal region. (See Figs. 129, 130, and 131.)

The symptoms which arise in diseases of the pons and oblongata are, from the manner in which they are grouped, a pretty good proof of the correctness of our views of the anatomical relations of these parts.

Tracts are here crowded into a small space, which are of the utmost importance in movements of the muscles, in sensation, speaking, swallowing, etc. A disease focus need be but small to cause many different symptoms here.

The central motor and sensory tracts, which arise from the cortex as well as from the inter- and mid- brains, pass through the pons and oblongata, and only give off those fibres which go to the nuclei of the cranial nerves.

Inasmuch as a break in the conductivity of these long tracts will cause the same symptoms, whether it occur in the fore-, mid-, or hind- brains, we can only suspect disease of the pons or oblongata if symptoms are at the same time present which show that one or more of the cranial-nerve nuclei have been involved.

The muscular atrophy which follows affections of the nuclei themselves (see Fig. 68 and accompanying text) must be studied with scrupulous care if we are to succeed in discovering the location and extent of such a disease. Fig. 132, which gives you a general view of the nuclei in a longitudinal section through the oblongata, will make this task somewhat easier for you than it was possible for the transverse sections through the nuclei to do.

Disturbances of speech, respiration, or deglutition probably depend on disease of the oblongata,—paralysis of muscles of mastication (motor portion of trigeminus), facial paralysis, or affections of the abducens on disease of the pons. Inasmuch, however, as the central fibres to the nerve-nuclei of the oblongata pass through the pons, a disease situated there may also cause disturbances of deglutition.

The motor tracts to the extremities lie anteriorly near the ventral border in the pyramids. They only cross to the opposite side far down near the beginning of the spinal cord. The motor fibres of the cranial nerves, on the other hand, lie

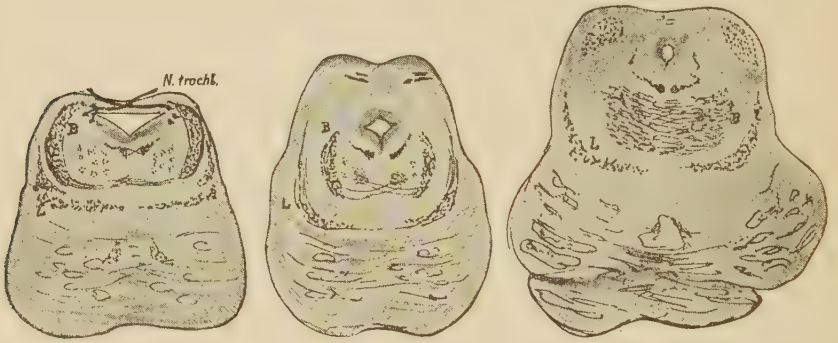

FIG. 129. FIG. 130. FIG. 131.

Three sections through the pons and quadrigeminal region of newborn children, to show the course of the cerebellar peduncles and the layer of the fillet. The latter is situated just above the fibres of the pons. The cerebellar peduncles, *B* (Fig. 129), are situated more internally in Fig. 130, and are beginning the decussation, which is at its height in Fig. 131. (Hæmatoxylin stain.)

near the middle line. They ascend in the *raphé* of the tegmentum, and only cross to the opposite side just before reaching the nucleus to which they are tending. A disease in the pons, therefore, will generally involve the opposite extremities, but will affect the facial abducens or trigeminus of its own side. The diagram (Fig. 133) is intended to impress upon your memory more forcibly than can be done by written descriptions this crossed paralysis, which is the most important symptom in many affections of the pons and medulla. It represents the motor innervation-tract for the face and extremities. You see from the cut that a lesion at *A*, in the right side of the cerebrum or right crus, would paralyze the left facial nerve and the left extremities. A disease at *B*, on the right, in the vicinity of the pons, would still paralyze the left extremities but the right facial. Should such a disease extend beyond the middle line it might paralyze both facial nerves and the extremities on one side. You see, also, in the diagram, that a disease in the pons (at *C*) might be so situated as to give rise to unilateral, not alternating, hemiplegia,—that is, it may cause the same symptoms as though it were situated in the cerebrum. Alternating paralysis can only (except in cases of multiple foci) be caused by dis-

ease of the pons, or tumors, etc., located in front of the pons, which impinge upon the peripheral portion of the cranial nerves and upon the pyramids. Inasmuch as the nuclei of the abducens and trigeminus are also located in the pons, these nerves may cause manifold modifications in the symptom-complex present in cases of alternating paralysis originating in disease of that part. How the acoustic nerve would be affected in such a case is still uncertain.

Through the pons, also, pass all the fibres to the nerve-nuclei of the oblongata, which supply the muscles of speech. Thus, in diseases of the pons and oblongata, we see disturbances of articulation, in spite of undiminished power of utterance. We call this either dysarthria or anarthria, according to the degree in which it is present.

Diseases of the pons may also lead to sensory disturbances. If it is located in the outer region, in the vicinity of the fillet, and is unilateral, we shall have hemianæsthesia of the opposite side.

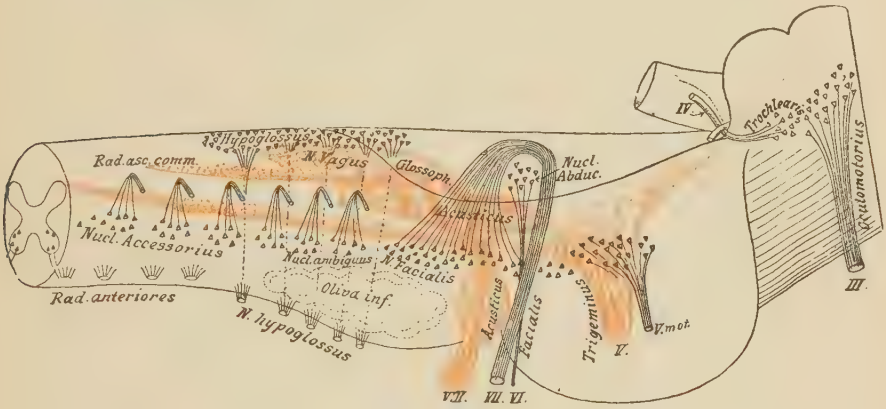

FIG. 132.

The situation of the cranial nerves. The medulla oblongata and the pons represented as transparent.

Still, the sense of taste (trigeminus) and that of hearing are almost always unimpaired, and the same may be said of the sense of sight. It is usually but little injured (paralysis of abducens, etc). The picture presented by intra-pontine hemianæsthesia, therefore, differs markedly from that produced by disease in the cerebrum. Bilateral hemianæsthesia may be caused by a disease situated in the middle line (inter-olivary layer). The occasional appearance of partial, direct, and alternating anæsthesias of the face is explained by the situation of the trigeminal nucleus.

Disturbances of mastication and deglutition may be observed also, because the motor nuclei of the trigeminus, the glosso-pharyngeal, and the hypoglossal may easily be affected by the same disease.

It is often difficult to decide whether a disease is seated in the medulla or the pons. From the situation of the motor nuclei of the vagus, accessory, and glosso-pharyngeal nerves such symptoms as hoarseness, loss of voice, and respiratory disturbances are usually only observed in diseases of the oblongata. Disturbances of articulation, dysarthria, and anarthria (nucleus of hypoglossal), and

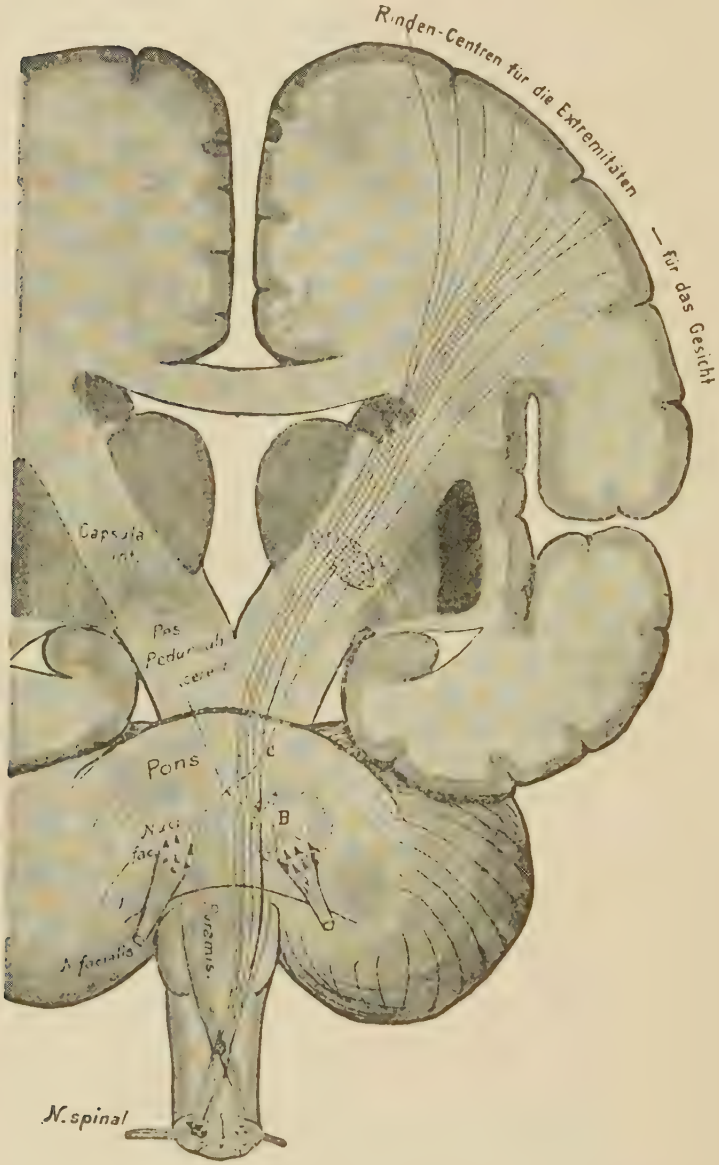

FIG. 133.

Diagram of the motor innervation tract for the facial nerve and the nerves to the extremities. Frontal section through the cerebrum, the peduncuh cerebri, the pons, the medulla oblongata, and the spinal cord.

Rinden-Centren für die Extremitäten—für das Gesicht, Cortical centres for the extremities—for the face.

disturbances of circulation are also more often caused by affections of the oblongata.

Almost all these symptoms may be caused in rare cases by disease in the cerebrum, inasmuch as injury to the central tracts of the cranial nerve-fibres is followed by paralysis, just as is injury to the nucleus or to the peripheral nerve. Paralysis of certain muscles supplied by nerves originating in the oblongata can only be ascribed to disease of the latter when simultaneous muscular atrophy appears, and an injury to the trunk of the nerve, outside the central organ, can be excluded.

Gentlemen: Our task is nearly done. A great number of important systems of fibres have been studied, both with regard to their relations to the central gray ganglia and to their course from the fore-brain down to the termination of the mid-brain, or from the spinal cord up to the same level. Still, it seems advisable again to examine a few of them briefly, either because they are of particular importance in connection with physiology or pathology, or because the comprehension of their whole course was rendered more difficult on account of their being traced, for didactic reasons, in an opposite direction after Lecture VII. Let this short recital serve as your guide in a sort of review, which you can easily undertake with the aid of the illustrations.

1. The pyramidal tract: The most important tract of motor innervation arises from the upper two-thirds of the central convolutions and the paracentral lobule, and runs to a point behind the knee of the internal capsule. From there it passes into the pes pedunculi, where it occupies the middle third. In the pons its fibres are but little divided by the transverse fibres of the latter.

After emerging from the pons its fibres lie in two thick bundles on the ventral surface of the oblongata. In this position they pass to the spinal cord. Here the great mass of the fibres cross to the opposite lateral columns; a smaller portion (anterior pyramidal tract) remains on the same side. Both these masses of fibres enter into relations with the cells of the anterior horns of the side opposite their cortical origin in the brain. From these cells the motor roots arise. Compare Figs. 44, 47, 56, 62,

72, 73, 96, 97, 98, 99, 100, 102, 103, 104, 108, 113, 114, 115, 120, 125, and 127.)

2. The central tract of the motor cranial nerves is only accurately known in the case of the facial and hypoglossal. The facial tract arises in the vicinity of the lower third of the central convolutions. Apparently this supplies the lower branches only; the cortical centre of the frontal branches is not known (gyrus angularis?). It then passes inward across the lenticular nucleus, and is finally found in the internal capsule, very close to the pyramidal tract. It cannot be (clinically) distinguished from the latter. Its fibres then abandon the general motor innervation tract apparently in company with the "bundle from the pes to the tegmentum," which has been frequently mentioned. They certainly are separated in the pons (see diagram, Fig. 68). It is not known how it reaches the nucleus. At all events it reaches the opposite facial nucleus, which lies in the caudal part of the pons. From this the nerve is given off. (See Figs. 47, 121, 122, 124, 125, 126, and 132.)

In the most ventral portion of the anterior central convolution is apparently situated the cortical centre of the hypoglossal nerve. At all events bundles pass from this region, ventrad of those going to the facial, whose destruction is followed by bilateral disturbances of the hypoglossal. On its way from the cortex to the internal capsule it passes over the upper edge of the lenticular nucleus, and must lie very near the speech-tract, just outside the commencement of the tail of the nucleus caudatus. In one case, which came under my observation, a diseased spot not larger than a 5-cent piece broke down both tracts at this point. In the internal capsule the hypoglossal tract probably lies between that of the facial and that of the extremities. Inside the pons its fibres must become separated from the pyramids. They apparently withdraw from the latter on the median side of the fillet, and pass upward and backward in the *raphé*. It is only on reaching the oblongata that they pass to the nucleus of the opposite (and the one on the same?)

side. From these nuclei arise the nerve. (Compare Figs. 47, 108, 110, 114, 115, 116, and 132.)

3. The motor speech-tract. We possess certain knowledge of only a few points along this tract,—the point of origin in the lower frontal convolution, the terminal point in the nuclei of the facial and hypoglossal, and, between the two, a point outside the tail of the nucleus caudatus. Apparently (Wernicke) the tract passes somewhat toward the median line from Broca's convolution—third frontal—and pursues an almost horizontal course under the island, dorsad of the internal capsule. Its fibres then pass into the internal capsule behind the motor tracts, and from there run to the crusta. In the pons they must gradually pass up into the tegmentum. Disturbances of speech have been observed in disease of all the above-mentioned points. (See Figs. 27 and 28.)

4. The coronal fibres to the pons arise from the cortex of the fore-brain, particularly from the frontal and parieto-occipital lobes. They pass through the internal capsule into the crusta, and from there into the pons (Fig. 56). From here they pass either directly or through interpolated ganglion-cells into the middle peduncles of the cerebellum, or brachia pontis.

5. The tegmental radiation arises in the parietal lobe, possibly in the same regions as the pyramidal fibres, and passes into the posterior third of the internal capsule. In this situation it is very closely approached by the optic radiation from the occipital lobe, and by the central tract of the acoustic. (As regards the latter tract, this has been demonstrated clinically, but not anatomically). A part of the tegmental tract passes into and through the lenticular nucleus, and a part passes directly into the fillet. Probably these two portions become united on the median side of the body of Luy's,—upper fillet. (Compare Figs. 47, 51, 52, 54, 56, and 59.)

6. The largest part of the fillet arises from the deep marrow of the corpora quadrigemina and from the nucleus of the posterior quadrigeminal body. In all likelihood it represents the

central sensory tract, or at least contains a good share of it. (Figs. 62, 65, 66, 70, and 72).

The fillet then passes back in the tegmentum of the crus, the pons, and the oblongata. On its way it gives off fibres to the opposite nuclei of the trigeminus, the acoustic, the glosso-pharyngeal, and the vagus. (Figs. 127, 126, 125, 122, and 121).

In the medulla oblongata a large share of the fibres branch off and pass dorsad over the middle line to the nuclei of the posterior columns,—internal arciform fibres. (Figs. 120, 117, 115, 114, 111, 110, and 109.)

The fibres of the posterior columns run caudad from the nuclei of these columns. Opposite each spinal-nerve root a few fibres are given off, which emerge with the root and enter the cells of the spinal ganglion. From these cells the sensory nerve arises.

Those fibres of the fillet which are left after the tracts to the nuclei of the posterior columns have been given off run backward in the anterior and lateral columns of the spinal cord. A number of these fibres pass off to the gray matter opposite each sensory spinal nerve, traverse it, and enter the opposite posterior horn. They are lost in the net-work of cells and fibres at that point; from this net-work, however, a great number of the sensory fibres arise. They all terminate directly in the spinal ganglion, and from this the sensory fibres arise. (Figs. 102, 100, and 88).

In this way connections are established between all the fibres of the layer of the fillet and the nuclei which lie on the opposite side. A portion decussate in the oblongata, the rest only do so after reaching the spinal cord. From these nuclei the fibres of the posterior roots are given off.

You have seen that the motor nerves are connected directly with the cells of the anterior horn, and have learned that a central tract, partly direct and partly crossed (the pyramids), arises from the anterior horns. The direct part (lateral pyramidal tract) passes across to the opposite side in the oblongata, and so

joins the other part which had already crossed in the spinal cord. The two, united, form the pyramids of the oblongata.

We also know that the sensory nerves have an analogous central course. The nerve first passes to its nucleus in the spinal ganglion. From the nucleus a direct tract is developed, which passes upward in the posterior columns. In the oblongata it passes over to the other side. Their course differs from that of the motor nerves in that they pass through a nucleus (nucleus of the posterior column) before decussating. In addition to this, there is given off from the spinal ganglion a tract which decussates directly after entering the spinal cord, but this tract must also pass through the unknown mechanism of the posterior horn.

There is an important and characteristic difference between the ways in which the two sets of nerves are connected with their prolongations into the brain.

The connection is always a crossed one, but, in the case of the sensory nerve, an additional apparatus is interposed in the cord, between the nucleus of origin, which lies outside the cord, and the central tract. With a motor nerve the case is different; its nucleus of origin already lies in the cord.

7. The central course of the trigeminus from the cortex to the capsule is unknown. Its fasciculi must, according to pathological experience, lie in the posterior third of the capsule. From here a tract must pass to the tegmental nuclei, the most anterior of which lies under the corpora quadrigemina, in the lateral wall of the aqueduct, the middle one in the midst of the pons, and the most posterior extends from the cervical cord up to the point of exit of the nerve. Near the point of exit is situated the motor nucleus of the nerve. Pathology teaches us that the ascending root contains the sensory fibres for the face. The central tract reaches all these from the fillet of the opposite side. These fibres are well known and were described in Lecture XI. From the trigeminal nuclei arise the roots whose sensory portions pass into ganglia (Gasserian and ciliary ganglia,

etc.), just like the posterior roots of the spinal nerves. The nerves arise from these ganglia. (Compare Figs. 47, 72, 86, 109, 110, 113, 114, 115, 125, 127, 128, and 132.)

8. As to the cerebral source of the acoustic nerve, we may assume that it is situated somewhere in the temporal lobe, that from here it is connected, in some way, with the posterior portion of the capsule, and that the acoustic tract passes on in that portion of the fillet which originated in the nucleus of the posterior quadrigeminal body. On reaching the level of the acoustic nucleus it passes to the opposite of these structures in the striæ acusticæ. There are two acoustic nuclei,—a dorsal, which resembles a sensory nucleus, both in situation and structure, and a ventral, which has a somewhat similar structure to that of the spinal ganglia. From its relations it may, perhaps, be compared to one of the latter. Through its ventral nucleus, the acoustic nerve is connected with the upper olivary body. From the latter, fasciculi run to the cerebellum and to the nuclei of the ocular muscles, and probably farther up to more anterior regions of the brain. (Compare Figs. 47, 65, 85, 113, 121, 122, 125, and 126.)

The trigeminus and the acoustic both receive fibres from the cerebellum.

9. Nothing is known about the central course of the vagus in the fore-brain. If the often-mentioned region in the posterior portion of the capsule is destroyed, no symptoms appear which can be attributed to the vagus. Disturbance of the sense of taste (glosso-pharyngeal) is present. Reference has been made to the course of the fibres from the fillet to the opposite nuclei of the vagus and glosso-pharyngeal. These nerves also apparently receive a tract from the cerebellum.

10. The central course of the optic nerve has been explained in all its relations. (Compare Figs. 56, 57, 61, 62, 66, and 70.)

I will again remind you that this nerve arises from the pulvinar thalami, the corpus geniculatum laterale, the tuber

cinereum, and, mainly, from the corpora quadrigemina. Fibres from the optic radiation, which commences in the occipital lobe, pass to all these sources. This radiation passes along the outer side of the posterier horn of the lateral ventricle, and, therefore, in its passage from the cortex to the primary optic centres, it runs under the lower parietal lobule. Hence, in diseases of the latter, or when it has been experimentally destroyed in animals, disturbances of vision arise which resemble those of cortical origin.

The fibres of the optic tract run to the chiasm. There the greater part of them cross to the opposite side. A small portion, which, however, are not gathered into a distinct bundle, remain on the same side. The conflict which was carried on for years over the chiasm has lately been definitely settled by Singer and Münzer, with the results given above. The optic tract must contain pupillary fibres coming from the oculo-motor nerve. It is not yet known by what course they reach the former.

INDEX.

Abducens nerve, 188, 207
Accessory nerve, 178, 188
Accessory olivary process, internal, 200
posterior, 200
Ala cinerea, 191
Amputation, spinal-cord, 7–10
Ansa peduncularis, 91
lentiformis, 88, 113
Anterior columns, 159
horn of ventricle, 15
horns, 152
mixed zone of lateral column, 165
Aqueduct of Sylvius, 96
Arbor vitæ, 136
Arms of the pons, 43, 132
Association fibres, 69
Axis-cylinder, 41

Baillarger's line, 65
Basal fore-brain bundle, 21, 79
Brain, embryology of, 20
peduncles of, 27, 36, 85
Brain-cortex, comparative anatomy, 22
physiology, 58
histology, 63, 137
Brain-sand, 96
Broca's convolution, 221
Burdach, 2, 12
Burdach's column, 162

Calcar avis, 53
Capsule, external, 38
internal, 18, 37, 76, 80
Central convolutions, 48
ventricular gray matter, 38, 91
Centrum semiovale, 31
Cerebellar peduncles, 132
anterior, 105, 111, 132, 142
middle, 132, 142
posterior, 132, 142
Cerebellum, 14, 20, 34, 132
Cervical enlargement of spinal cord, 150
Chiasm, 100
Choroid plexus (fore-brain), 14
(after-brain), 137
Cingulum, 71
Clarke, columns of, 157, 170
Claustrum, 38, 80
Clava, 187
Columna fornicis (see also Fornix), 52
vesicularis, 157, 170
Commissura, anterior (fore-brain), 38, 52, 71
(spinal cord), 167
media, 36, 52, 91
posterior, 36, 104
thalami dorsalis, 26
Conarium (see Pineal gland)
Conus terminalis, 150
Convolutions of cerebrum, 45
Cornu ammonis, 54, 55
Corona radiata, 24, 85
Corpora quadrigemina, 14, 34, 95, 105, 106, 114, 121
Corpus callosum, 32, 52, 71
ciliare (dentatum), 138
geniculatum laterale, 26, 36, 89, 108
geniculatum mediale, 36, 108
mamillare (candicans), 92, 93, 99
opticum, 20
restiforme, 132, 142, 195–198
striatum, 16, 21, 78
subthalamicum (Luys), 93, 104
trapezoides, 205
Cortical epilepsy, 70
Crura fornicis, 35
Crusta, 27, 85, 97, 124, 126
Culmen, 133
Cuneus, 53

Declivity, the, 133
Decussating commissure, anterior, 139, 143, 144
posterior, 144
zone, 142
Degeneration, secondary, 6, 147, 159, 162
Deiter's nucleus, 208
cells, 159
Dendritic tracts, 142
Direct sensory cerebellar tract, 143, 192, 203

Ehrenberg, 2
Embolus, 138
Embryology of central nervous system, 13
Embryonic lamina terminalis, 13
Epiphysis, 20, 25, 35, 96

Facial nerve, 188, 204, 207
Fascia dentata, 55
Fasciculus antero-lateralis, 164

Fasciculus arcuatis, 71, 72
longitudinalis, inferior, 71
posterior, 120, 200
retroflexus, 121
uncinatus, 41
Fibræ arciformes, 142, 195
internæ, 183
propriæ (of the cortex), 68
Fifth nerve, ascending root, 177
descending root, 122
Fillet, 26, 95, 104, 113, 221
Filum terminale, 150
Fimbria, 54
Fissura calcarina, 53
hippocampi, 54
occipito-temporalis, 57
parieto-occipitalis, 53
Sylvii, 15, 45
Flechsig, 7
Fleece, the, 142
Flocculus, 135
Folium cacuminis, 134
Foramen of Magendie, 138, 187
of Monro, 34
Fore-brain, secondary, 14
Formatio-reticularis, 202
Fornix, 16, 35, 51
Fountain-like decussation of the tegmentum, 114, 124
Frontal lobe, 24, 48
Funiculus gracilis, 162
cuneatus, 162
Furrows of cerebrum, 45

Ganglion-cells, 40
Ganglion habenulæ, 26, 36
Ganglionic ridge, 19
Gaskell, 29
Gasserian ganglion, 223
Gelatinous cortical layer, 158
Gennari, line of, 65
Gland, pineal, 20, 25, 35, 96
Globus pallidus, 38, 86
Glosso-pharyngeal nerve, 188, 191, 224
Goll's tract, 162, 182
Granular layer, 138
Ground-bundle of posterior column, 162
of anterior column, 165
Gudden, 7
Gudden's commissure, 108
Gyrencephalous mammals, 23
Gyri insulæ, 48
Gyrus angularis, 49
centralis ant. et post., 48
dentatus, 54
formicatus, 53-55
hippocampi, 53–55
marginalis, 49
occipito-temporalis, 57
uncinatus, 52

Hannover, 2
Hearing, nerve of, 108, 188, 204, 221
Hemispheres of cerebellum, 134, 135
History of investigation of the brain, 1–11
Horns of lateral ventricle, 15
Hypoglossal nerve, 188, 193, 201, 220
central tract of, 74, 220
Hypophisis, 35, 100

Inferior horn of ventricle, 15, 199
Inferior longitudinal fasciculus, 71
Infundibulum, 35, 38, 100
Inter-brain, 13, 14, 25, 74, 89
Inter-olivary layer, 184, 198
Intumescentia cervicalis, 150
lumbalis, 150
Island of Reil, 38, 46

Knee of corpus callosum, 52
of internal capsule, 80

Lamina medullaris thalami, 104
terminalis, 101
Laqueus, 26, 95, 104, 113, 221
Lateral cerebellar tract, 164, 195
columns, 159
Latticed layer, 90
Lemniscus (see Laqueus)
Lenticular nucleus, 18, 38, 78
divisions of, 86, 87
Limiting layer of gray matter, 165
Lingula, 133
Lisencephalous mammals, 23
Lobes of cerebellum, 133
Lobi optici, 26
Lobus centralis, 133
cuneiformis, 135
frontalis, 24, 48
gracilis, 135
lingualis, 53
occipitalis, 50
olfactorius, 100
parietalis, 49
posterior inferior, 135
quadrangularis, 134
semilunaris inferior, 135
superior, 134
temporalis, 48
Localization and symptomatology of disease in:—
the cortex, 57
the central ganglia, 102
the cerebellum, 145
the quadrigeminal region, 124
the spinal cord, 150, 173
the oblongata and pons, 215
the white substance, 81
Locus cœruleus, 210
Longitudinal fissures (spinal cord), 152
Lumbar enlargement " " 150
Luys, body of, 93, 104

Margin of hemisphere, 14
Marginal convolution, 55
Marrow, deep, 27, 114
Medulla oblongata, 29, 176
spinalis, 27, 150
Medullary sheath in spinal-cord, 158
structure of, 8
Methods of investigating the central nervous system, 4–14
Meynert's bundle, 121
Mid-brain, 13, 34, 95, 120
Motor area of tegmentum, 199
nuclei of cranial nerves, 190, 222, etc.
roots, 147, 201, 222
speech-tract, 74, 221

Nerve-fibres, 40
two forms of origin of, 41
Neuroglia, 39
Nodulus, 134
Nuclei acustici, 204
Nuclei of the thalamus, 89
of trigeminus, 209, 210
of trochlear nerve, 130
Nucleus ambiguus, 191
amygdalæ, 38
arciformis, 196
caudatus, 18, 34, 77
dentatus, 138
fastigii, 144
funiculi gracilis, 181, 182
cuneati, 181, 182
globosus, 138
lemnisci, 212
lentiformis, 18, 38, 78, 86
of abducens, 207
of accessory nerve, 178
of facial nerve, 204
of glosso-pharyngeal nerve, 191
of oculo-motor nerve, 115
of hypoglossal nerve, 193
pyramidalis, 201
reticularis tegmenti, 202
ruber, 93, 94

Oblongata, 29, 176
Occipital lobe, 50
sulci, 50
Oculo-motor nerve, 115, 188
Olfactory nerve, 25, 100
bulb, 25
Olivary body, inferior, 176, 184, 197
superior, 205
Operculum, 47
Optic nerve, 26, 100, 108, 224

Pallium, 21
Paracentral lobule, 53
Parietal lobe, 49
organ, 26
Pedicle of thalamus, 74
Pedunculi cerebelli, 132
cerebri, 27, 36, 85
conarii, 36, 96
corporis mamillaris, 92
Pes hippocampi major, 54
minor, 53
pedunculi, 27, 85, 97, 124, 126
Plexus choroideus (fore-brain), 14
(after-brain), 137
Pons, 14, 29, 74, 98, 127, 215
Posterior columns, 159
nuclei of, 181, 182
Posterior horns, 152
head of, 177
neck of, 177
roots of spinal cord, 147, 156, 167, 224
Præcuneus, 53
Processus protoplasmatici, 42
reticularis, 153
Pulvinar, 36, 89
Purkinje, cells of, 138
Putamen, 38, 79, 86
Pyramidal column, 180, 198
tract, 74, 98, 111, 219, 222, etc.
in anterior column, 160, 222
in lateral column, 160, 222
Pyramis cerebelli, 135

Raphé, 199
Rays, 21
Red nucleus, 93, 94
Regio subthalamica, 88, 93
Reil, 2
Remak, 2
Remnant of antero-lateral column, 165
Respiration bundle, 191
Rhomboidal fossa, 96, 175, 187

Saccus vasculosus, 25
Secondary degeneration, 6, 160, 161
Sensory nuclei of cranial nerves, 191, 200, 201, 223
roots, 18, 147, 156, 223
Septum pellucidum, 16, 34, 51
Speech-tract, 74, 221
Spider-cells, 159
Spinal cord, 28, 149
segmentation of, 151, 155
ganglia, 147
Splenium, 52
Stilling, 2–4
Stratum complexum et profundum pontis, 127
intermedium (Meynert's), 111
superficiale pontis, 127
zonale, 89
Stria medullaris, 36
longitudinalis Lancisi, 56
terminalis, 36
Striæ acusticæ, 207
Substantia gelatinosa centralis, 158

Substantia gelatinosa Rolandi, 158
innominata, 91
nigra, 95
perforata, anterior, 100
posterior, 98
reticularis, 130
Sulcus calloso-marginalis, 52
centralis, 48
insulæ, 47
interparietalis, 50
olfactorius, 56
orbitalis, 56
præcentralis, 48
Sylvius, fissure of, 15, 45

Tangential fibres of cortex, 65
Tapetum, 72
Tegmental bundle of corpus mamillare, 93
radiation, 75, 87, 91, 113, 221
tract, central, 201
Tegmentum, 27, 85, 111, 122, 129
motor area of, 199
Temporal convolutions, 48
lobe, 48
Thalamic ganglia, 25
Thalamus, 14, 34, 74, 89
Tonsilla (cerebelli), 135
Tractus intermedio-lateralis, 153
olfactorius, 25, 100
Tractus opticus, 26, 89, 100
Trigeminus nerve, 188, 209, 223
Trochlear nerve, 130, 188
Tuber cinereum, 35, 38, 100
olfactorium, 100
valvulæ, 135
Tuberculum acusticum, 204
anterius, 36

Uvula (cerebelli), 134

Vagus, 188, 191, 224
Velum medullare anticum, 134, 136
posticum, 21, 137, 187
Ventricle, 14, 15, 33
Ventriculus lateralis, 14, 15, 33
quartus, 96, 127, 140, 176, 187
septi pellucidi, 34
Vermis, 132, 133
Vicq d'Azyr's bundle, 93

White substance, 158
of cerebrum, 31
of hemispheres of cerebellum, 135
of vermis, 133
Worm, 132, 133

Zona spongiosa, 169
terminalis, 169
Zone of anterior horn (His), 29

F. W. S. Langmaid, M. D.,
Instruments,
Books,
Supplies,
for practitioner and student,
202 S. 36th St., Phila., Pa.